

Severe cobalt poisoning with loss of sight after ceramic-metal pairing in a hip—a case report

Wolfram Steens¹, Goetz von Foerster² and Alexander Katzer²

¹Franziskus-Hospital Münster, Orthopädie, Hohenzollernring 72, DE-481 45 Münster, ²ENDO-Klinik, Hamburg, Germany

Correspondence WS: wsteens@gmx.de

Submitted 05-10-06. Accepted 05-12-11

A healthy 53-year-old man who had been treated with a cemented total hip arthroplasty including a ceramic-on-ceramic pairing 6 years previously underwent revision surgery 3 years later because of chronic pain in the operated hip. The firmly incorporated stem and socket were left in place, the ceramic head was changed to a long metal head for a better offset, and a soft tissue revision was performed.

2 years after revision, the patient noted increasing impairment of his hearing and sight and eventually he could just recognize outlines and colors but could not read. Also, he needed a hearing aid and headphones. In addition, there was numbness in his feet, and his head and neck were affected by dermatitis.

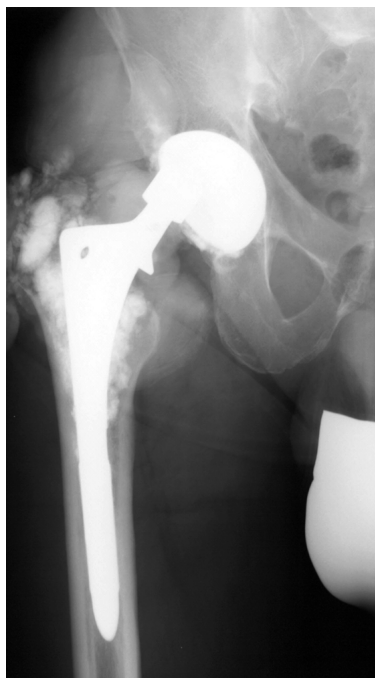

Figure 1. Deterioration of the metal head on radiographic control 3 years after revision surgery.

No attention had been paid by the medical staff involved to a hair analysis that had shown an increased amount of cobalt following revision surgery (Table). At the time of our first contact—and months after the reduction of hearing and sight had started—he again also had pain in the hip and radiographs showed deterioration of the metal head (Figure 1).

Using the dorsal approach for revision, the soft tissue, capsule and bone adjacent to the component were seen to be densely stained with black metal debris (Figure 2). The metal femoral head was worn down to a cylinder (Figure 3). The rim of the inlay was smashed and fragments of alumina ceramic were spread around (Figure 4). Histological examination of the soft tissue revealed a fibrous-histiocytic inflammation. Incision of the capsule allowed drainage of more than 500 mL of metallic black synovial fluid (Figure 5).

All prosthetic components were removed and the soft tissue and bone were cleaned with jet-lavage. A cemented total hip prosthesis, ENDO-Mark III, was implanted. At the time of revision increased concentrations of the alloy elements cobalt, chromium and molybdenum were measured in the serum. The concentration of cobalt in particular

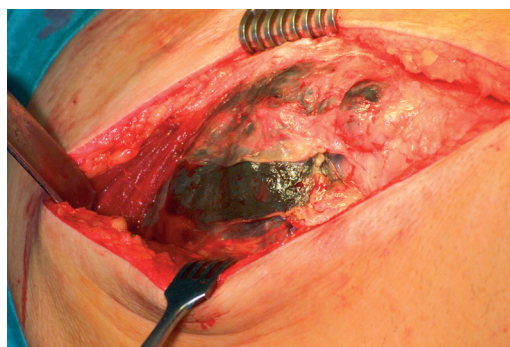


Figure 2. Soft tissue, capsule and bone adjacent to the component densely stained with black metal debris.



Figure 3. The femoral ball worn down to a cylinder.

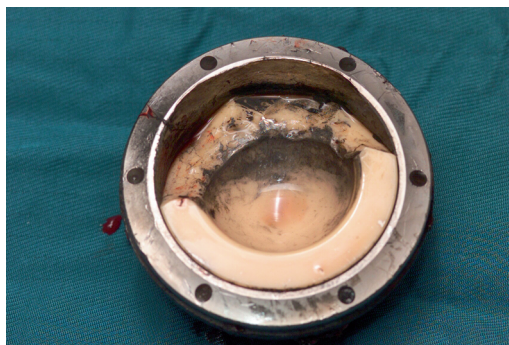

Figure 4. Smashed rim of the inlay.

Concentrations of elements in serum, cerebrospinal fluid (liquor) and hair

	Normal range	Pre-operatively	Post-operatively	8-week follow-up	6-month follow-up
Serum chrome, µg/L	< 0.4		56	25.4	12.2
Serum cobalt, µg/L	< 0.45		398	36.0	< 1.0
Serum molybdenum, µg/L	0.3–1.2		1.4	0.9	0.7
Liquor chrome, µg/L	< 3.0		0.8	–	–
Liquor cobalt, µg/L	< 2.6		3.2	–	–
Liquor molybdenum, µg/L	< 7.5		0.4	–	–
Hair cobalt, mg/kg	0.015–0.05	3.26		–	–

was remarkably high. Examination of cerebrospinal fluid (CSF) also showed an elevated cobalt concentration. Technical examination of the metal head showed debris of 79 g of cobalt and chromium. Follow-up tests showed decreasing serum concentrations of all the above-mentioned alloy elements (Table).

Postoperative ophthalmological examination showed a toxic atrophy of the optical nerve and retinopathy with malfunction of the macula which

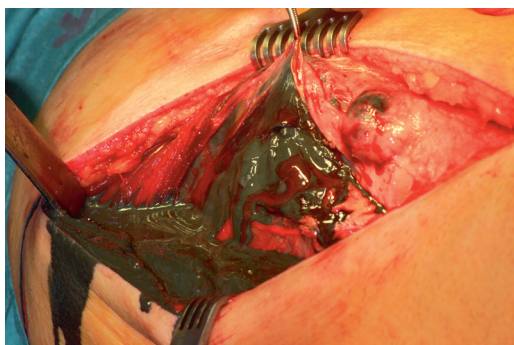


Figure 5. After incision of the capsule, more than 500 mL of metallic black fluid was drained.

recovered with time, however. Finally, the patient was able to work on a computer again using strong glasses. Audiometry revealed that his hearing was returning. The numbness of the feet and the dermatitis disappeared with time. To our knowledge, only one other case like this has been described (Hinrichs and Griss 2001).

Clinical features of cobalt poisoning

With regard to “non-endoprosthetic” exposure, only 2 case reports of optic atrophy caused by chronic cobalt poisoning have been published, one concerning a 32-year-old man treated for 15 weeks with cobalt chloride and another concerning a 48-year-old man 14 months after occupational exposure to cobalt powder (Licht et al. 1972, Meecham and Humphrey 1991).

Bilateral nerve deafness has been described following chronic occupational exposure to cobalt powder or during long-term treatment of anemia with cobalt chloride. Deafness typically resolves completely after discontinuation of exposure (Gardner 1953, Schirmacher 1967, Meecham and Humphrey 1991).

An allergic erythematous papular eruption, so-called “cobalt-itch” or “carboly-itch” may occur, usually in areas of skin subject to friction such as the sides of the neck, and flexor surfaces of elbows and ankles (Hathaway et al. 1996). Systemic exposure (ingestion, dental or loosened orthopedic prostheses) has been reported to induce sensitivity, causing local dermatitis over the area of the prosthesis or generalized dermatitis, and furthermore to exacerbate cobalt-induced contact dermatitis at a site distant from the site of exposure (Veien and Kaaber 1979, Lygre 2002). Treatment of chronic cobalt poisoning includes chelation therapy with EDTA or BAL/DMPS, but its efficacy is unclear.

Conclusion

Legislation in the EU states that surgeons are responsible for quality assurance and product liability if they mix components from different manufacturers. Our case is therefore another example of what every surgeon should know: never mix and match (Willmann 1998).

- Gardner F H. The use of cobaltous chloride in anaemia associated with chronic renal disease. *J Lab Clin Med* 1953; 41 (1): 56-64.
- Hathaway G J, Proctor N H, Hughes J P. *Chemical Hazards of the workplace*, 4th ed. Van Nostrand Reinhold Company, New York, NY, 1996.
- Hinrichs F, Griss P. Retrieved wear couple ceramic on metal: A case study. In: *Bioceramics in joint arthroplasty* (eds. Tony A, Willmann G). Thieme, Stuttgart New York, 2001: 94-98
- Licht A, Oliver M, Rachmilewitz E A. Optic atrophy following treatment with cobalt chloride in a patient with pancytopenia and hypercellular marrow. *Isr J Med Sci* 1972; 8 (1): 61-6.
- Lygre H. Prosthodontic biomaterials and adverse reactions: A critical review of the clinical and research literature. *Acta Odontol Scand* 2002; 60 (1): 1-9.
- Meecham H M, Humphrey P. Industrial exposure to cobalt causing optic atrophy and nerve deafness: A case report. *J Neurol Neurosurg Psychiatry* 1991; 54 (4): 374-5.
- Schirmacher U O. Case of cobalt poisoning. *Br Med J* 1967; 1 (539): 544-5.
- Veien N K, Kaaber K. Nickel, cobalt and chromium sensitivity in patients with pompholyx (dyshidrotic eczema). *Contact Dermatitis* 1979; 5 (6): 371-4.
- Willmann G. Ceramic sockets for total hip replacement. Part 4: Never mix and match. *Biomed Tech (Berl)* 1998; 43 (6): 184-6.