

## Functional outcome of surgical treatment for multi-level lumbar spinal stenosis

Zouboulis E Panagiotis, Karageorgos Athanasios, Dimakopoulos Panagiotis, Tyllianakis Minos, Matzaroglou Charis and Lambiris Elias

Department of Orthopedics, Patras University Hospital, GR-26504 Rio-Patras, Greece  
Correspondence AK: akarageorgos@hotmail.com  
Submitted 05-09-11. Accepted 06-01-12

**Background** There is no consensus regarding the best treatment of patients with multilevel lumbar stenosis. We evaluated the clinical and radiological findings in 41 patients with complex degenerative spinal stenosis of the lumbar spine who were treated surgically.

**Methods** Between 1997 and 2003, 41 patients suffering from degenerative lumbar spinal stenosis were included in a prospective clinical study. The spinal stenosis was multilevel in all patients and in 13 of them there was degenerative scoliosis, in 18 there was degenerative spondylolisthesis, and in 10 there was segmental instability. Plain radiographs, MRI and/or CT myelograms were obtained preoperatively. The patients were assessed clinically with the Oswestry disability index (ODI) and visual analog scale (VAS). Surgery included wide posterior decompression and fusion using a transpedicular instrumentation system and bone graft.

**Results** After a mean follow-up of 3.7 (1–6) years, the patients' clinical improvement on the ODI and VAS was statistically significant. Recurrent stenosis was not observed, and 39 of 41 patients were satisfied with the outcome. 3 patients with improvement initially had later surgery because of instability.

**Interpretation** The above-mentioned technique gives good and long lasting clinical results, when selection of patients is done carefully and when the spinal levels that are to be decompressed are selected accurately. ■

thesis or any combination of the above (Ehud and Susan 2001). It may form part of a generalized degenerative process at several spinal levels or may be more localized.

The etiological classification of lumbar spinal stenosis, as described by Arnoldi et al. (1976), distinguishes between congenital or developmental and acquired or degenerative stenosis. Spinal stenosis may cause chronic pain and difficulty in walking. Patients can undergo nonoperative treatment (Berthelot et al. 1997), surgical decompression (Atlas et al. 1996) or—together with decompression—stabilization with or without instrumentation (Brunon et al. 1996). Although there is a lot of interest in this topic, there has been a lack of randomized studies on effectiveness of the surgical treatment, and there has been even less published on the type of surgical treatment.

Our study refers to patients with multilevel degenerative spinal stenosis (2 or more spinal segments) and coexisting conditions such as spondylolisthesis or degenerative scoliosis leading to segmental instability. The patients were treated by wide decompression and instrumented spinal fusion with bone graft. We analyzed the outcome in terms of functional recovery and also the extent to which the results of surgery were long-lasting.

Spinal stenosis is the narrowing of the spinal canal, the lateral nerve root canals, or the neural foramen. This narrowing derives from facet or ligamentum flavum hypertrophy, extruded disc, spondylolis-

### Patients and method

Between 1997 and 2003, 41 (26 female) patients suffering from multilevel lumbar spinal stenosis

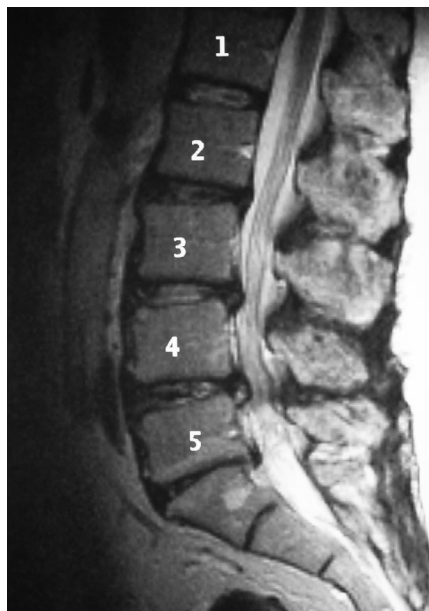


Figure 1. Preoperative evaluation using MRI.

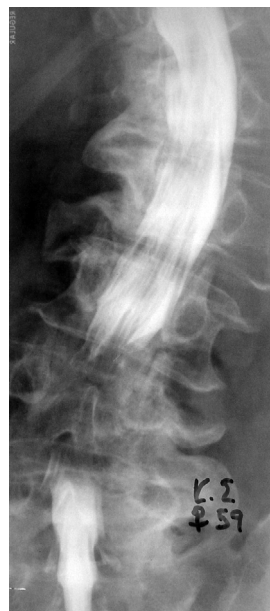

Figure 2. Preoperative evaluation using myelography in a case with degenerative scoliosis.

underwent posterior decompression and instrumented posterolateral fusion using transpedicular systems at our hospital. The average age of the patients was 61 (33–79) years.

#### *Clinical evaluation*

The patients underwent a thorough preoperative clinical (including neurological) and radiographic examination. Patients had suffered from spinal stenosis with serious symptoms (ODI > 30%; VAS > 5) of back pain and/or sciatica for periods ranging from 6 months up to many years. 3 patients had a peroneal paresis, 2 of them for more than 6 months and the third for 1 month. Initially, all patients underwent nonoperative treatment for a period of at least 6 months without clinical improvement. The neurological examination showed neurogenic intermittent claudication (31 patients, who could walk a maximum of 0.3 km) and/or nerve root pain syndrome (25 patients). The preoperative clinical test also included completing the Oswestry disability index (Fairbank et al. 1980) and the visual analog scale (0–10) for pain from the loins or lower extremities (Zanoli et al. 2001). Only 9 of the 10 parameters of the Oswestry disability scale were evaluated, the remaining parameter (involving sexual activity) being omitted.

All patients had to complete the above-mentioned test on admission to the department, under the supervision of an assistant not associated with the study. No patient suffered from serious cardiopulmonary co-morbidities.

#### *Radiological evaluation*

The preoperative radiographic examination included plain radiographs (face and profile) as well as flexion-extension radiographs. All patients underwent either an MRI or a myelography and CT myelogram, with MRI being the first choice (Figure 1). In patients suspected of having dynamic stenosis or a substantial degree of concurrent scoliosis, myelography and myelo-CT were chosen (Figure 2). The number of levels to be decompressed was decided preoperatively according to the findings from MRI or myelo-CT.

Degenerative scoliosis in 13 patients, spondylolisthesis in 18 patients (grade I in all cases) and segmental hypermobility (horizontal motion  $\geq 4$  mm and/or angular motion  $\geq 10^\circ$  as seen on dynamic radiographs) (Garfin et al. 2000) in 10 patients were also found. 4 of these patients had been operated on earlier (3 of them with discectomy and 1 with laminectomy).

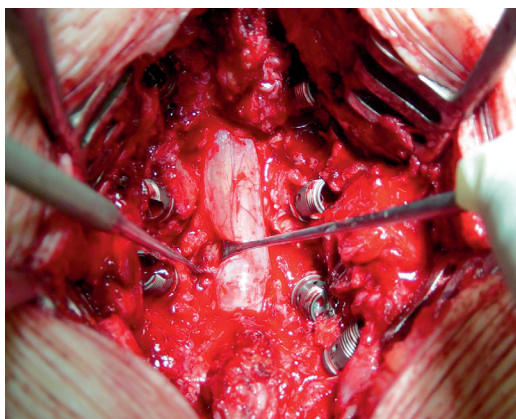


Figure 3. Wide posterior decompression and transpedicular screw placement.

### **Surgical technique**

The surgical technique started with pedicular screw fixation at levels to be decompressed. Next, wide decompression was done through a laminectomy, including the spinous process and the ligamentum flavum, from the outer edge of one lateral recess to the outer edge of the corresponding one (Figure 3). Decompression took place at those levels where the posterior segments placed significant pressure on the spinal cord, the cauda equina, or the exiting nerve roots, as confirmed by the radiological examinations and the patient's symptoms. This technique facilitated direct access to the meningeal sac, the roots that exit from it and the region where the roots enter the intervertebral foramen. In cases where there was pressure on the root in the lateral recess or the intervertebral foramen, a wide decompression was performed in those two structures. A concomitant discectomy at one or more levels was performed on 11 patients, since the preoperative examinations showed compression of the spinal sac and nerve roots by the intervertebral disc. In such cases, the posterior longitudinal ligament was maintained. The rods were then placed in order to stabilize the decompressed spinal column, to correct concomitant scoliosis (balancing), and to reconstitute normal sagittal alignment of the lumbar spine. In the cases where there was spondylolisthesis, it did not reduce. The operation was completed through the placement of autogenous and synthetic allografts between the exposed facets and transverse processes of decompressed vertebrae, in order to achieve posterolateral fusion.

13 patients underwent a 2-level spondylodesis, 12 patients a 3-level fusion, 9 patients a 4-level, 6 patients a 5-level and 1 patient a 7-level fusion. The most commonly affected levels were O3–O5, which were decompressed in 29 patients.

The average length of the operation was 3.8 (2–7) h. In all patients, blood retention was achieved through the use of a cell-saver. An average of 3 whole blood units was transfused per patient.

The patients were fully activated on the second postoperative day, with drainage removal. No protective body cast was used.

### **Follow-up**

Postoperatively, all patients underwent clinical monitoring by completing the Oswestry disability index and the visual analog scale on an annual basis. The forms were completed by the patients themselves. Patient satisfaction with regard to the functional outcome, as specified in their answers to the question about whether or not they would repeat the operation, was evaluated during the final review. Postoperative radiographic documentation included anteroposterior, lateral and flexion-extension plain films. With these views, stability of the fixed levels, fusion, and condition of the adjacent levels were evaluated. The criteria that were used to diagnose pseudarthrosis included evidence of radiolucency around the hardware, collapse of graft height with a gap between the vertebral and endplate and the bone graft, and loss of fixation due to hardware loosening or dislodgement. In addition,  $\geq 4$  mm of horizontal motion seen on dynamic anteroposterior and lateral radiographs and  $\geq 10^\circ$  of angular motion, as seen on lateral radiographs made with the patient bending, indicated postoperative instability (Garfin et al. 2000).

The mean follow-up time was 3.7 (1–6) years.

### **Statistics**

The differences that were observed diachronically (before the operation and 1, 2, 3, 4, 5, and 6 years after the operation) were evaluated by Friedman's parametric test, followed by the Wilcoxon signed ranks non-parametric test in order to compare the differences every two years before the operation and every year after the operation. In addition, one-way analysis of variance (ANOVA), followed by the Tukey test were used.

Results of Oswestry index parameters. The scale is graded 0–5, with 5 meaning maximum disability and 0 meaning minimum disability

	Preop.	1 year postop.	2 years postop.	3 years postop.	4 years postop.	5 years postop.	6 years postop.
Pain	3.22	0.68	0.76	0.64	0.48	0.67	0.20
Personal care	2.51	0.41	0.46	0.42	0.35	0.53	0.20
Lifting	3.22	0.80	1.11	1.26	1.26	1.00	0.60
Walking	3.38	1.05	0.97	1.19	1.17	1.40	1.40
Sitting	2.56	0.51	0.65	0.61	0.39	0.60	0.40
Standing	3.71	1.44	1.43	1.52	1.52	1.73	2.60
Sleeping	3.00	0.37	0.40	0.42	0.30	0.53	0.20
Social life	3.24	1.27	1.08	1.26	1.30	1.33	0.80
Traveling	2.63	0.24	0.35	0.32	0.26	0.40	0.40

## Results (Table)

The average preoperative Oswestry index for the 41 patients was 61%. During the first year of follow-up, it decreased to 15% ( $p < 0.001$ ). The value for 37 patients evaluated 2 years after their operation was 16% ( $p < 0.001$ ) while the values for 31 patients completing 3 years of follow-up, 24 patients completing 4 years, 15 patients completing 5 years and 5 patients completing 6 years of follow-up were 16%, 16%, 18% and 16%, respectively, all representing a statistically significant improvement compared to preoperative values ( $p < 0.001$ ).

Specifically, the average preoperative pain intensity score (VAS) was 7.9. It decreased to 2.7 during the first postoperative year, to 2.6 during the second, to 2.5 during the third, to 2.4 during the fourth, and then increased to 3.1 during the fifth, and to 3.2 during the sixth postoperative year ( $p < 0.05$ ).

The Oswestry index improved postoperatively. Preoperatively, 22/41 patients were not able to walk at all or they could walk only with the use of crutches. 9 other patients were unable to walk more than 0.3 km. In the fourth postoperative year, all patients but 4 were able to walk more than 0.3 km. In the sixth postoperative year, all patients but 1 were able to walk more than 0.3 km.

In the final review, 39 of 41 patients stated that they would repeat the operation.

Pseudarthrosis was observed radiographically in 2 patients at the final follow-up. 1 patient suffered a loosened sacral screw (O1-I1 spondylodesis) and 1 patient presented with a broken sacral screw (O3-I1 spondylodesis). Both were treated by

revision surgery. Moreover, 3 patients developed instability at a cranial adjacent level and underwent spondylodesis expansion. The 5 patients who had to undergo a second surgical operation due to mechanical symptoms improved postoperatively according to the Oswestry disability index and the visual analog scale. The postoperative radiographs in the remaining patients showed bridging bone bilaterally between transverse processes with trabeculation that was confluent across the fusion mass, and less than 2 mm motion, without instability at the adjacent levels.

A meningeal rupture occurred intraoperatively in 3 patients and was directly repaired with suture. Postoperatively, the patients followed the same rehabilitation protocol without any further complications. There were three superficial wound infections, which were treated with intravenous antibiotic therapy.

2 of the 3 patients with preoperative peroneal paresis improved in muscle strength after the operation. All 3 patients stated that they had remission of symptoms from the back.

## Discussion

Surgical treatment of lumbar spinal stenosis has two aims. The first is the decompression of neural structures (cauda equina and nerve roots), which are mechanically compressed by the degenerative tissues that form the spinal canal and the intervertebral foramina. The second aim is the correction of deformities on a sagittal and coronal plane and

the maintenance of spinal column stability.

Wide decompressive laminectomy is the commonest technique for decompression of neural structures. To avoid destabilization of the spinal column postoperatively, alternative decompression techniques have been established to maintain posterior bony and ligamentous elements. Such techniques include selective single or multiple unilateral or bilateral laminotomy (Postacchini et al. 1993, Sanderson et al. 1996), multilevel partial laminectomy (Solini et al. 1992), and lumbar laminoplasty (Matsui et al. 1992). Nevertheless, the problem of bone re-growth with clinically significant recurrent stenosis is more common when restricted bone removal techniques have been employed (Postacchini and Cinotti 1992).

The technique we used was standard wide decompressive laminectomy because all patients suffered from high-level stenosis (ODI > 30%, VAS > 5) (central and lateral) at 2 or more levels. 3 of 41 patients had intraoperative meningeal rupture, which is quite a low number, and no patient developed deficit of a single nerve root after surgery. The complications are comparable to those of multiple laminotomies; Postacchini et al. (1993) reported 1 dural tear and 3 nerve root deficits after surgery in 26 patients. We did not observe recurrent stenosis, which deteriorates the clinical improvement, in our patients.

Surgical stabilization is recommended in cases of preoperative instability or iatrogenic instability (Brunon et al. 1996), major intraoperative movement of vertebral segments in the elderly (Conley et al. 1990), relapsing symptoms with spondylolisthesis (Brunon et al. 1996), concurrent scoliosis (Simmons and Simmons 1992), and concurrent spondylolisthesis (Herkowitz 1994). However, there are no clear-cut indications for surgical stabilization.

In patients with spinal stenosis and concurrent spondylolisthesis, Fischgrund et al. (1997) found that the use of pedicle screws after decompression and posterior spondylodesis may lead to a higher fusion rate, but no better outcome. On the other hand, Kornblum et al. (2004) found better outcome in patients with solid fusion. In our study, 39/41 patients had solid fusion. 2 who suffered from concurrent spondylolisthesis showed pseudarthrosis. Furthermore, instability at a cranial adjacent ver-

tebral level was observed in 3 patients who then underwent fusion expansion. 2 patients underwent spondylodesis at 5 vertebral levels, and the third patient at 4 levels.

Regarding spinal stenosis with concurrent scoliosis, the literature recommends instrumented stabilization for the following reasons: (1) wide decompression causes additional destabilization of the scoliotic spinal column involved (Katz et al. 1997), and (2) without instrumentation, the rate of patients with solid fusion is less and there is no possibility of correcting deformities in a sagittal and coronal plane (Katz et al. 1997). In cases of degenerative scoliosis, an attempt to straighten the spinal column through spondylodesis with instrumentation is also recommended (Simmons 2001). 13 patients in our study suffered from concurrent scoliosis. In 10 of them, there was deformity correction in the coronal plane, and in 3 of them deformity correction in the coronal and sagittal plane took place. All patients had substantial clinical improvement and solid fusion.

We used the pedicular screw and parallel rod fixation technique in all our cases of posterior spondylodesis. This technique is better than any other system with regard to stabilization of the spinal column, especially under rotation forces (Shirado et al. 1991). The vertebral body pedicles are the stoutest parts of the vertebrae, and can be used for support in wide decompressions where the posterior elements have been removed. Moreover, as they act anteriorly on the rotation axis, they allow better correction on a sagittal and coronal plane in cases of concurrent scoliosis. Finally, pedicular systems—when compared to conventional extrapedicular systems—achieve stability with osteosynthesis of fewer vertebral levels (Liu et al. 1990).

In typical forms of spinal stenosis, the intervertebral disc is usually not involved. In some cases, however, a disc protrusion may cause symptoms due to pressure on the nerve roots within the intervertebral foramen. In such cases, posterior decompression should be accompanied by discectomy (Postacchini 1999). Discectomy must be performed unilaterally, to preserve the posterior longitudinal ligament and avoid destabilization of the anterior column. We performed a concomitant discectomy in 11 of our 41 patients. This is a rather

high percentage compared to other studies (Garfin et al. 2000). The preoperative radiographic examination of these patients revealed significant compression of neural elements by an extruded disc and all patients had clinical symptoms of nerve entrapment.

In conclusion, we found that wide posterior decompression, when applied with posterolateral-instrumented fusion, offers promising and reproducible clinical and radiographic results in patients suffering from multilevel lumbar spinal stenosis and instability (degenerative scoliosis and/or degenerative spondylolisthesis). Significant bone regrowth causing recurrent stenosis was not observed, due to wide decompression and stabilization of the spinal column.

#### Contributions of authors

ZEP and LE were the main surgeons. KA and MC performed preoperative evaluation and clinical follow-up. DP and TM performed the statistical analysis.

No competing interests declared.

- Arnoldi C C, Brodsky A E, Cauchoix J, Crock H V, Dommisse G F, Edgar M A, Gargano F P, Jacobson R E, Kirkaldy-Willis W H, Kurihara A, Langenskiold A, Macnab I, McIvor G W, Newman P H, Paine K W, Russin L A, Sheldon J, Tile M, Urist M R, Wilson W E, Wiltse L L. Lumbar spinal stenosis and nerve root entrapment syndromes. Definition and classification. *Clin Orthop* 1976; (115): 4-5.
- Atlas S J, Deyo R A, Keller R B, Chapin A M, Patrick D L, Long J M, Singer D E. The Maine Lumbar Spine Study, Part III. 1-year outcomes of surgical and nonsurgical management of lumbar spinal stenosis. *Spine* 1996; 21 (15): 1787-94.
- Berthelot J M, Bertrand-Vasseur A, Rodet D, Maugars Y, Prost A. Lumbar spinal stenosis: a review. *Rev Rhum Engl Ed* 1997; 64 (5): 315-25. Review.
- Brunon J, Chazal J, Chirossel J P, Houteville J P, Lagarrigue J, Legars D, Moreau J J, Perrin G, Tremoulet M. When is spinal fusion warranted in degenerative lumbar spinal stenosis? *Rev Rhum Engl Ed* 1996; 63 (1): 44-50. Review.
- Conley F K, Cady C T, Lieberman R E. Decompression of lumbar spinal stenosis and stabilization with Knodt rods in the elderly patient. *Neurosurgery* 1990; 26 (5): 758-63.
- Ehud A, Susan P. Lumbar stenosis. A clinical review. *Clin Orthop* March 2001; (384): 137-43.
- Fairbank J C, Couper J, Davies J B, O'Brien J P. The Oswestry low back pain disability questionnaire. *Physiotherapy* 1980; 66 (8): 271-3.
- Fischgrund J S, Mackay M, Herkowitz H N, Brower R, Montgomery D M, Kurz L T. 1997 Volvo Award winner in clinical studies. Degenerative lumbar spondylolisthesis with spinal stenosis: a prospective, randomized study comparing decompressive laminectomy and arthrodesis with and without spinal instrumentation. *Spine* 1997; 22 (24): 2807-12.
- Garfin S R, Herkowitz H N, Mirkovic S. Spinal stenosis. *Instr Course Lect* 2000; 49: 361-74. Review.
- Herkowitz H N. Lumbar spinal stenosis: indications for arthrodesis and spinal instrumentation. *Instr Course Lect* 1994; 43: 425-33. Review.
- Katz J N, Lipson S J, Lew R A, Grobler L J, Weinstein J N, Brick G W, Fossel A H, Liang M H. Lumbar laminectomy alone or with instrumented or noninstrumented arthrodesis in degenerative lumbar spinal stenosis. Patient selection, costs, and surgical outcomes. *Spine* 1997; 22 (10): 1123-31.
- Kornblum M B, Fischgrund J S, Herkowitz H N, Abraham D A, Berkower D L, Dittkoff J S. Degenerative lumbar spondylolisthesis with spinal stenosis: a prospective long-term study comparing fusion and pseudarthrosis. *Spine* 2004; 29 (7): 726-33; discussion 733-4.
- Liu Y K, Njus G O, Bahr P A, Geng P. Fatigue life improvement of nitrogen-ion-implanted pedicle screws. *Spine* 1990; 15 (4): 311-7.
- Matsui H, Tsuji H, Sekido H, Hirano N, Katoh Y, Makiyama N. Results of expansive laminoplasty for lumbar spinal stenosis in active manual workers. *Spine (Suppl 3)* 1992; 17: S37-40.
- Postacchini F. Surgical management of lumbar spinal stenosis. *Spine* 1999; 24 (10): 1043-7. Review.
- Postacchini F, Cinotti G. Bone regrowth after surgical decompression for lumbar spinal stenosis. *J Bone Joint Surg (Br)* 1992; 74 (6): 862-9.
- Postacchini F, Cinotti G, Perugia D, Gumina S. The surgical treatment of central lumbar stenosis. Multiple laminotomy compared with total laminectomy. *J Bone Joint Surg (Br)* 1993; 75 (3): 386-92.
- Sanderson P L, Getty C J. Long-term results of partial undercutting facetectomy for lumbar lateral recess stenosis. *Spine* 1996; 21 (11): 1352-6.
- Shirado O, Zdeblick T A, McAfee P C, Warden K E. Biomechanical evaluation of methods of posterior stabilization of the spine and posterior lumbar interbody arthrodesis for lumbosacral isthmic spondylolisthesis. A calf-spine model. *J Bone Joint Surg (Am)* 1991; 73 (4): 518-26.
- Simmons E D. Surgical treatment of patients with lumbar spinal stenosis with associated scoliosis. *Clin Orthop* 2001; (384): 45-53.
- Simmons E D Jr, Simmons E H. Spinal stenosis with scoliosis. *Spine (Suppl 6)* 1992; 17: S117-20.
- Solini A, Paschero B, Ruggieri N, Paladini Molgora A. Lumbar stenosis surgery: "recalibrage" according to Senegas. *Chir Organi Mov* 1992; 77 (1): 55-9.

Zanoli G, Strömqvist B, Jönsson B. Visual analog scales for interpretation of back and leg pain intensity in patients operated for degenerative lumbar spine disorders. *Spine* 2001; 26 (21): 2375-80.