

Long-term results of a soft interface- (Proplast-) coated femoral stem

Jon H M Goosen¹, René M Castelein², Wouter C Runne³, Denis A Dartee³ and Cees C P M Verheyen¹

Department of ¹Orthopaedic Surgery and Traumatology, Isala Clinics, Weezenlanden Hospital, Zwolle, Departments of Orthopaedic Surgery, ²University Medical Hospital Utrecht, Utrecht, the Netherlands, and ³Jeroen Bosch Hospital, 's-Hertogenbosch, the Netherlands
Correspondence CCPMV: C.C.P.M.Verheyen@isala.nl
Submitted 05-10-14. Accepted 06-02-04

Background Mid-term clinical results of uncemented femoral components with a Proplast coating have been unfavorable and the low modulus system was abandoned in the mid-1990s. There are, however, still substantial numbers of patients with a Proplast-coated prosthesis in situ. We evaluated the clinical and radiographic results in patients with 8–13 year follow-up.

Methods We evaluated the survival rate, Harris Hip score and radiographic features of 82 hips in 69 patients. Mean age at operation was 58 (35–72) years.

Results With respect to the Harris Hip score (HHS), 21% of the hips were considered to be clinical failures (HHS < 70) at final follow-up, mainly because of excessive thigh pain. Osteolysis was observed in one or more Gruen zones in one-third of the hips. According to the criteria of Engh, 79/82 stems were unstable. 11 hips were eventually revised due to aseptic loosening. Survival of the femoral component of the original cohort at final follow-up was 84% (95% CI: 75–93) in a standard-case scenario.

Interpretation Extensive signs of loosening were observed in almost all hips, while not all hips were considered to be clinical failures. Thus, all patients should be thoroughly screened for radiographic progressive osteolysis or the occurrence of thigh pain. Thigh pain or progressive osteolysis warrants revision of the Proplast-coated femoral stem.

forced with carbon fiber or aluminium oxide was introduced as Proplast. Proplast was considered to exhibit extraordinary chemical and thermal resistance, permitting fusion to metallic implants (Homsey 1972). As the elasticity of Proplast matches that of the surrounding cancellous bone, it was expected to have the advantage of a more natural transfer of stress, causing less stress shielding and aseptic loosening (Sadr and Arden 1977). In animal studies, a rapid ingrowth and a ready adherence to the surrounding tissue was observed (Homsey et al. 1972). Despite the possible theoretical benefits, mid-term clinical results on uncemented femoral components with a Proplast coating were not favorable (Sadr and Arden 1977, Bryan et al. 1981, Tullos et al. 1984, Maathuis and Visser 1996). Because of these reports, the low modulus system was considered to be a failure and was abandoned by our clinic in the mid-1990s. Today, there is still a substantial number of patients with a Proplast-coated prosthesis in situ. We evaluated the long-term clinical and radiographic results in this group of patients in order to be able to issue guidelines on when revision is indicated.

Patients and methods

We studied 100 consecutive primary cementless total hip arthroplasties performed between 1992 and 1997 in 83 patients with a minimum 8-year follow-up. 17 patients were operated bilaterally. 9

In the early 1970s, a soft-interface coating of a composite of polytetrafluoroethylene (PTFE) rein-

patients died before the minimum 8-year evaluation period (13 hips). None of these deaths were related to the index operation. 2 patients moved and were unable to return for follow-up. 3 patients underwent a revision before the minimum follow-up period, 2 in the first year after implantation and 1 after 2 years. All early revisions were due to aseptic loosening of the femoral stem. Thus, 18 hips in 14 patients were excluded, leaving 82 hips in 69 patients for clinical and radiographic follow-up (Table 1). The mean follow-up time was 10.2 (8–13) years.

All patients included received a Bitek femoral endoprosthesis (Biomet, Warsaw, IN). This uncemented femoral prosthesis was designed for a soft-interface coating that is a composite of polytetrafluoroethylene reinforced with aluminium oxide (Proplast II coating). A cemented acetabular component (SHP Promotion; Biomet) was used in 32 hips. In 50 hips an uncemented acetabular component (Mallory-Head/Ringloc liner; Biomet) was used. All hips were implanted using the direct lateral approach according to Hardinge (1982).

Clinical and radiographic evaluations were performed at 3 and 6 months, at 1 year, and annually thereafter. Harris Hip score was monitored and values < 70 were considered a clinical failure. Signs of endosteal condensation and osseointegration (spot welding) and the presence of radiodense or radiolucent lines were recorded in each Gruen zone (Engh et al. 1990). The time when these observations first occurred was noted. Pedestal formation (endosteal reactive radiodensity, distally from the tip of the stem), osteolysis, grading of stress shielding (Engh et al. 1987) and cortical hypertrophy were assessed. An increase in the distance between the superior tip of the greater trochanter and a standard point at the prosthesis of 5 mm or more was recorded as subsidence (Malchau et al. 1995). On all radiographs the magnification was based on the size of the femoral head; therefore, all measurements were corrected individually. The radiographic state of bone ingrowth was evaluated according to Engh et al. (1990).

Statistics

Kaplan-Meier analysis of the survival of the femoral component was performed for all hips in the original cohort. We determined the best-case sce-

Table 1. Patient characteristics

Patients (n = 69)	
Women/men	38/31
Height (m)	1.66 (1.45–1.87)
Weight (kg)	80 (57–109)
Body mass index	29 (21–35)
Age at operation (yr)	58 (35–72)
Follow-up average (yr)	10.2 (8–13)
Hips (n = 82)	
Diagnosis	
Osteoarthritis	76
Osteonecrosis	1
Developmental dysplasia	4
Post-trauma	1
Right/left side	46/36

Table 2. Clinical outcome at the latest follow-up

Clinical outcome	Hips	Harris Hip score (SD)	Pain sub-score (SD)
Excellent	19	96 (3.7)	43 (1.8)
Good	36	84 (2.4)	39 (3.8)
Fair	10	73 (3.1)	35 (5.8)
Poor	17	48 (15)	17 (9.2)

nario (in which all hips with less-than-complete follow-up were considered to have had a successful result throughout the study period), standard-case scenario (in which all hips with less-than-complete follow-up were considered to have had a successful result at the time of the last follow-up) and worst-case scenario (in which all hips with less-than-complete follow-up were considered to have failed). The analyses were performed using SPSS software, version 11.0.

Results

The mean preoperative Harris Hip Score was 56 (30–78) with a subscore of 15 (10–30) points for pain (Table 2). At the latest follow-up, these scores were 78 (25–100) and 34 (10–44), respectively. 17 hips (21%) were rated as poor and were therefore considered clinical failures. 22 patients (32%) complained of thigh pain; 14 of these had severe pain and were compromised in their daily activities.

Endosteal osseointegration (spot welds) in one or more Gruen zones was observed in 47 hips

Table 3. Prevalence of radiographic parameters according to Engh (1987, 1990)

Parameter	Prevalence hips (%) (n = 82)	Time of first observation in years (SD)
Spot welds	47 (57)	1.3 (0.57)
Radio-dense lines	78 (95)	1.2 (0.91)
Stress shielding		
Grade 1	60 (73)	1.0 (0.13)
Grade 2	50 (61)	1.9 (0.14)
Grade 3	10 (12)	2.3 (0.50)
Grade 4	–	–
Cortical hypertrophy	13 (16)	2.1 (1.2)
Pedestal	13 (16)	3.3 (1.1)
Intramedullary osteolysis	25 (30)	3.2 (2.2)
Subsidence	70 (86)	0.3 (0.09)

(57%) (Table 3). 91% of the spot welds present were observed in Gruen zone VII (calcar). The observed radioactive lines were dense and in all cases they were located at least in Gruen zone I (greater trochanter). In 82% of the cases, the dense lines reached to the tip of the stem (Gruen zone IV). The thickness of the lines was generally over 1 mm (70%). Subsidence was observed in 70 hips (86%), with a mean value of 12 (5–27) mm.

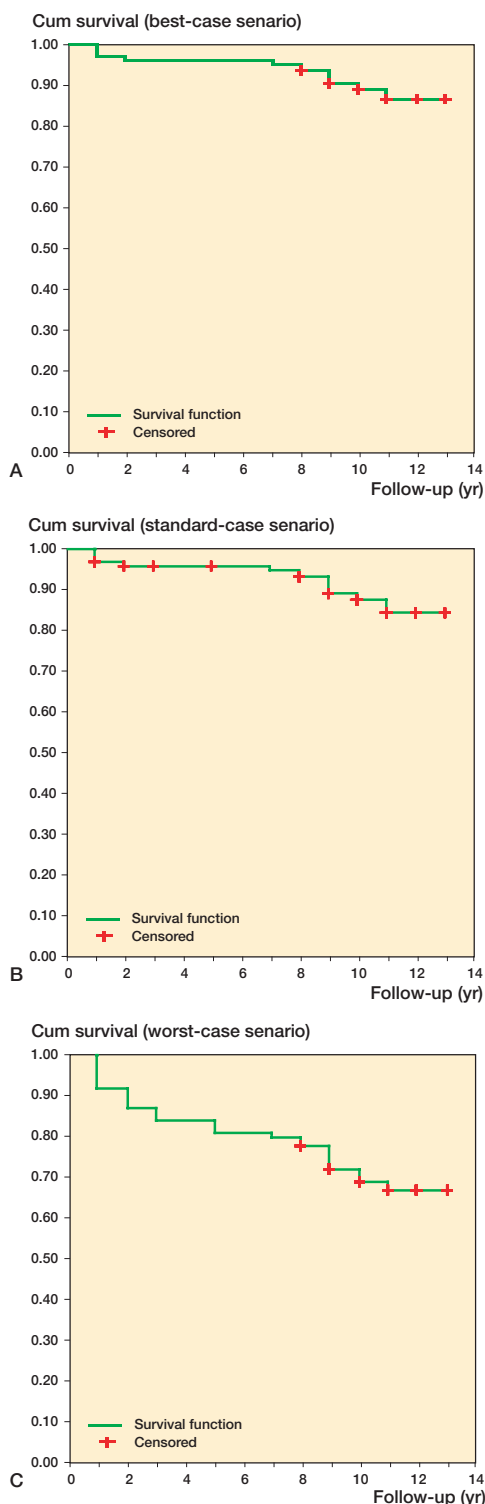
Stress shielding was observed in 60 hips (73%). All 60 hips showed grade-1 stress shielding (rounding of the calcar) at 1 year. 50 hips showed progression to grade-2 stress shielding (also loss of medial cortical density in zone 1) between the first and second years of follow-up. The progression continued to grade-3 stress shielding (loss of medial cortical density up to zone 2) in 10 hips (15%) between the second and third years of the follow-up.

25 hips (30%) showed intramedullary osteolysis of the femoral canal, mainly (21 hips) in Gruen zone VII (calcar). In the other 4 hips, the osteolysis was observed in Gruen zone IV (tip of the stem). The signs of osteolysis occurred at a mean follow-up of 3 (1–9) years. No difference in the occurrence of femoral osteolysis was found when uncemented or cemented sockets were used. According to the criteria of Engh, 96% of the hips were unstable. 11 revisions were performed because of suspected aseptic loosening. All hips were found to be loose at revision. 8 hips were revised during the 8–13 year follow-up period. Survival of the original

cohort at final follow-up was 86% (95% CI: 79–93) in a best-case scenario, 84% (95% CI: 75–93) in a standard-case scenario and 67% (95% CI: 57–77) in a worst-case scenario (Figure).

Discussion

Reports of high rates of failure of cemented femoral components in younger and more active patients have stimulated the development of implant fixation without cement (Barrack et al. 1992, Heekin et al. 1993). The transfer of load from the prosthesis to the femur alters the pattern of the natural stress transfer and varies according to the shape and stiffness of the implant (Huiskes et al. 1990). In the early 1970s, a rigid stem with a soft coating (low-modulus system) was introduced, based on the hypothesis that a high-modulus strength implant would be incompatible with effective surface stabilization because of an unnatural stress transfer through the surrounding tissue. A low-modulus coating would rapidly become infiltrated with fibrous tissue and would then transfer stress diffusely through the coating, resulting in a physiological stimulus to the maturation of the tissue into appropriate stress-supporting structures (Homsey et al. 1972). Polytetrafluoroethylene (PTFE) with carbon or aluminium oxide (Proplast I or II, respectively) was marketed as the coating that would meet the criteria of this model. PTFE, which exhibits extraordinary chemical and thermal resistance, can be firmly fused to a high-modulus substrate. Proplast was also thought to show no distinct yield stress and to demonstrate massive tissue ingrowth because of the relatively high pore size of 100–500 µm (Homsey et al. 1972). In studies on dogs by the developer of Proplast, the coating was seen to be thoroughly infiltrated with dense mature collagen by 10 weeks and with bone by 15 months, while no cellular inflammatory elements were found (Homsey et al. 1972). In another study, performed by independent investigators, Proplast-coated femoral prostheses were implanted into 12 goats and were observed clinically and radiographically for the first year postoperatively, with necropsy at the 1-year follow-up. Only 4 hips were found to be stable. These poor results were attributed to a lack of durable fixation after initial stabilization, allow-



Survival plots for different scenarios: best-case (A), standard-case (B) and worst-case (C).

ing movement at the interface between bone and the PTFE coating (Parvongnokul and Lump 1978). Another study reported that particles of abraded PTFE could give rise to an intense foreign-body reaction and produce collections of encapsulated caseous material, identical to the behavior of bone and joint tuberculosis (Charnley 1963). Here we have reported the outcome of the largest series to date, with the longest reported follow-up of a soft interface-coated femoral stem.

Regarding clinical outcome, 21% of the hips failed and 32% were associated with thigh pain. Similar studies with fewer patients and a shorter follow-up time have reported clinical failures in 58%, 36%, 12% and 8% of cases (Tullos et al. 1984, Keet and Runne 1989, Runne et al. 1989, Maathuis and Visser 1996). According to the criteria of Engh et al. (1990), 96% of the hips were rated as unstable and were considered to be loose. These findings were not associated with the clinical outcome of the patients. Other authors have stated that radioactive lines are not always associated with loosening, and it is not possible to determine whether the radiolucency on the radiograph is due to demarcation or to bone ingrowth of the coating (Kwong et al. 1992). From these statements and our findings, we conclude that the clinical performance and the presence of extensive osteolysis in a patient with a Proplast-coated femoral endoprosthesis is an indication for revision surgery rather than radiographical instability of the implant.

In our study, one-third of the hips showed signs of intramedullary osteolytic lesions in one or more Gruen zones. PTFE particles from the femoral component can cause foreign-body reactions and can be slowly erosive when in contact with bone (Charnley 1963). The lesions can also be caused by foreign-body reactions to polyethylene particles from the acetabular component, driven into the femoral canal between the disintegrated femoral stem and the endosteal bone (Willert et al. 1989). One of the reasons for developing a soft-interface stem was prevention of bone resorption as a result of a different stress pattern (stress shielding) (Homsy et al. 1972). Moderate stress shielding (grade 3) was observed in one-tenth of the hips in our study; none of the hips showed severe stress shielding (grade 4). An evaluation of 106 conventional (high-modulus) femoral implants with the same configuration

as the Bitek showed 16% grade-3 and 6% grade-4 stress shielding after a mean follow-up of 8.3 years. Despite a higher incidence of severe stress shielding, this high-modulus variant showed an excellent clinical outcome: 100% radiographic stability and fixation at the 8-year final follow-up (Goosen et al. 2005). Kärrholm et al. (2002) randomized patients (68 hips) to receive either a low- or a high-modulus stem. Using an absorptiometer, they observed a statistically significant reduction in bone mineral loss around the low-modulus stem in the proximal Gruen zones at the 2-year follow-up. No differences in clinical performance were observed after this short follow-up period. Another study showed a statistically significantly lower Harris Hip score and a more intense bone remodeling when measuring bone mineral density using a DEXA scan in the patients with a low-modulus stem compared to the situation with a high-modulus variant. The authors concluded that there was a less favorable host-bone response after long-term observation in 20 patients after 8 years (Bodén et al. 2004).

In conclusion, it can be stated that although several studies have judged the Proplast-coated prosthesis to be an absolute failure, a substantial number of patients—although having a radiographically loose prosthesis according to the criteria of Engh—still have this prosthesis in situ. These patients should be thoroughly screened for the occurrence of osteolysis. Poor clinical performance and the occurrence of thigh pain justify revision surgery.

Contributions of authors

JHMG design of project, clinical and radiographical latest follow-up, data-analysis, manuscript. RMC took part in manuscript processing and design. WCR took part in manuscript processing, started the prospective follow-up, surgeon of the patient group. DAD took part in manuscript processing, managed the prospective follow-up. CCPMV project leader, took part in final manuscript processing before submitting, design of research project and manuscript.

No competing interests declared.

Barrack R L, Mulroy R D, Harris W H. Improved cementing techniques and femoral component loosening in young patients with hip arthroplasty. A 12-year radiographic review. *J Bone Joint Surg (Am)* 1992; 74: 385-9.

- Bodén H, Adolphson P, Öberg M. Unstable versus stable uncemented femoral stems: a radiological study of periprosthetic bone changes in two types of uncemented stems with different concepts of fixation. *Arch Orthop Trauma Surg* 2004; 124: 382-92.
- Bryan W J, McCaskill B L, Tullos H S. Hip endoprosthesis stabilization with a porous low modulus stem coating. Factors influencing stabilization. *Clin Orthop* 1981; (157): 125-32.
- Charnley J. Tissue reactions to polytetrafluoroethylene. *Lancet* 1963; 2: 137.
- Engh C A, Bobyn J D, Glassman A H. Porous-coated hip replacement; the factors governing bone ingrowth, stress shielding and clinical results. *J Bone Joint Surg (Br)* 1987; 69: 45-55.
- Engh C A, Massin P, Suthers K E. Roentgenographic assessment of the biologic fixation of porous-surfaced femoral components. *Clin Orthop* 1990; (257): 107-27.
- Goosen J H, Swieringa A J, Keet J G, Verheyen C C. Excellent results from proximally HA-coated femoral stems with a minimum of 6 years follow-up. A prospective evaluation of 100 patients. *Acta Orthop* 2005; 76: 190-7.
- Hardinge K. The direct lateral approach to the hip. *J Bone Joint Surg (Br)* 1982; 64: 17-9.
- Heekin R D, Callaghan J J, Hopkinson W J, Savory C G, Xenos J S. The porous-coated anatomic total hip prosthesis, inserted without cement. Results after five to seven years in a prospective study. *J Bone Joint Surg (Am)* 1993; 75: 77-91.
- Homsy C A, Cain T E, Kessler F B, Anderson M S, Kessler F B, Anderson M S. Porous implant systems for prosthesis stabilization. *Clin Orthop* 1972; (89): 220-35.
- Huiskes R. The various stress patterns of press-fit, ingrown, and cemented femoral stems. *Clin Orthop* 1990; (261): 27-38.
- Kärrholm J, Anderberg C, Snorrason, F, Thanner J, Langeland, N, Malchau H, Herberts P. Evaluation of a femoral stem with reduced stiffness. A randomized study with use of radiostereometry and bone densitometry. *J Bone Joint Surg (Am)* 2002; 84: 1651-8.
- Keet G G, Runne W C. The Anaform endoprosthesis: a Proplast coated femoral endoprosthesis. *Orthopedics* 1989; 12: 1185-90.
- Kwong L M, Jasty M, Mulroy R D, Maloney W J, Bragdon C, Harris W H. The histology of the radiolucent line. *J Bone Joint Surg (Am)* 1992; 74: 67-73.
- Maathuis P G M, Visser J D. High failure rate of soft-interface stem coating for fixation of femoral endoprostheses. *J Arthroplasty* 1996; 11: 548-52.
- Malchau H, Kärrholm J, Wang Y X, Herberts P. Accuracy of migration analysis in hip arthroplasty. Digitized and conventional radiography, compared to radiostereometry in 51 patients. *Acta Orthop Scand* 1995; 66: 418-24.
- Parvongnokul K, Lump W V. Evaluation of polytetrafluoroethylene-graphite-coated total hip prostheses in goats. *Am J Vet Res* 1978; 39: 221-8.
- Runne W C, Van Sambeek K J M, Stierum J L, Van Tongerlo R B. Femoral endoprosthesis fixation with a soft, flexible low modulus stem coating. Four to six year clinical results. *Orthopaedics* 1989; 12: 529-35.

Sadr B, Arden G P. A comparison of the stability of Proplast-coated and cemented Thompson prostheses in the treatment of subcapital femoral fractures. *Injury* 1977; 8: 234-7.

Tullos H S, McCaskill B L, Dickey R, Davidson J. Total hip arthroplasty with a low-modulus porous-coated femoral component. *J Bone Joint Surg (Am)* 1984; 66: 888-98.

Willert H G, Buchhorn G H, Hess T. The significance of wear and material fatigue in loosening of hip prosthesis. *Orthopäde* 1989; 18: 350-69.