

Indirect patella fractures following ACL reconstruction

A review

Guan H Tay, Satish K Warriar and Guy Marquis

Department of Orthopedics, Royal Hobart Hospital, Tasmania, Australia
Correspondence SKW: satish96101@yahoo.com
Submitted 05-03-17. Accepted 05-06-03

The bone-patellar tendon-bone (BTB) graft has been popularized as a suitable graft for anterior cruciate ligament (ACL) reconstructions. Fracture of the donor patella, however, is a potential complication of this technique, with a reported incidence of 0–2% (Roberts et al. 1989, Daluga et al. 1990, Carangelo et al. 1995, Berg 1996, Ferrari and Bach 1998). Such a fracture has not been reported with the use of other types of graft.

We hypothesize that the mechanical forces are altered during graft harvest in patellar bone-tendon-bone grafts. With this review of the literature, we aim to highlight current understanding of indirect fractures of the donor patella (at the graft harvest site, and not the BTB graft itself), to describe the biomechanics, and to focus on the various techniques that have been employed to reduce the risk of fracture.

Methods

Following our first experience of an indirect patella fracture secondary to ACL reconstruction, we performed an extensive literature review using the key words “patella fracture” and “anterior cruciate ligament reconstruction”. A systematic computerized search of MEDLINE and PUBMED was conducted for potentially relevant publications. Further references were cross-referenced from bibliographies of articles that were identified. To be included in the review, studies had to include patellar fractures following ACL reconstruction. Articles were reviewed for incidence, age, time after ACL recon-

struction, bone graft, fracture configuration, donor site involvement and treatment.

Results

Our search returned 5 case reports and 8 series reports. 8 intraoperative fractures were recorded. From a total of 31 patella fractures following ACL reconstruction, there were 22 indirect fractures and 9 direct (Table). The average time until the occurrence of an indirect patella fracture after ACL reconstruction was 11 weeks, with an incidence rate of 0.55%. 12 of the indirect fractures were stellate in configuration, while 8 were transverse and 2 were undefined. 5 of 22 fractures occurred when climbing stairs (a high-risk activity). All reported cases of indirect patella fracture following ACL reconstruction occurred following patella BTB grafts and not using other grafts. The donor site was involved in only 12 of all cases, suggesting that the forces acting on the patella were altered after taking the graft.

Discussion

Course of ACL rupture

ACL rupture has been termed the “beginning of the end of the knee” (McDaniel et al. 1980, Satku et al. 1986). Whilst some patients can be managed non-operatively with intensive physiotherapy, bracing and modification of activities, those with persistent and severe symptoms require reconstruction (John-

Summary of reports of patella fracture during and after ACL reconstruction using central-third patella BTB grafts

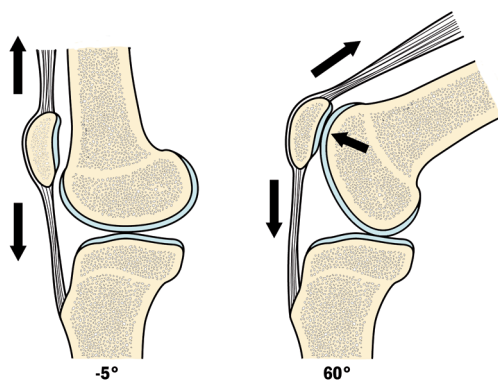
Study (Authors)	Incidence	Sex Age	Weeks after ACL recon.	Bone graft	Cause	Type	Donor site involved	Treatment
Stein et al. (2002)	8/618 (1.3%)	Mean 28	Mean 8	+	5 indirect 3 direct	3 nondispl. transverse 3 displaced transverse 2 displaced stellate	? ? ?	Nonoperative TBW ^a K-wires and TBW ^a
Viola and Vianello (1999)	3/1320 (0.2%)	M 25 M 24 F 39	5 8 6	–	Direct Direct Direct	Displaced transverse Displaced transverse Nondisplaced transverse	+ + +	TBW ^a Screws + TBW ^a TBW ^a
Benson and Barnett (1998)	CR ^b	M 16	52	+ ^c	Indirect	Nondispl. transverse ^d	–	Nonoperative
Brownstein and Bronner (1997)	CR ^b	F 34 F 23	6 7	–	Indirect Indirect	Displaced transverse Nondisplaced transverse	? ?	TBW ^a Nonoperative
Berg (1996)	3/133 (2%)	Fs F	16	–	Intraoper. Indirect	2 nondisplaced vertical 1 displaced transverse	+ ?	Screws Screws + TBW ^a
Simonian et al. (1995)	CR	M 44 F 32	5 3	+ +	Indirect Indirect	Nondisplaced stellate Displaced stellate	+ +	2 lag screws + cerclage wire 4 screws
Carangelo and Caputo (1995)	8/1497 (0.5%)	Mean 30	Mean 7	+	6 indirect 2 direct	8 stellate	8 +	2 nonoperative 6 lag screws ± TBW ^a
Ouwelleen and McElroy (1995)	CR ^b	M 21	2	–	Indirect	Avulsion ^e	+	Lag screws + TBW ^a + sutures ^e
Christen and Jakob (1992)	9/490 (1.8%)	All F 22–48		–	Intraoper.	6 fissuring intraoper.	+	2 screw fixation 1 cerclage + suture 3 nonoperative
		20	1	– ^f	Indirect	Displaced fracture of contralateral donor knee	?	Single lag screw + suture, cerclage
		M 23	3	– ^f	Indirect	Displaced stellate	?	Single lag screw + TBW – failed ^g
		M 29	12	– ^f	Direct	Displaced	?	TBW ^a + bone graft from iliac crest
Bonatus et al. (1991)	CR ^b	F 19	1	–	Indirect	Stellate + avulsion ^h	+	Lag screws + TBW ^a + suture ^g
McCarroll (1983)	CR ^b	M 23	26	–	Indirect	Displaced transverse	+	ORIF ⁱ

^a TBW Tension band wire^b Case report(s)^c Radiographs showed that bone graft had healed^d At superior pole of the patella^e Inferomedial quarter of patella and avulsion of lateral third of patella ligament. The latter repaired with Mitek Anchor sutures to patella tendon and side-to-side closure^f Graft reversed^g Repeated repair with bone graft from iliac crest^h Avulsion of lateral third of patella tendon. Repaired with Bunnell suture + staple to tibiaⁱ ORIF: open reduction internal fixation.

son et al. 1984). Young patients with a high level of physical activity will often require reconstruction.

Historically, many grafts have been used in reconstruction of a torn anterior cruciate ligament. The grafts used include semitendinosus, fascia lata, iliotibial tract and gracilis grafts. Noyes et al.

(1984) conducted a mechanical cadaveric study that compared these grafts with the patella BTB graft and showed the latter to be the superior graft when taken from the medial or central third of the patella. BTB grafts have the added advantage of allowing bone-to-bone union and do not sacrifice



Sagittal view through the knee. This diagram illustrates the 3-point bending stress exerted on the patella with knee flexion.

a significant stabilizer of the knee (D'Agata et al. 1993). The strength of the graft also permits immediate weight bearing and physiotherapy (Roberts et al. 1989, Bonatus and Alexander 1991, Berg 1996). This technique has now become the gold standard in ACL repair (Huberti et al. 1984, Goldstein et al. 1986, Roberts et al. 1989, Daluga et al. 1990, Lengsfeld et al. 1990, Bonatus and Alexander 1991, Sanders 1992, Shapiro et al. 1992, D'Agata et al. 1993, Carpenter et al. 1994, Berg 1996, Ferrari and Bach 1998).

Mechanics of patella fracture

The patella is the largest sesamoid bone and serves two primary functions. Firstly, as the insertion site of the quadriceps muscle, it transmits the tensile forces generated by the quadriceps to the patella ligament. Secondly, the patella acts to displace the quadriceps tendon-patella tendon linkage away from the axis of knee rotation. This increases the lever arm of the knee extension mechanism, analogous to that of a pulley (Sanders 1992, Carpenter et al. 1994, Stein et al. 2002).

In knee extension, the patella is subjected to two opposing forces in tension. However, in knee flexion there is an additional compressive force when the posterior aspect of the patella is in contact with the distal femur. This results in a transversely linear contact area with uniformly distributed contact pressures (Huberti et al. 1984, Carpenter et al. 1994) (see Figure). The contact area, which moves from distal to proximal with flexion, is subjected to maximal bending stress at all times (Lengsfeld et al. 1990). This bending force results in tensile forces

at the anterior surface of the patella that peak at 30° to 90° of flexion (Matthews et al. 1977, Huberti and Hayes 1984, Goldstein et al. 1986, Lengsfeld et al. 1990, D'Agata et al. 1993, Carpenter et al. 1994, Sharkey et al. 1997).

Patella surface strain and contact stresses during normal activities such as stair climbing can exceed the forces sustained by major weight-bearing joints, and have values close to that which can result in a fracture (Goldstein et al. 1986, Carpenter et al. 1994). This three-point bending configuration acting on an iatrogenically weakened patella is thought to cause indirect patella fractures (Carpenter et al. 1994).

Harvesting of the graft results in altered forces within the patella and may increase the risk of subsequent patella fractures. A change in orientation of principal surface strain was observed by Steen et al. (1999), from a longitudinal to a more transverse axis at the medial patella. Friis et al. (1994) reported a generalized increase in stress magnitude, especially superior to the graft site. An increase in mean axial strain at all degrees of flexion has also been recorded (Sharkey et al. 1997). Viola and Vionello (1999) reported that the superior transverse cut reduces the resistance of the patella by 30–40%. The strength of the patella tendon is also weakened by an average of 41% (Carpenter et al. 1993-94). Patellofemoral contact area and pressures remain unchanged after graft harvest (Eilerman et al. 1992, D'Agata et al. 1993, Sharkey et al. 1997).

McCarroll (1983) hypothesized that a decrease in vascularization was responsible for patella fractures. Benson and Barnett (1998) supported this theory and believed that the stress riser effect of the bone trough, and a relatively devascularized portion of the patella, was contributory.

The patellar blood supply is derived extraosseously and intraosseously (Sanders 1992, Benson and Barnett 1998). The extraosseous supply is largely preserved with graft harvesting. The intraosseous blood supply has three components: the midpatellar system, the polar system, and the quadriceps tendon system. Graft harvesting may disrupt the midpatellar and polar systems, which supply the mid- and distal patella. Hence, fractures may represent weakening due to relative devascularization of the patella (Benson and Barnett 1998).

The patella is further weakened by posttraumatic osteopenia. Bone loss is most rapid during the first few weeks of immobilization, and has been shown to be reduced by 7% even 12 months after ACL reconstruction (Sievanen et al. 1994).

Fracture types

Intraoperative patella fractures are often the result of technical inaccuracy (Roberts et al. 1989, Christen and Jakob 1992, Berg 1996, DuMontier et al. 2001). Postoperative patella fractures can occur with direct or indirect trauma. Rapid contraction of the quadriceps muscle with the knee in flexion can produce two types of indirect patella fractures namely, Y-shaped stellate fractures or transverse fractures. Stellate fractures tend to occur in the immediate postoperative period and are believed to be due to abnormal lateral patellar tracking with a background of a deconditioned vastus medialis or iatrogenically weakened patella. The timing and fracture configuration suggests that the harvest site acts as a source of stress, initiating failure. Thus, with donor site healing and muscle reconditioning, the majority of indirect patella fractures tend to be transverse (Simonian et al. 1995).

Management of patella fractures

Regardless of fracture type, the major issue governing treatment is displacement. Undisplaced fractures can be treated nonoperatively with good results (Carpenter et al. 1994). Transverse fractures with loss of active knee extension, fracture separation of greater than 3 mm, or an articular step greater than 2 mm require open reduction and internal fixation (Sanders 1992, Carpenter et al. 1994). The treatment of choice for displaced transverse fractures with or without mild comminution is the anterior tension band wire technique. This ensures quadriceps continuity, as well as stable anatomical reduction of the patellar articular surface (Sanders 1992, Carpenter et al. 1994). Early passive and active motion is encouraged with limited weight bearing in an extension splint. Viola and Vianello (1999) suggested surgery for all cases to promote early mobility and muscle-strengthening exercises. Christen and Jakob (1992) advocated bone grafting of the patella fracture with cancellous bone graft from the iliac crest, to prevent delay in union. In patients with severely comminuted fractures, par-

tial or total patellectomy may be considered (Sanders 1992, Carpenter et al. 1994).

Prevention of fracture

With healing, defects of the bony trough may fill up with fibrous tissue. This fibrous tissue lacks the strength and resistance of the anterior cortical bone of the patella, causing increased stresses which may predispose it to fracture (Stein et al. 2002). Patella defects are still palpable up to 3 years after patellar bone-to-bone grafts, indicating that spontaneous refilling occurs very slowly, if at all (Sharkey et al. 1997).

To regain the structural integrity of the patella, many authors have advocated bone grafting intraoperatively (Roberts et al. 1989, Daluga et al. 1990, Sharkey et al. 1997, Ferrari and Bach 1998). Primary bone grafting is believed to reduce the stress riser effect, donor site pain and fracture risk, while increasing bone healing. Bone grafting is recommended for defects greater than 10 mm in diameter and 6 mm in depth (Daluga et al. 1990). To simulate a healed bone graft, Sharkey et al. (1997) used polymethylmetacrylate to fill the patellar defect. Their results showed that the average axial strain measured with the defect filled was not significantly different from that of an intact patella.

Despite bone grafting, numerous cases of patella fractures have been recorded (Table). Few studies have looked at bone graft survival in the clinical and radiographic context. Martin et al. (1996) reported that despite bone grafting in 14 patients, the defect remained palpable in 13 patients at an average of 1.5 years, with radiographical evidence of complete healing in only 8 of the patients.

Three studies involving 1,187 patients recorded no cases of patella fracture following bone grafting of the patella defect (Roberts et al. 1989, Daluga et al. 1990, Ferrari and Bach 1998). Stein et al. (2002) reported 5 cases of indirect patella fracture in 618 patients despite bone grafting of the patella defect. However, no data have been published to unequivocally substantiate the idea that bone grafting either reduces the incidence of patella fractures or enhances healing of such fractures (Berg 1996). Possible heterotrophic bone formation has been cited as an argument against bone grafting (Berg 1996); however, Ferrari and Bach (1998) found no cases in 693 patients.

The size, shape and technique of patella graft harvest have been the subject of much interest in prevention of patella fracture. Different recommendations have been given regarding the appropriate size of graft. The size of the bone plug should be tailored to the size of the individual patella, and the upper margin should not extend beyond the equator (Christen and Jakob 1992). The depth of the graft should not exceed one-third of the depth measured preoperatively (Malek et al. 1996), or 10 mm (Christen and Jakob 1992). The width should not exceed 13 mm proximally or 10 mm distally, which equates to approximately one-third of the width of the patella (Christen and Jakob 1992). Christen and Jakob (1992) advocated harvesting a larger bone graft from the tibia and reversing the graft to reduce the amount of patella removed.

Steen et al. (1999) found that the graft harvest induced a significant redistribution of surface strain, which was not influenced by the shape of the defect. The cadaveric study of DuMontier et al. (2001) also showed no difference in the ultimate tensile strength between circular, triangular and rectangular defects in the patella. However, transpatellar fractures that extended through the patella defect tended to occur more frequently in the latter two. This was attributed to sharp corners acting as stress risers. Daluga et al. (1990) reported that trapezoidal bone plugs with edges at 45 degrees gave good results. However, Friis' (1994) cadaveric study reported that tapering defects did not significantly alter stress.

Surgical skill and care are important in preventing fissuring or splitting during surgery (Christen and Jakob 1992, Friis et al. 1994, Berg 1996, Viola and Vianello 1999, DuMontier et al. 2001). Jackson et al. (1990) suggested a new technique of harvesting a cylindrical bone plug with a circular oscillating saw. This method was thought to be more reproducible; it created a bony trough with no sharp edges and also provided a better fit, thus permitting earlier mobilization. No fractures were seen in his initial series of 300 cases. A follow-up study by Shapiro et al. (1992) confirmed the success of this technique. Their results showed a 20% stronger interference fit, stronger 3-point bending configuration and 4-point bending configuration compared to trapezoidal and triangular defects. However, the results on patellar strength are of lim-

ited value, as the direction of stress applied in the study was perpendicular to the direction of physiological stress.

Accelerated rehabilitation programs after ACL reconstruction may place excessive forces on the weakened patella, predisposing it to indirect patella fractures—the risk of fracture being highest in the first 6–8 weeks (Brownstein and Bronner 1997). Daluga et al. (1990) advocated no weight bearing in this period of vulnerability. However, conditioning of the quadriceps and vastus medialis muscles is of prime importance in preventing maltracking of the patella, which might otherwise predispose it to stellate-type indirect fractures (Simonian et al. 1995). Immobility would also promote disuse osteopenia (Sievanen et al. 1994). Early attention should be focused on neuromuscular control, effusion control and motion and muscle-strengthening exercises (Brownstein and Bronner 1997). There is little justification for reducing goals or increasing restrictions in the postoperative period, as the risk of ankylosis is greater (Hughston 1985, Simonian et al. 1995, Benson and Barnett 1998).

Prognosis

Patellar fractures following ACL reconstruction require a long rehabilitation period. Several studies have shown that following successful rehabilitation of treated patellar fractures with no further complications, patients do not suffer from long-term consequences (Bonatus and Alexander 1991, Christen and Jakob 1992, Carangelo et al. 1995, Simonian et al. 1995, Berg 1996, Brownstein and Bronner 1997, Viola and Vianello 1999, Stein et al. 2002).

Conclusion

Indirect patella fracture following anterior cruciate ligament reconstruction is an uncommon complication of bone-patella tendon-bone autografts. It is associated with knee flexion; thus, an increased awareness of the mechanism of injury may assist in preventing such fractures.

Following graft harvest, the forces that act on the patella are altered. The methods that have been proposed to cancel these effects remain inconclusive. Bone grafting of the patella defect offers a theoretical advantage: normalization of the forces by restoring the integrity of the anterior patella wall. However, further study of the efficacy of

bone grafting must be recommended. Finally, post-operative mobilization should not be restricted, but rather encouraged in order to avoid the risk of ankylosis.

The authors thank Dr Farhard Azimi for his contribution to this paper.

No competing interests declared.

- Benson, E R, Barnett P R. A delayed transverse avulsion fracture of the superior pole of the patella after anterior cruciate ligament reconstruction. *Arthroscopy* 1998; 14 (1): 85-8.
- Berg E E. Management of patella fractures associated with central third bone-patella tendon-bone autograft ACL reconstructions. *Arthroscopy* 1996; 12 (6): 756-9.
- Bonatus T J, Alexander A H. Patellar fracture and avulsion of the patellar ligament complicating arthroscopic anterior cruciate ligament reconstruction. *Orthop Rev* 1991; 20 (9): 770-4.
- Brownstein B, Bronner S. Patella fractures associated with accelerated ACL rehabilitation in patients with autogenous patella tendon reconstructions. *J Orthop Sports Phys Ther* 1997; 26 (3): 168-72.
- Carangelo R J, Caputo A E, Langeland R H. Postoperative patellar fractures after autogenous patellar tendon harvesting for anterior cruciate ligament reconstruction. *Orthop Trans* 1995; 19: 24.
- Carpenter J E, Huston L J, Goldstein S A. Strength of the patella tendon after removal of a central graft for ACL reconstruction. *Orthop Trans* 1993-94; 17: 605-6.
- Carpenter J E, Kasman R, Matthews L S. Fractures of the patella. *Instr Course Lect* 1994; 43: 97-108.
- Christen B, Jakob R P. Fractures associated with patellar ligament grafts in cruciate ligament surgery. *J Bone Joint Surg (Br)* 1992; 74 (4): 617-9.
- D'Agata S D, Pearsall A W, Reider B, Draganich L F. An in vitro analysis of patellofemoral contact areas and pressures following procurement of the central one-third patellar tendon. *Am J Sports Med* 1993; 21 (2): 212-9.
- Daluga D, Johnson C, Bach B R, Jr. Primary bone grafting following graft procurement for anterior cruciate ligament insufficiency. *Arthroscopy* 1990; 6 (3): 205-8.
- DuMontier T A, Metcalf M H, Simonian P T, Larson R V. Patella fracture after anterior cruciate ligament reconstruction with the patellar tendon: a comparison between different shaped bone block excisions. *Am J Knee Surg* 2001; 14 (1): 9-15.
- Eilerman M, Thomas J, Marsalka D. The effect of harvesting the central one-third of the patellar tendon on patellofemoral contact pressure. *Am J Sports Med* 1992; 20 (6): 738-41.
- Ferrari J D, Bach B R, Jr. Bone graft procurement for patellar defect grafting in anterior cruciate ligament reconstruction. *Arthroscopy* 1998; 14 (5): 543-5.
- Friis E A, Cooke F W, McQueen D A, Henning C E. Effect of bone block removal and patellar prosthesis on stresses in the human patella. *Am J Sports Med* 1994; 22 (5): 696-701.
- Goldstein S A, Coale E, Weiss A P, Grossnickle M, Meller B, Matthews L S. Patellar surface strain. *J Orthop Res* 1986; 4 (3): 372-7.
- Huberti H H, Hayes W C. Patellofemoral contact pressures. The influence of q-angle and tendofemoral contact. *J Bone Joint Surg (Am)* 1984; 66 (5): 715-24.
- Hughston J C. Complications of anterior cruciate ligament surgery. *Orthop Clin North Am* 1985; 16 (2): 237-40.
- Jackson D W, Cohn B T, Morrison D S. A new technique for harvesting the patella tendon in patients undergoing anterior cruciate ligament reconstruction. *Orthopedics* 1990; 13 (2): 165-7.
- Johnson R J, Eriksson E, Haggmark T, Pope M H. Five- to ten-year follow-up evaluation after reconstruction of the anterior cruciate ligament. *Clin Orthop* 1984; (183): 122-40.
- Lengsfeld M, Ahlers J, Ritter G. Kinematics of the patellofemoral joint. Investigations on a computer model with reference to patellar fractures. *Arch Orthop Trauma Surg* 1990; 109 (5): 280-3.
- Malek M M, DeLuca J V, Verch D L, Kunke K L. Arthroscopically assisted ACL reconstruction using central third patellar tendon autograft with press fit femoral fixation. *Instr Course Lect* 1996; 45: 287-95.
- Martin R P, Galloway M T, Daigneault J P, Goehner K. Patellofemoral pain following ACL reconstruction: bone grafting the patella defect. *Orthop Trans* 1996; 20: 9.
- Matthews L S, Sonstegard D A, Henke J A. Load bearing characteristics of the patello-femoral joint. *Acta Orthop Scand* 1977; 48 (5): 511-6.
- McCarroll J R. Fracture of the patella during a golf swing following reconstruction of the anterior cruciate ligament. A case report. *Am J Sports Med* 1983; 11 (1): 26-7.
- McDaniel W J, Jr., Dameron T B, Jr. Untreated ruptures of the anterior cruciate ligament. A follow-up study. *J Bone Joint Surg (Am)* 1980; 62 (5): 696-705.
- Noyes F R, Butler D L, Grood E S, Zernicke R F, Hefzy M S. Biomechanical analysis of human ligament grafts used in knee-ligament repairs and reconstructions. *J Bone Joint Surg (Am)* 1984; 66 (3): 344-52.
- Roberts T S, Drez D, Parker W. Prevention of late patellar fracture in ACL deficient knees reconstructed with bone-patellar tendon-bone autografts. *Am J Knee Surg* 1989; 2 (2): 83-6.
- Sanders R. Patella fractures and extensor mechanism injuries. *Skeletal Trauma* 1992; 2: 1692-5.
- Satku K, Kumar V P, Ngoi S S. Anterior cruciate ligament injuries. To counsel or to operate? *J Bone Joint Surg (Br)* 1986; 68 (3): 458-61.

- Shapiro J D, Cohn B T, Jackson D W, Postak P D, Parker R D, Greenwald A S. The biomechanical effects of geometric configuration of bone-tendon-bone autografts in anterior cruciate ligament reconstruction. *Arthroscopy* 1992; 8 (4): 453-8.
- Sharkey N A, Donahue S W, Smith T S, Bay B K, Marpder R A. Patellar strain and patellofemoral contact after bone-patellar tendon-bone harvest for anterior cruciate ligament reconstruction. *Arch Phys Med Rehabil* 1997; 78 (3): 256-63.
- Sievanen H, Kannus P, Heinonen A, Oja P, Vuori I. Bone mineral density and muscle strength of lower extremities after long-term strength training, subsequent knee ligament injury and rehabilitation: a unique 2-year follow-up of a 26-year-old female student. *Bone* 1994; 15 (1): 85-90.
- Simonian P T, Mann F A, Mandt P R. Indirect forces and patella fracture after anterior cruciate ligament reconstruction with the patellar ligament. Case report. *Am J Knee Surg* 1995; 8 (2): 60-4; discussion 64-5.
- Steen H, Tseng K F, Goldstein S A, Carpenter J E. Harvest of patellar tendon (bone-tendon-bone) autograft for ACL reconstruction significantly alters surface strain in the human patella. *J Biomech Eng* 1999; 121 (2): 229-33.
- Stein D A, Hunt S A, Rosen J E, Sherman O H. The incidence and outcome of patella fractures after anterior cruciate ligament reconstruction. *Arthroscopy* 2002; 18 (6): 578-83.
- Viola R, Vianello R. Three cases of patella fracture in 1,320 anterior cruciate ligament reconstructions with bone-patellar tendon-bone autograft. *Arthroscopy* 1999; 15 (1): 93-7.