

## Case report

# Autologous chondrocyte implantation with bone grafting for osteochondral defect due to posttraumatic osteonecrosis of the hip—a case report

Pavel Akimau<sup>1</sup>, Abhijit Bhosale<sup>1</sup>, Paul E Harrison<sup>2</sup>, Sally Roberts<sup>3</sup>, Iain W McCall<sup>4</sup>, James B Richardson<sup>1</sup> and Brian A Ashton<sup>2</sup>

<sup>1</sup>Institute of Orthopaedics, <sup>2</sup>Leopold Muller Arthritis Research Centre, <sup>3</sup>Centre for Spinal Studies, Leopold Muller Arthritis Research Centre, <sup>4</sup>Department of Radiology, Robert Jones and Agnes Hunt Orthopaedic Hospital, Oswestry, Shropshire, UK, SY10 7AG  
Correspondence PA: pasha16sulta@mail.ru  
Submitted 05-05-22. Accepted 05-09-19

A 31-year-old man sustained a severe fracture dislocation of the left hip as a result of a road traffic accident in 2001. There was a subcapital fracture of the femoral head with complete separation of the head from the femoral neck, and posterior wall fracture of the acetabulum (Figure 1). The initial management was open reduction and internal fixation, and the immediate postoperative radiograph showed the screws to be in a satisfactory position within the femoral head.

After 1 year, the patient was walking with one crutch and the range of movement of the left hip was restricted due to severe pain. At this time, his hip score (HS) was 52 of a possible 100 (Harris

1969). Radiography demonstrated a united femoral fracture, but the fixation screws had penetrated the hip joint due to collapse of the osteonecrotic femoral head, and there was narrowing of the joint space (Figure 2). Taking the young age of the patient into account, we decided to proceed with autologous chondrocyte implantation (ACI). The first stage was performed 21 months after the original injury. During an arthroscopy of the ipsilateral knee, 240 mg of macroscopically normal full depth cartilage was harvested from the low load area of the medial trochlea. The tissue was transported to a dedicated clinical cell culture laboratory for isolation and expansion of the chondrocytes as previously

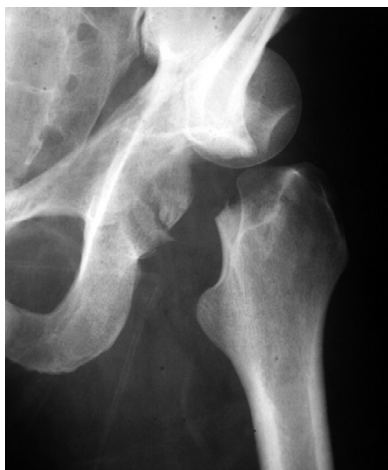

Figure 1. Anteroposterior plain radiograph showing the original severe fracture dislocation of the left hip prior to surgery. There is complete separation and displacement of the femoral head and femoral neck, with a fracture of the posterior wall of the acetabulum.

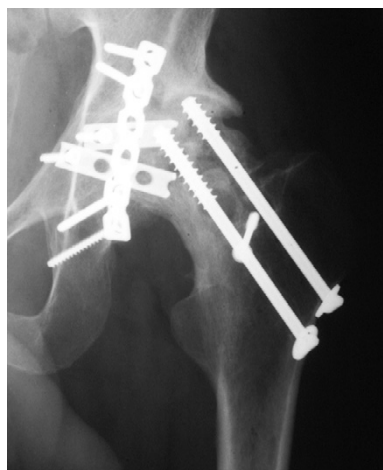


Figure 2. Anterolateral radiograph of the hip 10 months after the trauma, showing a united femoral neck fracture with metal penetration into the joint space. There is collapse of the lateral aspect of the femoral head with extensive sclerosis, indicating severe osteonecrosis.

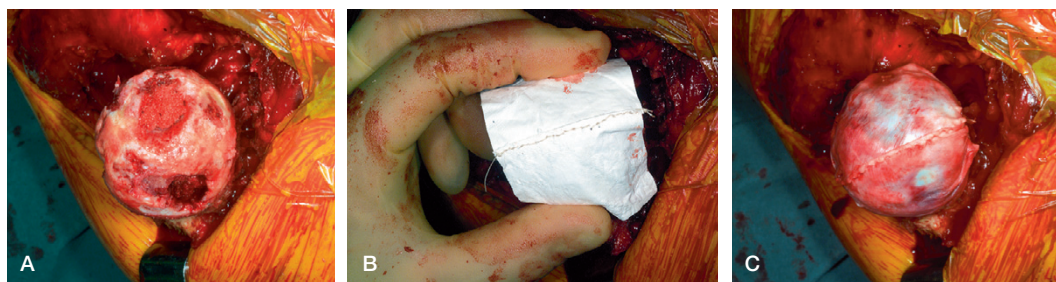

Figure 3. Intraoperative photographs showing: A. excessive chondrolysis of the femoral head prior to ACI; B. initial adjustment of two Chondro-Gide patches; and C. the final conformation of Chondro-Gide over the femoral head.

described (Harrison et al. 2000). 3 weeks later, the second stage was undertaken using a Stracathro approach for the hip (McLauchlan 1984). An anterior slice of the greater trochanter was removed with proximal medius and distal vastus lateral muscles in continuity. Care was taken to avoid the entry of the medial circumflex artery to the femur at the insertion of the superior gemellus muscle. The screws were removed from the femoral neck. The hip was dislocated anteriorly. The femoral head revealed flattening and irregularity, with complete loss of cartilage. The head was then debrided to healthy bleeding bone using a cibator (Figure 3 A). The defects of the femoral head were filled with bone graft taken from the osteotomy site. 2 manufactured collagen patches (Chondro-Gide patches (Geistlich Pharma AG, Switzerland) were sutured together with 2.0 Vicryl and placed over the femoral head (Figure 3 B). Bleeding was minimal by this time. A purse string of polydioxanone around the femoral neck was used to shape the patch in order to conform to the head (Figure 3 C). Tisseel (Baxter, Berkshire, UK) was used to seal the edges and 6 million chondrocytes were injected under the patch from 2 entry points. The hip was relocated and the wound was closed.

In the postoperative period skin traction of 2 kg was applied for 6 h, followed by continuous passive movements of the left hip for the next 48 h. Partial weight bearing was recommended for the next 8 weeks. 2 months after the surgery, the HS decreased to 45. The patient continued to experience severe pain in the hip on movement and mobilized with crutches. However, by 12 months after the operation there was a significant improvement in his condition. At that time, HS rose to 76. Active hip flexion was 90°, extension 5°, abduction and

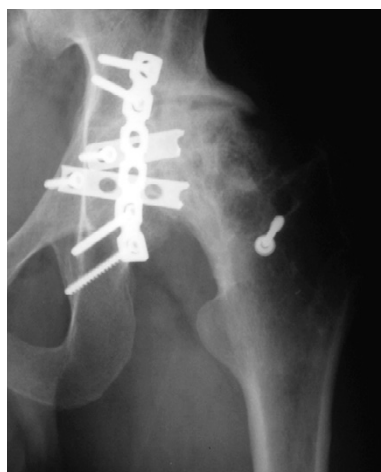

Figure 4. Anteroposterior plain radiograph at 12 months post-ACI showing residual metalwork in the acetabulum. Also, cysts and sclerotic areas of the femoral head can be seen clearly.

adduction 20°, and internal and external rotation 30°. Radiography performed at that time demonstrated cysts and sclerotic areas in the femoral head (Figure 4). MRI was performed prior to arthroscopy and demonstrated a thin layer of cartilage overlying an irregular subchondral bone (Figure 5). 15 months after surgery, an arthroscopy was attempted, but it proved impossible to gain access to the joint space due to excessive scar tissue formation from the previous injury. A full-depth biopsy from the ACI-treated site was obtained, using fluoroscopic guidance. Histology of the biopsy demonstrated cartilage of approximately 2 mm thickness, which was well-populated with viable cells and integrated with the underlying bone (Figure 6). Viewing under polarized light showed that it was predominantly fibrocartilage, but there were small areas of the matrix towards the bone which were

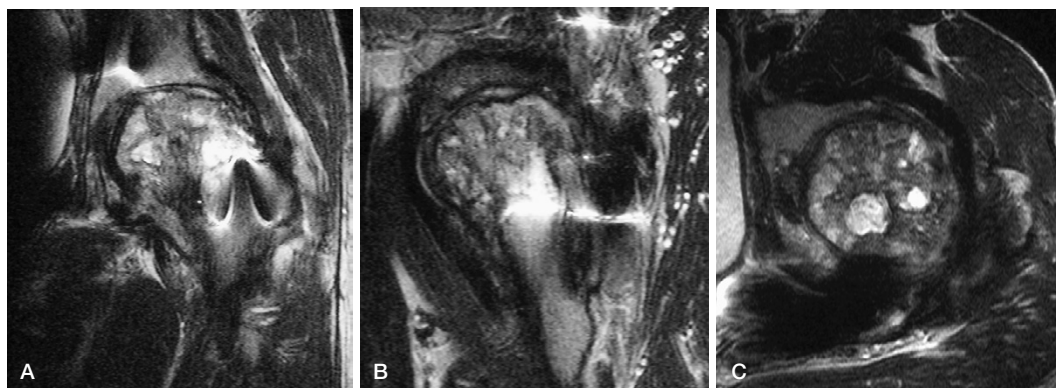


Figure 5. MRI at 12 months post-ACI demonstrates a variable thickness of cartilage overlying an irregular subchondral bone outline. The subchondral cysts and areas of sclerosis with loss of normal marrow signal are clearly visible. A. coronal view, T2-weighted TSE (TR 4000, TE 96, echo 7); B. sagittal view, T1-weighted SE (TR 570, TE 20); and C. axial view, T2-weighted TSE (TR 4000, TE 96, echo 7).

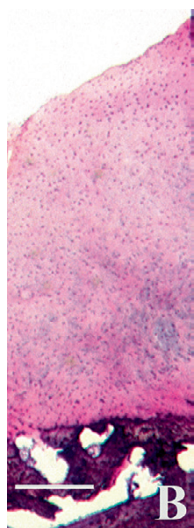


Figure 6. Photomicrograph showing cartilage tissue populated with viable chondrocytes, which is well integrated into the underlying bone (B). Hematoxylin and eosin. Bar represents 500  $\mu\text{m}$ .

amorphous and hyaline in appearance. The patient was most recently seen 16 months post-ACI. He was very pleased with the results and had returned to the full-time employment. He was not using any walking aids, had a slight limp and his HS remained at 76. The active range of motion of the left hip was the following: flexion 110°, extension 10°, abduction 35°, adduction 20°, internal rotation 30° and external rotation 20°. He was able to run on the spot and walk more than a mile, with mild pain which disappeared on resting. CT was per-

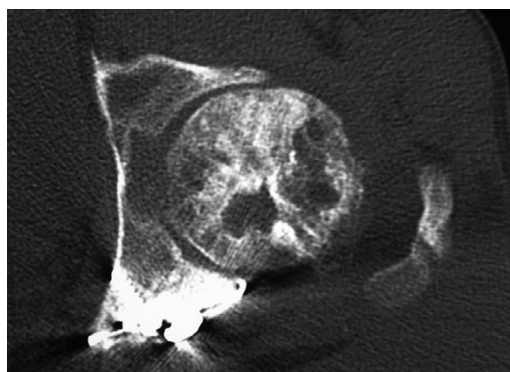


Figure 7. CT scan 18 months post-ACI treatment, showing sclerosis and cysts in the femoral head due to previous osteonecrosis. The joint space is reduced but present, and there is good congruity of the femoral head and acetabulum.

formed at 18 months post-ACI. It confirmed cystic sclerotic bony changes of previous osteonecrosis, but retention of the joint space (Figure 7).

## Discussion

ACI is a novel technique in the repair of cartilage defects (Brittberg et al. 1994). It has been shown to be successful in the treatment of full-thickness cartilage defects in the knee and ankle, especially in young and active patients (Petersen et al. 2000, 2003, Whittaker et al. 2005). However, its potential in the hip has not been addressed yet. The method we used is generally similar to employment of

recombinant human osteogenic protein-1 (rhOP-1) for bone defect repair (Wozney, 2002). This organic component is known to induce endochondral and direct bone formation. In the series of 121 patients reported by Friedlaender et al. (2001), intramedullary nailing combined either with rhOP-1 and type I collagen carrier led to complete clinical and radiological healing of tibial nonunions 9 months after the procedure. In our case, we were faced with a difficult problem—predominant extensive loss of cartilage and posttraumatic osteonecrosis. We considered ACI surgery of the hip with an artificial membrane (Chondro-Gide), and bone grafting might be a suitable treatment for him.

To our knowledge this is the first such report. The procedure is technically feasible and, as it addresses the loss of cartilage, could be a beneficial option for the treatment of chondral defects of the femoral head. Our early findings suggested cartilage generation, with an encouraging histological appearance. Despite radiographic osteonecrotic changes in the femoral head more than 1 year after the intervention, the patient demonstrated significant objective clinical improvement and was satisfied with the results. We understand that the validity of the data from a single case is limited, and long-term results are required. We will report the outcome after 3 years. Even so, we believe that at least with regard to medium-term outcomes, ACI is a possible method for the treatment of massive cartilage loss in young adults after severe fracture dislocation of the hip. Moreover, even if ACI fails, we do not see it as a disadvantage—as it does not preclude the use of other hip reconstructive surgery at a later stage.

#### Author contributions

PA collected results and wrote the article. AB performed follow-up assessment. PEH harvested chondrocytes for ACI. SR performed histological assessment. IWM performed radiological assessment. JBR performed all operations, head of the ACI project. BAA leading researcher, co-founder of ACI project.

- Brittberg M, Lindahl A, Nilsson A, Ohlsson C, Isaksson O, Peterson L. Treatment of deep cartilage defects in the knee with autologous chondrocyte transplantation. *N Engl J Med* 1994; 331: 889-95.
- Friedlaender G E, Clayton R P, Cole J D, Cook S D, Cierny G, Muschler G F, Zych G A, Calhoun J H, LaForte A J, Yin S. Osteogenic protein-1 (bone morphogenetic protein-7) in the treatment of tibial nonunions. *J Bone Joint Surg (Am)* 2001; 83: 151-8.
- Harris W H. Traumatic arthritis of the hip after dislocation and acetabular fractures: Treatment by mold arthroplasty. An end-result study using a new method of result evaluation. *J Bone Joint Surg (Am)* 1969; 51: 735-55.
- Harrison P E, Ashton K, Johnson W E B, Turner S L, Richardson J B, Ashton B A. The in vitro growth of human chondrocytes. *Cell Tissue Bank* 2000; 1: 255-60.
- McLauchlan J. The stracathro approach to the hip. *J Bone Joint Surg (Br)* 1984; 66: 30-1.
- Petersen L, Minas T, Brittberg M, Nilsson A, Sjogren-Jansson E, Lindahl A. Two- to 9-Year outcome after autologous chondrocyte transplantation of the knee. *Clin Orthop* 2000; (374): 212-34.
- Petersen L, Brittberg M, Lindahl A. Autologous chondrocyte transplantation of the ankle. *Foot Ankle Clin* 2003; 8: 291-303.
- Whittaker P, Smith G, Makwana N, Roberts S, Harrison E, Laing P, Richardson B. Early results of autologous chondrocyte implantation in the talus. *J Bone Joint Surg (Br)* 2005; 87: 179-83.
- Wozney J M. Overview of bone morphogenetic proteins. *Spine* 2002; 27: 2-8.