

Mueller reinforcement rings in acetabular revision

Outcome in 164 hips followed for 2–17 years

Ulf J Schlegel¹, Rudi G Bitsch¹, Maria Pritsch², Martin Clauss¹, Hans Mau¹ and Steffen J Breusch³

¹Department of Orthopaedics, University of Heidelberg, ²Institute for Medical Biometry and Informatics, University of Heidelberg, Germany, ³Department of Orthopaedic Surgery, University of Edinburgh, Scotland

Correspondence SJB: steffen.breusch@ukonline.co.uk

Submitted 05-01-20. Accepted 05-05-11

Background In revision hip arthroplasty, cages are commonly used for acetabular reconstruction in cases with loss of bone stock. It is important to follow this patient group closely, in order to better understand failure mechanisms and the chance of long-term success.

Patients and methods We followed our first 164 acetabular revisions with the Mueller reinforcement ring (ARR) in 164 patients, with an average follow-up period of 6 (2–17) years. Mean age at surgery was 69 (29–92) years. 39 patients died (39 hips) during follow-up, but only 3 patients (3 hips) were lost to follow-up.

Results In the observation period, 13 of the hips had to undergo acetabular re-revision for aseptic and septic loosening. Overall survival at 5 years was 95% (CI: 89%–98%) and 90% (CI: 76%–95%) at 8 years using acetabular re-revision or implant removal for all reasons as endpoint. In addition, mechanical and clinical failure was seen in 2 cases. The mean Harris hip score was 70 points, whilst the Merle d'Aubigné score averaged 7 points. Radiolucent lines according to DeLee and Charnley were observed twice in zone I, 6 times in zone II and 14 times in zone III.

Interpretation We found that mid- to long-term survival of the ARR is acceptable. However, failure of the implant due to allograft collapse/resorption or deep infection, and also poor clinical outcome, remain major concerns in acetabular revision arthroplasty. This should be recognized when advising patients.

Acetabular revision following total hip arthroplasty (THA) can be a challenging and complex problem, especially in the presence of bone loss (Dennis 2003). Acetabular reconstruction aims to restore the former hip center and anatomy in a functional sense. Bone loss can be addressed with the use of mega-implants (Koster et al. 1998, Chen et al. 2000, Christie 2002, Gross et al. 2002, Gotze et al. 2003, Popovic et al. 2003) or more commonly (in Europe) with the use of bone graft. Various designs of acetabular reinforcement rings combined with different methods of bone grafting have been described. We have reviewed our first 164 acetabular revisions with the Mueller reinforcement ring (ARR) in 164 patients with an average follow-up period of 6 (2–17) years. The results are compared with other published series.

Patients and methods

Reinforcement ring

The implant used in all cases was the original acetabular reinforcement ring according to M. E. Mueller (Centerpulse Orthopedics, now Zimmer Inc., Warsaw, IN), which has been in clinical use since 1976 (Figure 1). The long- and mid-term reports showed good clinical results in larger series (Gurtner et al. 1993, Pascarel et al. 1993). This implant is recommended for reconstruction of mainly cavity defects (Starker et al. 1998), is available in 12



Figure 1. The original acetabular reinforcement ring according to M. E. Mueller (Centerpulse Orthopedics, now Zimmer Inc., Warsaw, IN).

sizes ranging from 36–58 mm and is made of pure CP titanium (ISO 5832-2). Stable fixation to host bone is achieved by 6.5-mm fully threaded cancellous screws. The corresponding polyethylene cup is fixed with cement within the ring, where it can be freely positioned in appropriate anteversion and inclination. In our series, the size of the implanted ARR averaged 51 (44–58) mm.

Grafts

Bone grafting for augmenting acetabular bone deficiency was mainly performed with femoral head allografts, which had been retrieved at primary THA and cryoconserved at -70°C . For the reconstructions we used morselized bone, bulk grafts or a combination of both. Morselized grafting was performed with washed and milled allogeneous bone. Then the ring was hammered into the graft, using the ring for impaction of the graft, before screw fixation. When required to reconstruct large defects, bulk allografts were fixed with K-wires to the host bone and then reamed and shaped to accommodate the ring. In cases with combined bulk and morselized graft, bone chips were added to fill remaining spaces, which were not covered by the structural allograft. We added autogenous cancellous iliac crest grafts in only 8 cases. In total, there were 49 morselized and 75 bulk allografts, combined grafts in 26 cases and no grafting was necessary in 17 hips (Table 1).

Table 1. Grafts

Type of graft	Hips, n (%)
Morselized	49 (30)
Bulk	75 (46)
Combined	26 (16)
No bone graft	14 (9)

Table 2. Revision diagnosis

Revision diagnosis	Hips, n (%)
Loosening	143 (87)
Infection	13 (8)
Trauma	6 (4)
Recurrent dislocation	2 (1)

Patients and follow-up

Our study design was retrospective but consecutive, and included 164 patients (164 hips; 121 women), who had undergone acetabular revision between 1984 and 1999, with an average follow-up period of 6 (2–17) years. In cases with bilateral revision, only the first operated hip was included. Mechanical failure was the cause of revision in 143 cases, septic loosening in 13 cases and 6 were revised for traumatic reasons, whereas the remaining 2 had recurrent dislocation (Table 2). 25 patients had undergone previous acetabular revision prior to the index operation: in 8 cases an isolated acetabular revision had been performed, and in 5 cases an acetabular reinforcement device had also been used. Furthermore, in 12 cases a combined revision of stem and cup had previously been carried out. In 13 cases an infection was present and was the cause of loosening. Average age at the intervention was 69 (29–92) years; body mass index averaged 26 (16–40). 39 patients died during follow-up and 3 patients were lost to follow-up (Figure 2). In all patients who had died during the follow-up period except 2, the device had not been removed at the time of death; for the latter 2, the information about the implant's fate in terms of fixation was not available. Clinical and radiographic follow-up data could be retrieved for 109 patients. This information was collected by the first author in 97 cases, and 12 patients were examined radiographically and clinically by orthopedic surgeons elsewhere,

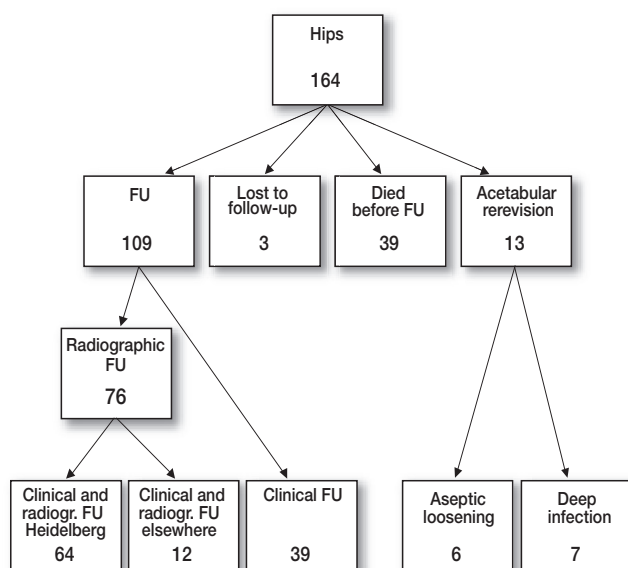


Figure 2. Patient data.

who sent us radiographs and clinical data. For 33 patients, the only clinical follow-up information obtained was by patient questionnaire. For evaluation of patients who presented for examination, standard AP and lateral radiographs were taken; in addition, a questionnaire and clinical examination were used to calculate Harris hip score and Merle d'Aubigné score.

Surgeons

The operations were performed by 29 orthopedic surgeons. Almost half (49%) of the revisions (80 operations) were performed by 3 surgeons, who each perform a minimum of 30 acetabular revisions with reinforcement rings per year.

Clinical assessment

Clinical evaluation included documentation of range of motion (ROM), Trendelenburg's sign, leg length, limp, walking distance and Charnley class. The Visual Analogue scale was used for pain assessment; activity in daily living was recorded in 4 grades (Devane et al. 1997) and patient categories were documented according to Charnley. In addition, both Harris hip score (Harris 1969) and Merle d'Aubigné score (D'Aubigné 1954) were calculated.

Radiographic evaluation

Acetabular bone stock deficiency was graded according to the AAOS (D'Antonio et al. 1989). Defect classification was done on preoperative standard AP and lateral radiographs by two senior orthopedic surgeons. Average radiographic follow-up was 5 (2–16) years. All radiographs (AP and lateral) were evaluated for radiolucent lines in the 3 regions according to DeLee and Charnley (1976), for heterotopic ossification (Brooker et al. 1973), for ring inclination and for integrity of graft and screws. Radiographic failure of the device was defined as a complete radiolucent line surrounding the ring, migration of the implant more than 5 mm, and breakage of at least 1 screw (Bohm and Banzhaf 1999).

Statistics

Continuous data are described by median and range. Two Kaplan-Meier analyses were carried out: one considering revision or removal for any reason as an endpoint, and the second using aseptic revision or removal as endpoint. The 95% confidence intervals (CIs) for 5- and 8-year survival were calculated with the upper limit according to the proposition of Rothman, whereas the lower confidence interval was given according to Simon and Lee (Marubini 1987) as recommended by Dorey and Korn (1987). All analyses were performed using SAS version 8.2 (SAS Institute Inc., Cary, NC).

Results

Survival

The overall survival rate was 95% (CI: 89%–98%) at 5 years and 90% (CI: 76%–95%) at 8 years. For aseptic loosening, the survival was 98% (CI: 93%–99%) at 5 years and 95% (CI: 84%–99%) at 8 years (Figure 3).

Clinical data

The median Harris hip score of the patients at follow-up was 70 (20–100), whereas Merle d'Aubigné and Postel scores reached a median of

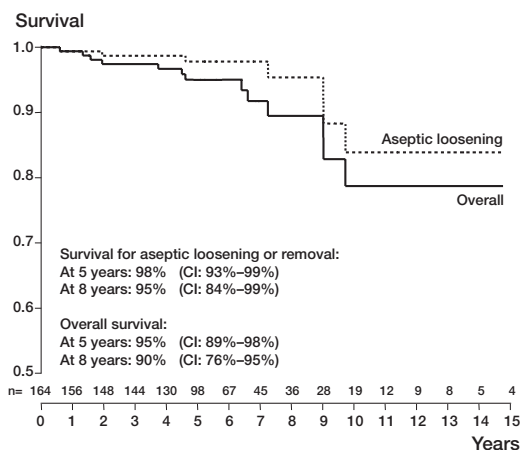


Figure 3. Kaplan-Meier chart of prosthetic survival.

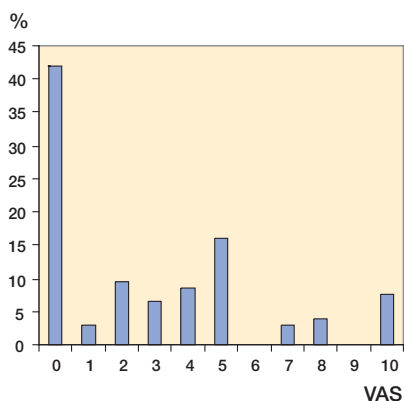


Figure 4. Postoperative pain levels (VAS).

7 (0–12) points. In the Merle d'Aubigné score, 15 patients (22%) showed good to very good results, while 37 patients (55%) had a poor clinical outcome. In the Harris hip score, 52% of the patients reached a score under 70 points (which is considered a poor result according to the original article). Regarding the Charnley class, half of the patients were grouped as class A; however, a noteworthy number were classified as C (Table 3). The ADL assessment showed that most patients were limited to doing office work or light physical work (Table 4). VAS for the affected side revealed that almost half of the patients never experienced any pain, as shown in Figure 4. A considerable or moderate limp was present in 33 cases (41%), and in 17 patients (21%) a mild limp was present. Trendelenburg's sign was strongly positive in 19 patients (23%), and weakly positive in 10 other cases (12%). Leg

Table 3. Charnley class

Charnley Class	Hips, n (%)
Class A	40 (49)
Class B	17 (21)
Class C	24 (29)

Table 4. ADL

Activity	Patients, n (%)
Heavy physical work	8 (13)
Light physical work	20 (32)
Office work	29 (46)
Work sitting	6 (10)

Table 5. Leg length

Leg length discrepancy	Hips, n (%)
None	43 (52)
5–15 mm	20 (24)
15–30 mm	13 (16)
> 30 mm	6 (7)

Table 6. Heterotopic ossification (Brooker)

Heterotopic ossification	Hips, n (%)
Group 0	41 (55)
Group 1	16 (21)
Group 2	3 (4)
Group 3	13 (17)
Group 4	2 (3)

length discrepancies > 30 mm were rarely present; no discrepancy could be detected in more than half of the cases studied (Table 5).

Radiographic findings

At radiographic follow-up, no heterotopic ossifications according to Brooker were found in more than half of the radiographs examined, however a noteworthy number of grade 3 ossifications was identified (Table 6). Radiolucent lines according to DeLee and Charnley were found mainly in zone III (Table 7). Radiographic and mechanical failure (which had not yet been re-revised) was detected in only 2 patients. Inclination was 40–45°

Table 7. Radiolucent lines (DeLee/Charnley)

Radiolucent lines	Hips, n (%)
Zone I	2 (3)
Zone II	6 (8)
Zone III	14 (19)

Table 8. Percentage of interfaces with radiolucent lines

Percentage	Cases, n
0%	53
0–50%	22
51–99%	0
100%	13

Table 9. Acetabular defects

AAOS classification	Hips, n (%)
Type 1 (segmental)	11 (9)
Type 2 (cavitary)	33 (20)
Type 3 (combined)	92 (56)
Type 4 (pelvic discontinuity)	8 (5)
Type 5 (arthrodesis)	0 (0)
No deficiency	20 (12)

in 46 (61%) of the cases, whereas in all other hips the reinforcement ring was implanted out of that range: > 45° in 15 (20%), and < 40° in 14 (19%). Of 6 hips that were re-revised for aseptic loosening, we found screw breakage and migration in all cases. Additional graft collapse was present in 3 of the 6 cases revised for aseptic reasons. Among the 7 hips that were re-revised for deep infection, we found graft collapse in 2 cases—in which additional screw breakage and migration of the implant was visible. In one other case, only screw breakage without further dislocation could be seen. Isolated migration without graft collapse or screw breakage was present in another hip with deep infection. In the remaining 3 septic revisions, none of those complications could be identified. Regarding defect classification according to the AAOS, in the 13 cases of re-revision there were 2 cavitary and 9 combined defects before primary revision, whereas another 2 defects were classified as pelvic discontinuities (Table 9).

Discussion

Reconstruction of acetabular defects remains a challenge in revision THA. Especially large deficiencies with combined cavitary and segmental bone loss may pose complex problems when bridging and filling of the defect is required. The acetabular reinforcement ring (ARR) was designed to address these problems and to provide stable fixation for the polyethylene liner. However, when substantial loss of structural bone in the cranial part of the acetabulum is present, the ARR will lead to a more cranial reconstruction and hence a high hip center (Starker et al. 1998). As the ring lacks design features for distal support, cases with severe deficiencies may lead to a horizontal positioning of the implant—and thus to implant loosening. Segmental integrity of the acetabulum should always be ensured before using this device. Former reports of large series have described widely different survival rates of this type of implant. Gurtner et al. (1993) presented a cumulative survival rate of 87% when following 150 of these implants over a period of 7 years, whereas Pascarel et al. (1993) followed 141 ARR over 5 years and found an overall survival of 99%. In the literature overview by Starker et al. (1998) of 11 published articles (see Table 10), 11% of the ARR failed clinically and radiographically after 6 years, whereas an additional 8% had been revised in the same time period (Schatzker et al. 1984, Haentjens et al. 1986, Korovessis et al. 1992, Gurtner et al. 1993, Dihlmann et al. 1994, Panski and Tauber 1997, Stockl et al. 1997).

We achieved a high follow-up rate in our series, as only 3 patients/hips (2%) were lost to follow-up. According to Britton et al. (1995), patients lost to follow-up have worse results than patients in regular assessment, whereas patients who die during the period of follow-up are similar to the surviving population. With the number of patients lost being lower than the number of failures, the data presented in this study can be regarded as being reliable according to Murray et al. (1997). The main criticism and weakness of our study is the lack of preoperative clinical scores. There are also other limiting factors: several patients already underwent multiple acetabular revisions prior to the index revision followed up in this series, which is another factor possibly contributing to poor clinical

Table 10. Literature overview (Starker et al. 1998)

Author	Mueller rings	Patient age (years)	Follow-up (years)	Loosening	Revision septic	Revision aseptic
Dihlmann 1994	42	71	2.5	0	0	0
Gurtner 1993	150	64	7	15	10	9
Haentjens 1986	14	68	3.3	1	1	0
Korovessis 1992	30	61	2.5	0	0	0
Pascarel 1993	141	63	8	9	2	0
Rosson 1992	46	63	5	16	5	0
Schatzker 1984	20	X	2.4	1	1	0
Stöckl 1997	47	68	6.4	2	2	2
Panski 1997	14	61	3.3	4	2	0
Starker 1998	41	X	6.6	2	2	0
Our data	164	69	6	2	7	6

cal outcome. With regard to pain (VAS), 42% of the patients did not experience any pain in the revised hip. This finding is apparently not sufficiently represented in the currently used clinical scores.

The clinical results with poor hip scores in our study are of concern, and are definitely worse than previously reported for this reinforcement device (Haentjens et al. 1986, Gurtner et al. 1993, Pascarel et al. 1993, Korovessis et al. 1999). Gurtner et al. (1993) found 53% good to excellent results in the relative Merle d'Aubigné score, whereas we found only 22% of the patients in that range (absolute score). Altogether, more than half of the patients in our series showed a poor clinical outcome in the Merle d'Aubigné score and the Harris hip score. A possible factor contributing to the poor results could be the high proportion of patients with additional systemic disease or concomitant pain in other joints, graded as Charnley class C. All clinical data in our study, except for the ROM, was retrieved independently—as the patients had filled in a questionnaire. The scoring of results in this setting may be lower than those obtained with the assistance of a physician (as an unpublished pilot study in our institution has suggested). It is well known that with ageing, a “natural” deterioration in clinical scores occurs. It would therefore be unjustified to attribute the poor clinical results to the type of implant under investigation. Although the value of our clinical data is limited by the lack of preoperative scores, the results may still provide some information of value regarding the outcome that can be expected in such a patient group.

Radiolucent lines in the implant-bone interface according to the classification by DeLee and Charnley (1976) were present in 22 cases, which is worrisome, but matches the experiences of other authors (Rosson and Schatzker 1992, Gurtner et al. 1993). It has to be contemplated that an accurate assessment and interpretation of those radiographic findings is difficult, especially when additional bone grafting has been done. However, although important to record, these lines have to be interpreted with care, as the maturation process of the graft may take up to 7 years (Gordon et al. 1985, Shih et al. 1994) and radiolucencies might be present during the entire period.

Classification of acetabular bone stock deficiency is important, to allow comparison of results. There is serious doubt, however, that the current classification systems for loss of bone stock are reliable, as inter- and intraobserver agreement is obviously poor (Campbell et al. 2001). In our patients with mainly large combined defects and a small number of pelvic discontinuities the description of defects intraoperatively was poor. Accurate intraoperative defect description and classification is certainly desirable, but this is difficult to implement in centers with many surgeons.

Despite all the limitations of our study, the outcome data represent a multisurgeon scenario, and acceptable long-term survival rates were obtained with Müller acetabular reinforcement rings and allografts in acetabular revision—even in the management of large defects, to which flanged reinforcement rings are probably more suited. Poor clinical outcome, infection and graft collapse with

consecutive failure remain major concerns in acetabular revision arthroplasty. This should be considered when advising patients preoperatively.

Author contributions

UJS collected the clinical and radiographic data with support from RGB and MC. HM and SJB did most of the operations, made the radiographic evaluations and helped in preparing the manuscript. MP did the statistical analysis. USJ and SJB prepared the manuscript.

No competing interests declared.

- Bohm P, Banzhaf S. Acetabular revision with allograft bone. 103 revisions with 3 reconstruction alternatives, followed for 0.3-13 years. *Acta Orthop Scand* 1999; 70: 240-9.
- Britton A, Murray D, Bulstrode C, McPherson K, Denham R. Loss to follow-up: does it matter? *Lancet* 1995; 345: 1511-2.
- Brooker A F, Bowerman J W, Robinson R A, Riley L H, Jr. Ectopic ossification following total hip replacement. Incidence and a method of classification. *J Bone Joint Surg (Am)* 1973; 55: 1629-32.
- Campbell D G, Garbuz D S, Masri B A, Duncan C P. Reliability of acetabular bone defect classification systems in revision total hip arthroplasty. *J Arthroplasty* 2001; 16: 83-6.
- Chen W M, Engh C A, Jr, Hopper R H, Jr, McAuley J P, Engh C A. Acetabular revision with use of a bilobed component inserted without cement in patients who have acetabular bone-stock deficiency. *J Bone Joint Surg (Am)* 2000; 82: 197-206.
- Christie M J. Beyond cementless hemispherical sockets. *Am J Orthop* 2002; 31: 208-11.
- D'Antonio J A, Capello W N, Borden L S, Bargar W L, Bierbaum B F, Boettcher W G, Steinberg M E, Stulberg S D, Wedge J H. Classification and management of acetabular abnormalities in total hip arthroplasty. *Clin Orthop* 1989; (243): 126-37.
- D'Aubigné M. Functional results of hip arthroplasty with acrylic prosthesis. *J Bone Joint Surg (Am)* 1954; 36: 451-75.
- DeLee J G, Charnley J. Radiological demarcation of cemented sockets in total hip replacement. *Clin Orthop* 1976; (121): 20-32.
- Dennis D A. Management of massive acetabular defects in revision total hip arthroplasty. *J Arthroplasty* 2003; 18: 121-5.
- Devane P A, Horne J G, Martin K, Coldham G, Krause B. Three-dimensional polyethylene wear of a press-fit titanium prosthesis. Factors influencing generation of polyethylene debris. *J Arthroplasty* 1997; 12: 256-66.
- Dihlmann S W, Ochsner P E, Pfister A, Mayrhofer P. Analysis of migration of screwed acetabular components following revision arthroplasty of the hip joint. Results of single-image roentgen analysis. *Z Orthop Ihre Grenzgeb* 1994; 132: 286-94.
- Dorey F J, Korn E L. Effective sample sizes for confidence intervals for survival probabilities. *Stat Med* 1987; 6: 679-87.
- Gordon S L, Binkert B L, Rashkoff E S, Britt A R, Esser P D, Stinchfield F E. Assessment of bone grafts used for acetabular augmentation in total hip arthroplasty. A study using roentgenograms and bone scintigraphy. *Clin Orthop* 1985; (201): 18-25.
- Gotze C, Sippel C, Wendt G, Steinbeck J. Limits in cementless hip revision total hip arthroplasty. Midterm experience with an oblong revision cup. *Z Orthop Ihre Grenzgeb* 2003; 141: 182-9.
- Gross A E, Blackley H, Wong P, Saleh K, Woodgate I. The role of allografts in revision arthroplasty of the hip. *Instr Course Lect* 2002; 51: 103-13.
- Gurtner P, Aebi M, Ganz R. The acetabular roof cup in revision arthroplasty of the hip. *Z Orthop Ihre Grenzgeb* 1993; 131: 594-600.
- Haentjens P, Handelberg F, Casteleyn P P, Opdecam P. The Muller acetabular support ring. A preliminary review of indications and clinical results. *Int Orthop* 1986; 10: 223-30.
- Harris W H. Traumatic arthritis of the hip after dislocation and acetabular fractures: treatment by mold arthroplasty. An end-result study using a new method of result evaluation. *J Bone Joint Surg (Am)* 1969; 51: 737-55.
- Korovessis P, Spastris P, Sdougos G, Salonikides P, Christodoulou G, Katsoudas G. Acetabular roof reinforcement rings. *Clin Orthop* 1992; (283): 149-55.
- Korovessis P, Stamatakis M, Baikousis A, Katonis P, Petsinis G. Mueller roof reinforcement rings. Medium-term results. *Clin Orthop* 1999; (362): 125-37.
- Koster G, Willert H G, Kohler H P, Dopkens K. An oblong revision cup for large acetabular defects: design rationale and two- to seven-year follow-up. *J Arthroplasty* 1998; 13: 559-69.
- Marubini E V M. Analysing survival data from clinical trial and observational studies. Wiley, Chichester 1987.
- Murray D W, Britton A R, Bulstrode C J. Loss to follow-up matters. *J Bone Joint Surg (Br)* 1997; 79: 254-7.
- Panski A, Tauber C. Acetabular supporting ring in total hip replacement. *Arch Orthop Trauma Surg* 1997; 116: 233-5.
- Pascarel X, Liquois F, Chauveaux D, Le Rebeller A, Honton J L. The use of Muller acetabular rings in revision surgery of total hip prosthesis. Apropos of 141 cases with a minimal 5-year follow-up. *Rev Chir Orthop Reparatrice Appar Mot* 1993; 79: 357-64.
- Popovic Z, Pokimica L, Starcevic S, Rajovic J. Early results in the use of the oblong S-ROM uncemented acetabular component. *Vojnosanit Pregl* 2003; 60: 279-83.
- Rosson J, Schatzker J. The use of reinforcement rings to reconstruct deficient acetabula. *J Bone Joint Surg (Br)* 1992; 74: 716-20.

- Schatzker J, Glynn M K, Ritter D. A preliminary review of the Muller acetabular and Burch-Schneider antiprotrusion support rings. *Arch Orthop Trauma Surg* 1984; 103: 5-12.
- Shih C H, Chen C H, Tsai M F, Tzen K Y. Incorporation of allograft for acetabular reconstruction. Single photon emission CT in 21 hip arthroplasties followed for 2.5-5 years. *Acta Orthop Scand* 1994; 65: 589-94.
- Starker M, Kandziora F, Jager A, Kerschbaumer F. Acetabular reconstruction using acetabular reinforcement rings. *Orthopade* 1998; 27: 366-74.
- Stockl B, Beerkotte J, Krismer M, Fischer M, Bauer R. Results of the Muller acetabular reinforcement ring in revision arthroplasty. *Arch Orthop Trauma Surg* 1997; 116: 55-9.