

Comparison of the uncemented Cone and the cemented Bimetric hip prosthesis in young patients with osteoarthritis

An RSA, clinical and radiographic study

Håkan Ström¹, Kurt Kolstad¹, Hans Mallmin¹, Bo Sahlstedt² and Jan Milbrink¹

Departments of ¹Orthopedics and ²Radiology, University of Uppsala, Uppsala, Sweden
Correspondence HS: hakan.strom@akademiska.se
Submitted 04-11-15. Accepted 05-05-19

Background There is no consensus as to whether uncemented or cemented femoral stems should be used in younger patients. We compared the uncemented Cone stem to the cemented Bimetric stem in young patients with osteoarthritis.

Patients and methods We randomized 45 relatively young patients (< 65 years old, mean age 54 years) with osteoarthritis to either an uncemented Cone stem or a cemented Bimetric stem. All patients were followed for 2 years. Outcome was assessed by the Merle d'Aubigné score, conventional radiography and repeated radiostereometric analysis (RSA). We also followed 81 Cone stems for 8 (7–12) years with revision as endpoint.

Results The clinical outcome was excellent. No patient had postoperative thigh pain. The migration was small. The Bimetric stem was stable during the whole observation period, while the Cone stem subsided and rotated to retroversion during the first 3 months postoperatively, and then remained stable. In the follow-up study of 81 Cone stems, 1 stem was revised.

Interpretation We conclude that both the cemented Bimetric stem and the uncemented Cone stem are stable and give excellent clinical results after 2 years in relatively young patients with osteoarthritis. Although designed for CDH hips, the Cone stem appears to be suitable also for patients with osteoarthritis.

(Wroblewski 1993). Total hip arthroplasty with a cemented Charnley type of prosthesis provides more than 85% excellent results in long-term follow-up (Wroblewski and Siney 1993). However, some reports have indicated that the results are less favorable in younger patients (Hozack et al. 1993, Ballard et al. 1995, Neumann et al. 1996, Dowdy et al. 1997). Sylvan et al. (2001) found that a group of patients with mechanical failure after cemented arthroplasty had a lower average age than those in a success group with the same implants. In the hope of better outcome, uncemented devices are often chosen for young patients. Good results using uncemented stems have been reported; Önsten et al. (1996) reported on 30 Omnifit hydroxyapatite-coated stems that showed little migration in the first 2 years, as measured by radiostereometric analysis (RSA). Söballe et al. (1993) found that a hydroxyapatite stem (Bimetric) was stable for the first year postoperatively, while the same stem with plasma-sprayed titanium alloy coating was less stable during the same follow-up time. On the other hand, Kärrholm and Snorrasson (1993) reported that of 18 ribbed uncoated stems, 13 had subsided according to RSA at the 2-year follow-up.

In the early 1990s a cemented titanium stem, Bimetric, was used as a first-hand choice in younger patients (i.e. < 65 years of age) in our department. However, recent results have made us aware of problems with cemented stems in younger patients (Hozack et al. 1993). Thus, an uncemented stem,

Whether uncemented or cemented devices are best in hip arthroplasty in young patients is contro-

Table 1. Patient data

	Randomized study		Clinical follow-up Cone
	Cone	Bimetric	
n	22	23	83
Female/Male	17/5	13/10	55/28
Age			
mean	55	53	49
median	55	55	50
range	45–65	41–64	19–65
Primary/secondary osteoarthritis	18/5	20/3	37/46
CDH Perthes	0	0	20
Follow-up time (years)			
mean	2	2	8.4
range			6.7–12.2

the Cone, was introduced in our clinic. We had no solid evidence, however, of the best choice for this patient group.

Early migration of cemented hip stems detected by RSA increases the risk of later revisions (Kärrholm et al. 1994a). Thus, the RSA technique seems to be suitable as the first step in the clinical evaluation of a prosthesis device.

We compared the early migration pattern using RSA and the radiographic and clinical outcome of the Cone and the Bimetric stems in younger patients with osteoarthritis. In addition, we hoped to determine whether the uncemented Cone stem is a safe option in young patients with osteoarthritis. Thus, we also followed a group of patients who had been operated with the Cone stem in order to study the mid-term revision rate of this stem.

Patients and methods

Between November 1996 and June 1998, we randomized 45 young patients with osteoarthritis to either an uncemented Cone ($n = 22$) or a cemented Bimetric femur hip stem ($n = 23$) (Table 1). The inclusion criteria were age under 65, unilateral osteoarthritis, and a shape of femur suitable for the Cone stem. Patients weighing over 100 kg or with any musculoskeletal disease—except osteoarthritis—were excluded. Wagner and Wagner (1995) pointed out that a trumpet-formed femur is not suitable for the Cone stem since this shape does not provide enough cortical bone contact distally.

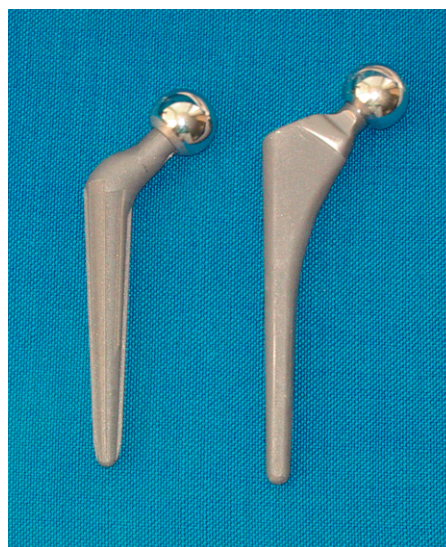

Figure 1. The Cone and Bimetric stem.

According to the guidelines of the manufacturer, approximately at least two-thirds of the distal stem should have cortical bone contact in order to secure stability. Thus, before inclusion and randomization we arbitrarily required at least 6 cm of distal bone contact, measured by templates on regular AP radiographs. Randomization was performed with a closed envelope technique. No stratification was done. The patients were followed for 2 years with clinical examination, radiographic examination and RSA. In addition, to determine stem survival we also followed 82 patients (83 THA) under the age of 65 who were operated with the Cone stem, using revision as endpoint. The mean follow-up time was 8 (7–12) years.

The implants

The Cone stem (Figure 1) is a grid blasted titanium-aluminum-nobelium alloy with a conical shape. The conus angle is 5° and it has 8 longitudinal ribs of varying height (1–2 mm) to provide rotational stability. The CCD angle is 135° and the length is 15 cm. At operation, the femur is reamed conically according to the contour of the implant. Primary stability is obtained when the longitudinal ribs are impacted into the cortical bone.

The Bimetric stem is a collarless gridblasted titanium alloy stem (Figure 1). The length of the stem increases with increasing size. The CCD angle is 140° . All Bimetric stems were cemented

with vacuum-mixed Palacos cement with gentamicin (Schering-Plough), and modern cementing technique was used with brushing of the canal and high-pressure lavage before inserting the cement and the stem.

All patients with the Cone stem were instructed to walk with partial weight bearing (15 kg) for 3 months, while the patients with Bimetric stem were allowed immediate weight bearing directly after surgery. All patients in the randomized study received a cemented Cenator (Corin, Cirencester, UK) acetabular component. The operations were done with an anterior-lateral approach. All stems were given a 28-mm chrome cobalt head. No intra-operative or postoperative complications occurred.

The study was approved by the local ethics committee (University of Uppsala) and all the patients had given their informed consent before inclusion.

Clinical examination

All patients were clinically examined preoperatively and after 3, 12 and 24 months. The clinical results were evaluated according to the Merle-d'Aubigné score (Merle-d'Aubigné and Postel 1954).

Radiography

Conventional radiographs with AP and lateral views were obtained postoperatively and after 2 years. The radiographs were evaluated by an experienced musculoskeletal radiologist who was blinded as to the RSA and clinical results. Any subsidence or radiolucency of the femur was evaluated and localization of radiolucent lines was classified according to Gruen et al. (1979).

A stem was considered loose when one or more of the following criteria was present: (1) distal migration of the femoral component within the cement mantle of > 5 mm, or within the cortical bone; (2) visible fracture of the cement mantle; (3) distal migration of the femoral component between bone and cement of > 5 mm, and presence of radiolucency between bone and cement > 2 mm wide in more than one Gruen zone (Gruen et al. 1979); (4) mid-stem pivoting of the prosthesis with lateral stem-tip shift of > 3 mm; (5) medial calcar shift of the prosthesis of > 3 mm.

Radiostereometric analysis (RSA)

The RSA procedure and analysis was performed

Table 2. 99% confidence limits for significant movements values of precision. The values represent mean values \pm 2.7 SD of the error obtained from double investigations

	n	x-axis	y-axis	z-axis	MTPM
Segment motion ^a					
Translation (mm)	26	0.17	0.43	0.43	
Rotation (degrees)	26	0.57	1.81	0.22	
Point motion ^b	37	0.24	0.35	0.91	0.93

^a Stem vs. femur.
^b Caput vs. femur.

as described previously (Selvik 1989, Kärrholm et al. 1997). At the time of operation, 5–8 tantalum ball markers (1.0 mm) were inserted into the proximal femur. RSA radiographs were taken with two X-ray tubes positioned at an angle of 40°. Both radiographs were exposed simultaneously. Two-dimensional measurements were made on a digitizing table (Biomedical Innovations AB, Umeå, Sweden). For calculation of migration, we used the computer program UMRSA (RSA Innovations). Migration of the center of the head, and the calculated rigid body of the stem was calculated related to the mathematically defined rigid body of the tantalum balls in the femur. For all 45 stems, the translation of the center of the head in the directions of the x-, y- and z-axes was calculated as well as the vectorial sum of these motions (maximal total point motion; MTPM). After we had included 11 patients, we could technically solve the task of marking the metal with tantalum balls. Thus, 18 Cone and 16 Bimetric stems were marked with 5 tantalum balls, 1 at the tip, 2 on each side of the body and 2 on each side of the hump distal to the neck. In these 34 stems, the translations and the rotations of the rigid body of the stem in the three different directions were also calculated. The precision error (value of precision) of the RSA measurements was determined on examinations postoperatively and a 99% confidence interval was chosen (Mjoberg 1986) (Table 2). A stem was considered to have migrated when the RSA value exceeded the value of precision. Comparisons were performed between the two types of stems. The initial RSA investigation was done within 1 week postoperatively, and follow-up was at 3, 12 and 24 months.

Table 3. Clinical score according to Merle d'Aubigné. n = 23 (Bimetric) and 22 (Cone)

	Preoperatively		3 months		12 months		24 months	
	Cone	Bimetric	Cone	Bimetric	Cone	Bimetric	Cone	Bimetric
Pain	2.4	2.6	5.5	5.6	5.7	5.8	5.7	5.8
Walking ability	2.7	3.0	4.6 ^a	5.5	5.8	5.8	5.9	6.0
Range of motion	4.1	4.2	5.1	5.4	5.8	5.5	5.6	5.7
Total score	9.2	9.7	15 ^b	16	17	17	17	17

^a P = 0.02, ^b P = 0.03, Cone compared with Bimetric (Kendall rank correlation coefficient test).
P = 0.001 for all follow-up values compared with preoperative values (Wilcoxon signed-rank test).

Stem survival

In order to investigate stem survival, we prospectively followed 83 Cone stems in 82 patients who had been operated 1992 through 1998 with revision as endpoint. The 22 patients from the randomized study represented a proportion of these 82 patients. Patients who died during the follow-up period were excluded. None of the patients who died had been revised. The follow-up time for the surviving patients was 8 (7–12) years. The preoperative diagnosis was CDH/Perthes for 20 stems and osteoarthritis for 63 stems.

Statistics

The values of migration are presented as signed values representing the direction of the migration. Kendall Rank correlation coefficient test was used for evaluation of the clinical score between the two study groups, and the Wilcoxon signed-rank test was used to test clinical score within the two study groups over time with preoperative measurement as baseline. Mann-Whitney U-test was used to evaluate migration between study groups. P-values less than 0.05 were considered to be significant.

Results

Clinical outcome

The Merle d'Aubigné score had improved significantly at the control examination after 3 months (Table 3). The improvement remained after 12 and 24 months. There were no significant differences between the two stems, except for walking ability at the 3-month follow-up: the patients with the cemented Bimetric stem had a higher score than the

patients in the Cone group ($p = 0.02$). No patients reported thigh pain at any time.

Radiography

None of the stems were considered to be loose according to the radiographic evaluation, although 10 of the 22 Cone stems had subsided by 1.5–2.0 mm at the 2-year control. 4 of these stems had radiolucent lines (RL) in Gruen zone 1, while 2 stems had RL without any radiographic subsidence. In total, 6/23 Cone stems showed RL, all in Gruen zone 1. 2 of these stems also showed RL in Gruen zone 7, and 1 stem showed RL in Gruen zones 6 and 7. 1 of 23 Bimetric stems had subsided 1 mm, but showed no RL. 2 Bimetric stems had RL, one in Gruen zone 1 and one in Gruen zones 1 and 7. All zones had a width less than 1 mm and the length varied from 5 to 60 mm.

Radiostereometric analysis

Both types of stem showed limited migration (Table 4). The only differences between the stems were in subsidence and varus tilt (rotation around the z-axis) starting at the 3-month evaluation. The 18 Cone stems subsided more than the 16 Bimetric stems: 0.50 mm as compared to 0.06 mm proximal migration ($p = 0.001$) (Figure 2). Measured from the center of the head, the Cone stems ($n = 22$) subsided more than the Bimetric stems ($n = 23$): 0.52 mm as compared to 0.04 mm proximal migration ($p = 0.001$). 5/18 Cone stems (10/22 of the Cone heads) had subsided more than the value of precision (indicating true subsidence) after 2 years, and most of the subsidence took place within the first 3 months. Thereafter, the Cone stem was stable. 1/16 Bimetric stems (2/23 of the Bimetric heads) had subsided more than the value of precision. The

Table 4. Stem migration. P-values are given for differences between Cone and Bimetric. Center of head translations are given for all stems, while stem translations and stem rotations are given only for stems marked with tantalum balls

	3 months			1 year			2 years		
	Mean	SD	Range	Mean	SD	Range	Mean	SD	Range
<i>Caput translations (mm)</i>									
Medial (+) Lateral (-)									
Bimetric (n=23)	-0.03	0.34	-1.03–0.77	-0.03	0.51	-1.84–0.70	0.03	0.29	-0.60–0.52
Cone (n=22)	0.09	0.36	-0.38–1.14	0.27	0.60	-0.30–2.56	0.18	0.44	-0.38–1.40
Proximal (+) Distal (-) (=subsidence)									
Bimetric	-0.03	0.34	-1.21–0.52	-0.06	0.31	-1.28–0.45	0.04	0.31	-0.85–0.73
Cone	-0.51 ^a	0.80	-2.57–0.25	-0.53 ^b	0.77	-2.55–0.12	-0.52 ^c	0.75	-2.62–0.34
Anterior (+) Posterior (-)									
Bimetric	-0.05	0.94	2.03–3.27	-0.12	1.03	-1.83–3.84	-0.46	0.67	-1.60–0.94
Cone	-0.28	0.50	-1.76–0.36	-0.64	0.75	-2.90–0.31	-0.60	0.83	-2.69–0.52
Maximal point motion									
Bimetric	0.69	0.81	0.13–3.72	0.74	0.93	0.03–4.45	0.77	0.47	0.09–1.83
Cone	0.83	0.82	0.08–2.59	1.08	1.05	0.14–4.38	1.12	0.91	0.22–3.29
<i>Stem translations (mm)</i>									
Medial (+) Lateral (-)									
Bimetric (n=16)	-0.02	0.35	1.10–0.51	-0.03	0.51	1.19–1.10	0.08	0.31	-0.21–1.09
Cone (n=18)	0.01	0.21	-0.49–0.39	-0.02	0.23	-0.46–0.60	0.02	0.29	-0.49–0.66
Proximal (+) Distal (-)									
Bimetric	0.02	0.27	-0.82–0.42	-0.03	0.34	-1.08–0.56	0.06	0.23	-0.51–0.48
Cone	-0.52 ^d	0.71	-2.49–0.07	-0.55 ^e	0.76	-2.46–0.05	-0.50 ^c	0.76	-2.51–0.03
Anterior (+) Posterior (-)									
Bimetric	-0.05	0.28	-0.72–0.35	-0.10	0.43	-1.29–0.39	0.03	0.29	-0.66–0.33
Cone	0.03	0.26	-0.33–0.64	0.16	0.49	-0.84–1.33	0.03	0.31	-0.62–0.88
<i>Stem rotations (degrees)</i>									
Anterior (+) Posterior (-) tilt									
Bimetric (n=16)	0.04	0.64	-1.10–2.00	0.10	0.69	-0.92–2.36	-0.13	0.35	-0.98–0.44
Cone (n=18)	-0.19	0.39	-0.63–0.63	-0.23	0.77	-2.20–0.77	-0.31	0.49	-1.43–0.25
Ante (-) Retroversion (+)									
Bimetric	0.05	1.09	-2.18–1.82	0.61	0.55	-0.25–1.35	0.47	0.69	-0.94–1.58
Cone	0.88	1.73	-1.67–5.95	0.53	1.52	-2.53–3.37	0.81	1.23	-0.96–3.79
Valgus (+) Varus (-)									
Bimetric	0.02	0.13	-0.16–0.36	-0.01	0.20	-0.47–0.47	0.05	0.17	-0.21–0.52
Cone	-0.18 ^f	0.26	-0.67–0.31	-0.32 ^g	0.42	-1.60–0.33	-0.22 ^b	0.34	-0.97–0.27

^a P=0.003, ^b P=0.01, ^c P=0.001, ^d P<0.001, ^e P=0.007, ^f P=0.008, ^g P=0.006

Cone stem rotated more into varus than the Bimetric stem ($p = 0.01$) (Figure 3), but even so the mean rotation of the Cone stem was small: 0.22° after 2 years. 8/18 Cone stems and 1/16 Bimetric stems migrated to varus more than the value of precision.

Both the Cone and the Bimetric heads migrated posteriorly, 0.60 and 0.46 mm respectively, but there was no significant difference between the two stems in this regard. This posterior migration corresponds to a small degree of posterior tilt of the stems, 0.31° (Cone) and 0.13° (Bimetric) mm respectively. The stems also rotated to retroversion around the y-axis, 0.81° and 0.47° respectively, but there was no significant difference between the 2 stems in this regard.

Of the 10 Cone stems that had subsided by more than 1.5 mm according to radiography, 6 had also subsided according to RSA. On the other hand, of the 10 Cone stems that had subsided more than the value of precision in the RSA study, 4 stems had not subsided at all in the radiographic evaluation.

Stem survival

In the series of 83 Cone stems followed for an average of 8 years, 2 patients had died from unrelated causes after operation. 1 stem had been revised (at 8 months) due to a deep infection.

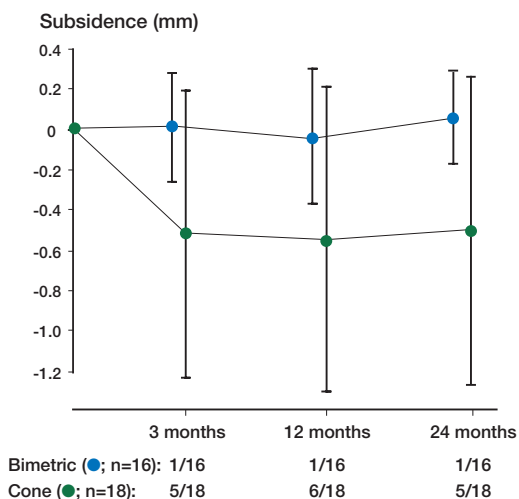


Figure 2. Subsidence over time with signed values (mean \pm SD). Only stems that were marked with tantalum balls are included. Above: Number of prostheses showing significant migration/number of available observations at each examination.

Discussion

Both the uncemented Cone and the cemented Bimetric stem showed good clinical outcome and were stable at the 2-year follow-up according to both conventional radiography and RSA micromotion. However, we found a different pattern of early micromotion between the two types of stems. The main difference was that the cemented Bimetric stem was stable from the start whereas the Cone stem subsided to a small degree, 0.51 mm (-2.57–0.25 mm), and rotated posteriorly by 0.88° (-1.67–5.95) within the first 3 months. The same pattern of migration of the Cone stem has been reported previously in a 5-year follow-up study of patients with CDH (Ström et al. 2003). Another study reported an uncemented polyethylene-coated titanium stem that showed initial subsidence and then remained stable in the proximo-distal direction combined with a retro-rotation of the stem (Nistor et al. 1991). Söballe et al. (1993) compared eight titanium-coated stems (TI) with seven hydroxyapatite stems (HA) and found the same pattern of subsidence for the HA stem as we did for the Cone prosthesis, whereas the TI-coated stem subsided over the whole 1-year period. In some cases, the early migration of the Cone stem could probably be explained by insufficient pri-

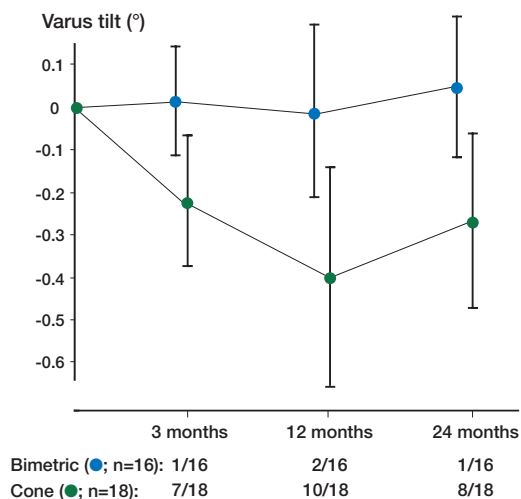


Figure 3. The varus tilt (rotation around the z-axis) over time in signed values (mean \pm SD). Only stems that were marked with tantalum balls are included. Above: Number of prostheses showing significant migration/number of available observations at each examination.

mary fixation. However, the good clinical outcome and the low degree of early subsidence followed by stabilization indicate that after the operation, the stems became stabilized by the load in spite of the fact that the patients were not allowed full weight bearing. Thus, we conclude that a small degree of migration can be tolerated in the Cone prosthesis.

The radiographic examination showed radiolucent lines in 6 of 22 radiographs with Cone stems. However, it is difficult to evaluate radiolucent lines along the Cone stem because of the longitudinal ribs. Of the 10 patients who showed subsidence of the center of the head exceeding the value of precision in the RSA evaluation, 4 patients also showed radiolucent lines. 1 of these patients had a subsidence according to RSA of 2.1 mm while the other three had a subsidence less than 1 mm. The main proportion of the subsidence took place during the first 3 months. Of the 10 Cone stems that had subsided radiographically by more than 1.5 mm, 6 had also subsided according to RSA. Also, of the 10 Cone stems that had subsided more than the value of precision in the RSA study, 4 had not subsided at all in the radiographic evaluation. Malchau et al. (1995) claimed that the femoral head has to sink at least 5 mm before the subsidence can be detected with any certainty on conventional radiographs. This is confirmed by our findings and explains the

differences between the radiographic and the RSA evaluations. Thus, conventional radiography does not appear to be reliable enough to determine subsidence between 1 and 2 mm.

The Merle d'Aubigné score for walking ability and total score was higher in the Bimetric group than in the Cone group at 3 months. This can probably be explained by the fact that the Cone patients were instructed to allow themselves partial weight bearing during the first 3 months. Some investigators have reported thigh pain after surgery with cementless devices (Callaghan et al. 1988, Bourne et al. 1994), but none of our patients reported thigh pain. This could be due to the shape of the Cone stem, which probably gives the stem a good degree of primary rotational stability. This suggestion is supported by a report by Kendrick et al. (1995) who compared 4 stems with different cross-sectional design. The fluted design—very much like the Cone stem—was found to have the best torsional resistance of the 4 cementless stems tested.

Over the years, uncemented hip stems have been found to give variable results (Söballe et al. 1993, Dowdy et al. 1997, Kim et al. 1999, Thanner et al. 1999, Romagnolo 2002). These designs are different to the Cone stem. To date, no RSA studies of the Cone stem or any stem with a similar design have been performed in patients with osteoarthritis. Kim et al. (1998) reported good clinical outcome in a 2-year follow-up study of congenitally dislocated hips (CDH). Ström et al. (2003) also reported good results in a 5-year RSA-based follow-up study of 14 CDH hips with a migration pattern similar to that found in the present study. The Cone stem was designed with a cylindrical shape, mainly for use in narrow femoral medullary canals and CDH cases. Our study indicates that this stem can be used on patients with osteoarthritis when there is a calculated distal bone contact of the implant of at least 6 cm.

We did not stratify for sex or age. The randomization gave a similar age distribution in the two groups, but not for sex. The Bimetric group had a larger proportion of males (Table 1). Males are revised more often and earlier than females (Herberts and Malchau 1997, Sylvain et al. 2001). Nevertheless, the Bimetric group had minor migration values. Furthermore, we could not find any sig-

nificant sex differences in migration in any of the groups, but the number of patients was small.

Kärrholm et al. (1994b) studied the migration of cemented TKAs and showed that a good predictor of revision within 5–7 years for cemented stems was the subsidence measured using RSA. Progressive subsidence exceeding 2 mm indicates a loose stem. There have been few reports with longer follow-up studies using RSA on uncemented stems. In a previous study, we concluded that after an initial subsidence over 3 months, the Cone stem remains stable within 5 years (as measured with RSA) (Ström et al. 2003).

The Cone stem also had a low revision rate, in spite of the fact the CDH ratio was high. Total hip replacement on patients with CDH of the hip is a technical challenge (Sugano et al. 1998). The survivorship in our study is on a par with that of the best uncemented stems in the Swedish Hip Register (Malchau et al. 2002).

Our findings indicate that both the uncemented Cone stem and the cemented Bimetric stem are suitable for young patients with osteoarthritis, and no indication of mid-term mechanical loosening could be observed. Although the Cone stem is designed for CDH hips, it seems to be suitable for patients with osteoarthritis. However, longer follow-up studies may be needed to determine whether the stability and the clinical results will last—especially in the case of the Cone stem, since this design provides a new concept for stem fixation.

Author contributions

HS planned, operated, did all the calculations, wrote the article, KK, HM, JM planned and operated, contributed to writing. BS evaluation of radiographs. JM supervised.

The authors wish to thank Mrs Monica Gelotte for excellent RSA X-ray images.

No competing interests declared.

Ballard W T, Callaghan J J, Sullivan P M, Johnston R C. The results of improved cementing techniques for total hip arthroplasty in patients less than fifty years old. A ten-year follow-up study. *J Bone Joint Surg (Am)* 1995; 77 (5): 808-9.

- Bourne R B, Rorabeck C H, Ghazal M E, Lee M H. Pain in the thigh following total hip replacement with a porous-coated anatomic prosthesis for osteoarthritis. A five-year follow-up study. *J Bone Joint Surg (Am)* 1994; 76 (10): 1464-70.
- Callaghan J J, Dysart S H, Savory C G. The uncemented porous-coated anatomic total hip prosthesis. Two-year results of a prospective consecutive series. *J Bone Joint Surg (Am)* 1988; 70 (3): 337-46.
- Dowdy P A, Rorabeck C H, Bourne R B. Uncemented total hip arthroplasty in patients 50 years of age or younger. *J Arthroplasty* 1997; 12 (8): 853-62.
- Gruen T A, McNeice G M, Amstutz H C. "Modes of failure" of cemented stem-type femoral components: a radiographic analysis of loosening. *Clin Orthop* 1979; (141): 17-27.
- Herberts P, Malchau H. How outcome studies have changed total hip arthroplasty practices in Sweden. *Clin Orthop* 1997; (344): 44-60.
- Hozack W J, Rothman R H, Booth R J, Balderston R A. Cemented versus cementless total hip arthroplasty. A comparative study of equivalent patient populations. *Clin Orthop* 1993; (289): 161-5.
- Kärrholm J, Snorrason F. Subsidence, tip, and hump micromovements of noncoated ribbed femoral prostheses. *Clin Orthop* 1993; (287): 50-60.
- Kärrholm J, Borssen B, Löwenhielm G, Snorrason F. Does early micromotion of femoral stem prostheses matter? 4-7-year stereoradiographic follow-up of 84 cemented prostheses. *J Bone Joint Surg (Br)* 1994a; 76 (6): 912-7.
- Kärrholm J, Malchau H, Snorrason F, Herberts P. Micromotion of femoral stems in total hip arthroplasty. A randomized study of cemented, hydroxyapatite-coated, and porous-coated stems with roentgen stereophotogrammetric analysis. *J Bone Joint Surg (Am)* 1994b; 76 (11): 1692-705.
- Kärrholm J, Herberts P, Hultmark P, Malchau H, Nivbrant B, Thanner J. Radiostereometry of hip prostheses. Review of methodology and clinical results. *Clin Orthop* 1997; (344): 94-110.
- Kendrick J B I, Noble P C, Tullos H. Distal stem design and the torsion stability of cementless femoral stems. *The Journal of Arthroplasty* 1995; 10 (4): 463-9.
- Kim Y Y, Kim B J, Ko H S, Sung Y B, Kim S K, Shim J C. Total hip reconstruction in the anatomically distorted hip. Cemented versus hybrid total hip arthroplasty. *Arch Orthop Trauma Surg* 1998; 117 (1-2): 8-14.
- Kim Y H, Kim J S, Cho S H. Primary total hip arthroplasty with a cementless porous-coated anatomic total hip prosthesis: 10- to 12-year results of prospective and consecutive series. *J Arthroplasty* 1999; 14 (5): 538-48.
- Malchau H, Kärrholm J, Wang Y X, Herberts P. Accuracy of migration analysis in hip arthroplasty. Digitized and conventional radiography, compared to radiostereometry in 51 patients. *Acta Orthop Scand* 1995; 66 (5): 418-24.
- Malchau H, Herberts P, Eisler T, Garellick G, Söderman P. The Swedish Total Hip Replacement Register. *J Bone Joint Surg (Am)* (Suppl 2) 2002; 84: 2-20.
- Merle-d'Aubigne R, Postel M. Functional results of hip arthroplasty with acrylic prosthesis. *J Bone Joint Surg (Am)* 1954; 36: 451-75.
- Mjöberg B. Loosening of the cemented hip prosthesis. The importance of heat injury. *Acta Orthop Scand* (Suppl 221) 1986: 1-40.
- Neumann L, Freund K G, Sorensen H. Total hip arthroplasty with the Charnley prosthesis in patients fifty-five years old and less. *J Bone Joint Surg (Am)* 1996; 78: 73-9.
- Nistor L, Blaha J D, Kjellström U, Selvik G. In vivo measurements of relative motion between an uncemented femoral total hip component and the femur by roentgen stereophotogrammetric analysis. *Clin Orthop* 1991; (269): 220-7.
- Önsten I, Carlsson A S, Sanzen L, Besjakov J. Migration and wear of a hydroxyapatite-coated hip prosthesis. A controlled roentgen stereophotogrammetric study. *J Bone Joint Surg (Br)* 1996; 78 (1): 85-91.
- Romagnolo S. Press-fit hip arthroplasty: a European alternative. *J Arthroplasty* (Suppl 1) 2002; 17: 108-12.
- Selvik G. Roentgen stereophotogrammetry. A method for the study of the kinematics of the skeletal system. *Acta Orthop Scand* (Suppl 232) 1989: 1-51.
- Söballe K, Toksvig L S, Gelineck J, Fruensgaard S, Hansen E S, Ryd L, Lucht U, Bunger C. Migration of hydroxyapatite coated femoral prostheses. A Roentgen stereophotogrammetric study. *J Bone Joint Surg (Br)* 1993; 75 (5): 681-7.
- Ström H, Mallmin H, Pétren-Mallmin M, Milbrink J, Kolstad K. The Cone hip stem. A prospective study of 13 patients followed for 5 years with RSA. *Acta Orthop Scand* 2003; 74 (5): 525-30.
- Sugano N, Noble P C, Kamaric E, Salama J K, Ochi T, Tullos H S. The morphology of the femur in developmental dysplasia of the hip. *J Bone Joint Surg (Br)* 1998; 80 (4): 711-9.
- Sylvain G M, Kassab S, Coutts R, Santore R. Early failure of a roughened surface, precoated femoral component in total hip arthroplasty. *J Arthroplasty* 2001; 16 (2): 141-8.
- Thanner J, Kärrholm J, Malchau H, Herberts P. Poor outcome of the PCA and Harris-Galante hip prostheses. Randomized study of 171 arthroplasties with 9-year follow-up. *Acta Orthop Scand* 1999; 70 (2): 155-62.
- Wagner H, Wagner M. Conical stem fixation for cementless hip prosthesis for primary hip prosthesis and revisions (ed. Morsher E). Springer Verlag, Berlin 1995: 258-67.
- Wroblewski B M. Cementless versus cemented total hip arthroplasty. A scientific controversy? *Orthop Clin North Am* 1993; 24 (4): 591-7.
- Wroblewski B M, Siney P D. Charnley low-friction arthroplasty of the hip. Long-term results. *Clin Orthop* 1993; (292): 191-201.