

Prosthesis survival after total hip arthroplasty—does surgical approach matter?

Analysis of 19,304 Charnley and 6,002 Exeter primary total hip arthroplasties reported to the Norwegian Arthroplasty Register

Astvaldur J Arthursson¹, Ove Furnes^{2,4}, Birgitte Espehaug², Leif I Havelin^{2,4}, and Jon Arne Söreide^{3,4}

¹Stavanger University Hospital, Department of Orthopedic Surgery, NO-4068 Stavanger, ²The Norwegian Arthroplasty Register, Department of Orthopedic Surgery, Haukeland University Hospital, NO-5021 Bergen, ³Stavanger University Hospital, Department of General Surgery, NO-4068 Stavanger, ⁴Department of the Surgical Sciences, University of Bergen, Norway
Correspondence AJA: addi@lyse.net
Submitted 06-12-12. Accepted 07-05-07

Background and purpose Controversies still exist about whether there is any effect of operative approach on survival of hip prostheses. We compared long-term survival of primary total hip arthroplasties in a well-defined study population from a national prospective population-based registry with regard to the three most commonly used surgical approaches.

Methods We assessed prosthesis survival according to surgical approach (the lateral with or without trochanteric osteotomy, and the posterolateral) for 19,304 Charnley and 6,002 Exeter total hip arthroplasties performed from 1987 to 2004.

Results For Charnley total hip arthroplasties, lateral approach with trochanteric osteotomy had a lower probability of revision than lateral approach without trochanteric osteotomy (RR = 0.6, 95% CI: 0.5–0.8). The lower revision rate was due to fewer revisions for aseptic loosening and dislocation. The differences had declined in the latest time period (1995–2004). We observed no differences between lateral approach without trochanteric osteotomy and posterolateral approach, except that there were more revisions due to dislocation in the posterolateral approach group (RR = 1.9, 95% CI: 1.1–3.2). No statistically significant differences were observed for Exeter total hip arthroplasties.

Interpretation For Charnley prostheses, the lateral approach with trochanteric osteotomy gave a reduced revision risk compared to the other approaches, which was due to fewer revisions for dislocation, and in the

first time period also fewer revisions due to aseptic loosening. ■

Several controversies still exist in hip joint arthroplasty, including the effect of operative approach. Each surgical approach to the hip has certain advantages and disadvantages. The reported frequency of early complications and revisions related to different surgical approaches varies in the literature. The approach with trochanteric osteotomy has been associated with trochanteric pain, limp, and dislocation if trochanteric nonunion occurs. The rate of trochanteric nonunion after trochanteric osteotomy has been reported to be between 0.8% and 32% (Wroblewski and Shelley 1985, Pai 1997, Schinsky et al. 2003). Trochanteric nonunion may lead to a need for repeated surgery. Morrey (1992) found a sixfold increase in hip instability with nonunion of the trochanter. The advantages are good exposure of the femur and acetabulum, facilitating cup and stem positioning. It also affords the possibility of tightening the abductor muscles when preparing and reinserting the trochanter. This may reduce the rate of dislocation.

The lateral approach to the hip, without trochanteric osteotomy, has been blamed for an increased risk of damage to the superior gluteal nerve as

well as to the gluteus medius muscle, resulting in a high prevalence of postoperative limp or dislocation (Downing et al. 2001, Masonis and Bourne, 2002). Increased heterotopic ossification has also been reported (Mulliken et al. 1998). The exposure of the femur is more restricted than in the posterior approach, but it allows good exposure of the acetabulum and the possibility of good cup positioning.

The posterior approach is considered to have less effect on gait since the abductor muscles are not dissected, but it has been associated with the highest rate of postoperative instability (Masonis and Bourne 2002). It is often more difficult to expose the acetabulum for correct cup position. It also gives increased risk of injury to the sciatic nerve, which is close to the operative field. The advantages are good exposure of the femur, shorter operation time, and possibly less blood loss.

The Norwegian Arthroplasty Register (NAR) contains prospective data on more than 90,000 primary total hip arthroplasties (THAs) and enables analysis of various aspects of hip arthroplasty surgery, including the surgical approach.

The purpose of this study was to compare the long-term survival of primary THAs in two well-defined study populations from a national prospective and consecutive population-based registry, with regard to the three commonest surgical approaches (i.e. the lateral approach with and without trochanteric osteotomy, and the posterolateral approach).

Patients and methods

The Norwegian Arthroplasty Register (NAR), a population-based prospective clinical database, was established in September 1987 (Havelin et al. 1993, 2000). Data on THA are reported from all Norwegian hospitals involved with arthroplasty operations. A standard form (Havelin 1999), filled in by the orthopedic surgeon, is used for both primary operations and revisions. Information on primary arthroplasties and possible subsequent revisions is linked by use of the unique (11-digit) identification number assigned to every citizen of Norway. Every revision can be traced, and pertinent information about revisions is available irrespective of where in Norway the patients live. The quality of the NAR

data has recently been evaluated and validated at one high-volume hospital, and it was found to be complete and reliable—both for primary operations and revisions. About 98% of THAs done in our country are reported to the register (Havelin et al. 2000, Arthursson et al. 2005, Espehaug et al. 2006).

Definitions

The lateral approach (LA) is performed with a longitudinal skin incision centered over the greater trochanter. The gluteal fascia and the iliotibial band are exposed and incised in the line of the incision. Without a trochanteric osteotomy, the gluteus medius is split down to the major trochanter. The incision is prolonged distally into the vastus lateralis and medially through the anterior portion of the gluteus minimus. The capsule of the hip can either be incised or excised (Hardinge 1982). If a lateral approach with trochanteric osteotomy is used, the patient is usually in supine position and the major trochanter is released with an osteotomy. The major trochanter with the m. gluteus medius and m. gluteus minimus is elevated and held proximally by use of a spike into os ilium, just above the acetabulum (Charnley 1979).

The posterolateral (posterior) approach (PA) is posterior to the m. gluteus medius and is performed through a curved incision centered on the posterior aspect of the greater trochanter. The fascia lata is incised in the line of the incision and the fibers of the gluteus maximus split by blunt dissection. The short external rotators are then detached close to their femoral insertion and reflected, exposing the posterior aspect of the hip joint capsule. The capsule can either be incised or excised (Moore 1959). During closure, the external rotators are usually reattached.

A revision is defined as the surgical removal or exchange of the whole or part of the hip implant.

Study population

Between 1987 and 2004, 90,960 primary total hip replacements were reported to the NAR. The Charnley prosthesis was the most common prosthesis ($n = 36,378$) and it was also the only prosthesis to be used in sufficient numbers with 3 different surgical approaches. We therefore selected Charnley THAs for the present study.

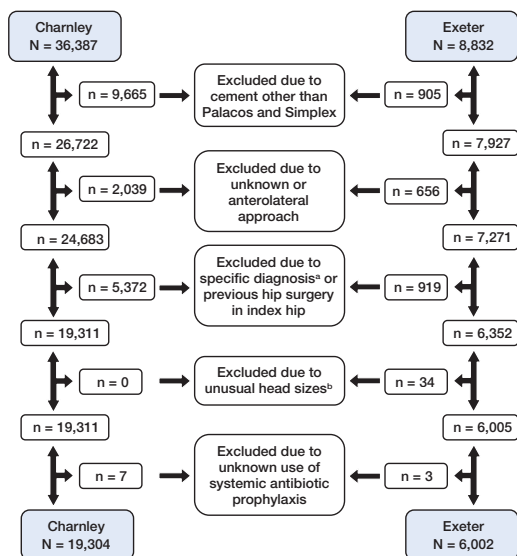


Figure 1. Details of the selection procedure used for THAs registered in the Norwegian Arthroplasty Register between 1987 and 2004.

^a Dysplasia with high dislocation and sequela after hip fracture.

^b For Exeter other head size than 26, 28, and 30 mm.

The second most common prosthesis (the Exeter THA polished stem ($n = 8,832$)) had been inserted using the posterior approach or the direct lateral approach without trochanteric osteotomy, and this prosthesis was also included. A detailed account of the selection procedures is given in Figure 1. Due to previous reports on inferior results for several cement types (Havelin et al. 1995, Furnes et al. 1997, Espehaug et al. 2002), we included only prostheses where both components had been fixed with either Palacos or Simplex cement. Furthermore, we included only operations with the approaches that had been used in sufficiently high numbers (the lateral or posterolateral surgical approaches, where the lateral approach had been performed either with or without trochanteric osteotomy). For Exeter prostheses, the lateral approach with a trochanteric osteotomy had been used in only 12 procedures and this group was thus excluded.

To make the study groups homogenous and comparable, we included only patients without previous operations in the index hip, and only patients operated on due to primary osteoarthritis, rheumatoid arthritis, congenital dysplasia without dislocation, complications after epiphysiolyis or Perthes'

disease, or ankylosing spondylitis. Exeter prostheses with femoral head sizes other than 26, 28, or 30 mm were also excluded. Lastly, 10 operations with unknown use of systemic antibiotic prophylaxis were also excluded.

Statistics

Prosthesis lifetimes were calculated separately for the Charnley and Exeter prostheses by using various endpoints, including revision for any cause, or for deep infection, dislocation, or aseptic loosening. Additional analyses were done with revision due to aseptic loosening of the cup or the stem, respectively, as endpoints.

Information on deaths or emigrations of patients was provided by Statistics Norway, Oslo, and follow-up of prostheses in these patients was censored at the time of death or emigration. The follow-up had ended by December 31, 2004.

Cox regression analysis provided estimates of relative revision risk (incidence rate ratios) (RR) for the different surgical approaches with adjustment for possible confounding by gender, age (< 60, 60–69, 70–79, or ≥ 80 years), diagnosis (primary osteoarthritis, other diagnoses), type of cement (Palacos, Simplex), use of systemic antibiotic prophylaxis (yes, no), and antibiotic-containing cement (yes, no). Also, the Cox analyses were performed separately for Charnley and Exeter prostheses. In analyses that included Exeter prostheses only, the regression model also included the diameter of the caput (26 mm, 28 mm, or 30 mm). Estimates from the Cox regression analyses (stratified by surgical approach) were used to construct survival curves for mean values of the covariates, and to calculate 7- and 15-year adjusted revision probabilities, for mean values of the covariates. For the median follow-up estimate, the method described by Schemper and co-workers was used (Schemper and Smith 1996).

In our study population, the lateral approach without trochanteric osteotomy was more commonly used late in the study period. Thus, we have delineated two different time periods, an early registration period (September 1987–December 1994) and a late registration period (January 1995–December 2004), respectively.

SPSS software version 12.01 (SPSS Inc., Chicago, IL) and S-Plus 2000 (MathSoft Inc., Seattle,

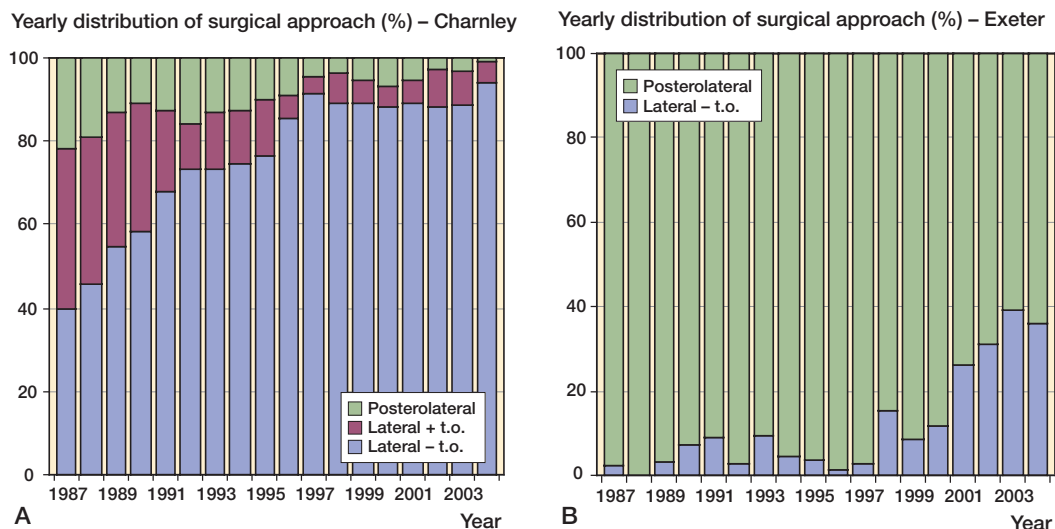


Figure 2. Distribution of surgical approaches used for Charnley and Exeter THA in 1987–2004.

WA) were used for statistical calculations. A p -value of < 0.05 was considered statistically significant.

Results

Charnley THA

The lateral approach without trochanteric osteotomy was most commonly employed (80%) in the 19,304 Charnley THA operations. The Charnley THA was used at 57 of 82 hospitals reporting information on THAs to the NAR. The preferred surgical approach for Charnley THA changed during the study period, and the lateral approach without trochanteric osteotomy was more frequently used later in the study period (Figure 2A). Except for cement brand and use of antibiotic-containing cement, only marginal differences between pertinent variables were observed among the different operative approach groups. With the posterolateral approach, fewer patients received cements containing antibiotics (Table 1).

For Charnley THA, the lowest probability of revision was found in patients operated by the lateral approach with trochanteric osteotomy (Figure 3A). This was also found for revisions performed due to dislocation and aseptic loosening. However, for revisions due to infection there were no statistically significant differences between the study

groups. The greatest difference was observed when revision performed due to dislocation was used as endpoint ($RR = 0.2$, $p < 0.01$) comparing the lateral approaches with and without trochanteric osteotomy. For Charnley THA, revision risks with the posterolateral approach were similar to those with the lateral approach without trochanteric osteotomy, except for revision due to dislocation as endpoint—where the posterolateral approach was associated with an increased revision risk ($RR = 1.9$, $p = 0.02$) (Table 2).

Exeter THA

The 6,002 Exeter THAs were done at 26 different hospitals, with the posterolateral approach being used most often (84%). The distribution of age, gender, diagnoses, and use of antibiotic prophylaxis was similar among the study groups, but fewer patients received cements containing antibiotics when the posterolateral approach was used (Table 1). The preferred surgical approach for Exeter THA changed during the study period, and use of the lateral approach without trochanteric osteotomy increased during the last 5 years (Figure 2B).

In the group of Exeter THAs, we found no differences in survival between the lateral approach without trochanteric osteotomy and the posterolateral approach (Table 2). Cox survival curves for 6,002 Exeter THAs, with revision for any cause as

Table 1. Details of 19,304 Charnley and 6,002 Exeter THAs operated between 1987 and 2004

	Charnley THA			Total	Exeter THA		Total
	Lateral without TO ^a	Lateral with TO	Postero-lateral		Lateral without TO	Postero-lateral	
THA (1987–2004)	15,400	2,321	1,583	19,304	981	5,021	6,002
THA (1987–1994)	4,013	1,422	885	6,320			
THA (1995–2004)	11,387	899	698	12,984			
No. of hospitals (1987–2004)	54	36	32	57	17	22	26
Females (%)	72	69	68	71	70	70	70
Median age (years)	73	72	72	72	73	71	71
Range	(17–95)	(22–94)	(42–92)	(17–95)	(27–91)	(25–93)	(25–93)
Diagnoses of O.A. (%)	90	90	93	90.0	86	88	88
Systemic antibiotics (%)	98	99	97	98	100	100	100
Antibiotic-containing cement (%)	84	91	66	84	86	51	57
Palacos/Simplex cement (%)	84 / 16	91 / 9	63 / 37	83 / 17	87 / 13	54 / 46	59 / 41
Median follow-up (years) (95% CI)	5.4 (5.3–5.5)	9.1 (8.8–9.4)	8.9 (8.6–9.2)	6.0 (5.9–6.1)	2.2 (2.1–2.3)	6.3 (6.1–6.5)	5.6 (5.4–5.8)

^a TO: trochanteric osteotomy.

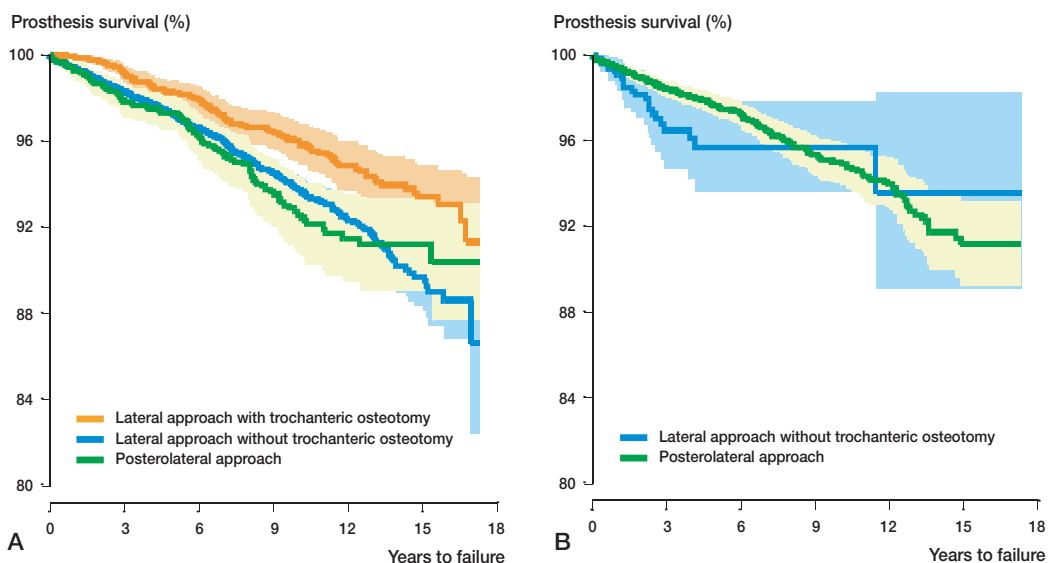


Figure 3. Survival curves based on Cox multiple regression (by surgical approach) based on 19,304 Charnley THAs and 6,002 Exeter THAs performed between 1987 and 2004, with all revisions as endpoint. A. Charnley THA; B. Exeter THA

endpoint and with adjustment for confounders, are given in Figure 3B.

Time period analysis

Analyses based on Charnley THAs from the early time period (1987–1994) showed mainly the same findings as for the whole time period (Table 3).

For revision due to dislocation, however, the difference between lateral approach with and without osteotomy was smaller (RR = 0.4) and no longer statistically significant ($p = 0.09$).

For the last period (1995–2004), there were no statistically significant differences between the three approaches (Table 3). Figure 4 shows

Table 2. Relative revision risk (RR) based on Cox regression analysis with adjustment for confounders, for 19,304 Charnley and 6,002 Exeter THAs operated between 1987 and 2004

Reason for revision	Approach	No. of revisions	Charnley THA			p	Exeter THA						
			Estimated rev. % 7 years	Estimated rev. % 15 years	RR		95% CI	No. of revisions	Estimated rev. % 7 years	Estimated rev. % 15 years	RR	95% CI	p
Any cause of revision													
	Lateral –TO ^a	624	3.4	10.3	1		23	4.2	6.4	1			
	Posterolateral	98	4.7	8.8	1.1	0.8–1.4	0.6	197	3.5	8.7	0.9	0.5–1.4	0.5
	Lateral +TO ^b	98	2.8	6.6	0.6	0.5–0.8	< 0.01						
Infection													
	Lateral –TO	91	0.6	0.8	1		5	0.5	0.6	1			
	Posterolateral	6	0.2	0.5	0.6	0.2–1.4	0.2	23	0.4	0.5	0.5	0.1–1.8	0.3
	Lateral +TO	10	0.3	0.8	0.6	0.3–1.2	0.2						
Dislocation													
	Lateral –TO	99	0.8	1.2	1		8	1.9	1.9 ^c	1			
	Posterolateral	21	1.1	2.1	1.9	1.1–3.2	0.02	43	0.8	1.6	0.6	0.2–1.6	0.4
	Lateral +TO	5	0.1	0.4	0.2	0.1–0.6	< 0.01						
Aseptic loosening													
	Lateral –TO	410	2.5	7.6	1		9	1.8	3.7	1			
	Posterolateral	65	2.9	6.0	1.0	0.7–1.3	1.0	115	1.7	5.6	0.7	0.4–1.6	0.5
	Lateral +TO	82	2.2	5.1	0.7	0.6–0.9	0.01						
Aseptic loosening of cup													
	Lateral –TO	197	1.1	3.8	1								
	Posterolateral	42	1.9	3.7	1.4	0.9–2.1	0.09						
	Lateral +TO	29	0.5	1.8	0.5	0.3–0.7	0.01						
Aseptic loosening of stem													
	Lateral –TO	378	2.3	7.1	1								
	Posterolateral	56	2.3	5.1	0.9	0.6–1.3	0.5						
	Lateral +TO	76	2.1	4.6	0.7	0.6–0.9	0.02						

^a – TO: without trochanteric osteotomy.

^b + TO: with trochanteric osteotomy.

^c Last revision at 7 years.

the Cox survival curves based on revision due to aseptic loosening for the early and late registration periods. With revision due to dislocation, however, the estimated relative revision risks were similar to those observed for the whole period in the last period also, although the differences were small and not statistically significant (Tables 2 and 3, Figure 5). For Charnley THA, after 7 years there were more revisions due to dislocation with the posterior approach in the late period (2%) than in the first period (1%) (Table 3). For the Exeter prostheses, the results were the same in both time periods.

Discussion

For Charnley THAs performed between 1987 and

1994, the best long-term survival was observed when the lateral approach with a trochanteric osteotomy was used. The dislocation rate was one-fifth of that in patients in whom a lateral approach without trochanteric osteotomy was employed, and as low as 10% of the dislocation rate with the posterolateral approach. The frequency of aseptic loosening of cup or stem was also lower than when the lateral approach without trochanteric osteotomy or posterolateral approach had been used. Some authors claim that trochanteric osteotomy provides a better approach to the proximal femur (Stark et al. 1982). They have found it easier to avoid a varus position of the stem and a position of the distal tip that is too posterior, and they have also found that this approach allows a better cement mantle (Ebramzadeh et al. 1994, Garellick et al. 1999).

Table 3. Relative revision risk (RR) estimates based on Cox regression analysis with adjustment for confounders, for Charnley THAs operated in 2 different time periods

Reason for revision	Approach	Charnley THA operated 1987–1994					p	Charnley THA operated 1995–2004				
		No. of revisions	Estimated rev. %	RR	95% CI	No. of revisions		Estimated rev. %	RR	95% CI	p	
			7 years	15 years								
Any cause of revision												
	Lateral –TO ^a	315	4.6	11.0	1			309	3.7	1		
	Posterolateral	68	5.0	10.0	1.0	0.7–1.4	0.9	30	4.5	1.1	0.8–1.7	0.4
	Lateral +TO ^b	73	2.4	6.4	0.5	0.4–0.7	<0.01	25	4.2	0.9	0.6–1.4	0.7
Infection												
	Lateral –TO	30	0.5	0.7	1			61	0.6	1		
	Posterolateral	4	0.4	0.5 ^c	0.8	0.2–2.8	0.7	2	0.2 ^f	0.5	0.1–1.9	0.3
	Lateral +TO	4	0.1	0.5	0.4	0.1–1.3	0.1	6	0.8 ^h	1.3	0.5–3.0	0.5
Dislocation												
	Lateral –TO	24	0.5	1.1	1			75	0.9	1		
	Posterolateral	12	1.0	2.6	2.4	0.9–5.6	0.05	9	2.0	1.9	0.9–3.7	0.08
	Lateral +TO	4	0.1	0.7	0.4	0.1–1.1	0.09	1	0.1 ^B	0.2	0.02–1.3	0.08
Aseptic loosening												
	Lateral –TO	251	3.5	8.9	1			161	2.0	1		
	Posterolateral	48	3.5	6.8 ^e	0.9	0.6–1.3	0.5	17	2.6	1.1	0.7–1.8	0.6
	Lateral +TO	65	2.1	5.7	0.6	0.4–0.8	<0.01	17	2.8	1.1	0.7–1.8	0.7
Aseptic loosening of cup												
	Lateral –TO	112	1.2	4.0	1			85	1.1	1		
	Posterolateral	31	2.3	3.8 ^d	1.3	0.8–2.1	0.3	11	1.9	1.5	0.8–2.1	0.2
	Lateral +TO	26	0.5	2.7	0.5	0.3–0.8	0.02	3	0.5 ^B	0.4	0.1–1.2	0.9
Aseptic loosening of stem												
	Lateral –TO	229	3.3	8.3	1			151	1.8	1		
	Posterolateral	44	3.0	6.1 ^e	0.9	0.6–1.3	0.5	12	2.0	0.8	0.5–1.5	0.6
	Lateral +TO	60	2.1	4.6	0.6	0.4–0.8	<0.01	16	2.7	1.1	0.7–1.8	0.7

^a –TO: without trochanteric osteotomy.

^b +TO: with trochanteric osteotomy.

^c Last revision at 8 years.

^d Last revision at 11 years.

^e Last revision at 13 years.

^f Last revision at 0.5 years.

^g Last revision at 2 years.

^h Last revision at 4 years.

^B Last revision at 5 years.

Late aseptic loosening of the acetabular component has been reported to be a problem (Garcia-Cimbrelo and Munuera 1992, Ranawat et al. 1995). The inferior result of the cups operated with a lateral approach without trochanteric osteotomy—as compared to lateral approach with trochanteric osteotomy—is interesting. To our knowledge this has not been reported previously. Several explanations may be relevant, including the possibility that trochanteric osteotomy in a supine position might give (1) a better overview of the acetabulum and easier orientation of the pelvis, making the correct orientation of the cup easier; (2) less residual blood in the acetabulum in the supine position, providing

a dryer acetabulum during the cementing process (Bannister and Miles 1988); (3) improved position and approach to push and stabilize the cup, and consequently better cementing technique to achieve a stronger cement-bone interface (Stark et al. 1982, Flivik et al. 2004); (4) less micromovements during the cementing process (Schmalzried et al. 1992). As the lateral approach without a trochanteric osteotomy and performed in a side position was introduced in many hospitals during the first time period, the learning process may have contributed to inferior results with this approach.

We found that differences in results between the various surgical approaches decreased after 1994,

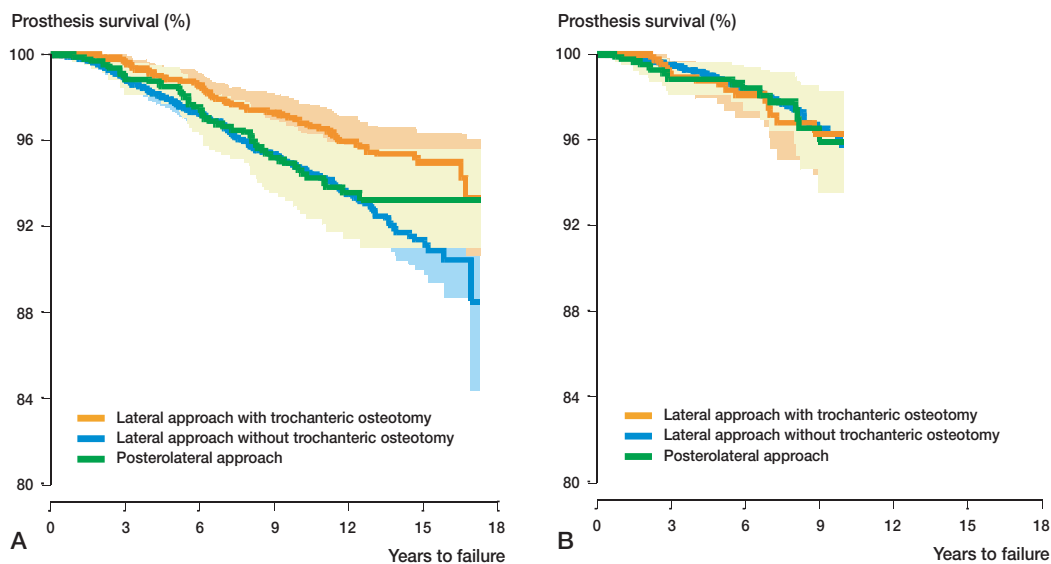


Figure 4. Survival curves based on Cox multiple regression (by surgical approach) based on primary Charnley THAs, with revision due to aseptic loosening as endpoint. A. 6,320 Charnley THAs performed 1987 through 1994; B. 12,984 Charnley THAs performed 1995 through 2004.

except for revision due to dislocation. One possible explanation could be that use of the posterolateral and lateral approaches without trochanteric osteotomy were eventually more commonly employed, and that the surgeons had reached a high level of competence on the “learning curve”. Another explanation could be that new instrumentation for this approach became available, and enabled a more accurate insertion of the prosthesis. This new technique includes removal of bone from the posterior part of the piriform fossa, and a more accurate positioning of the femoral stem may be achieved (Ostgaard et al. 2001). A third explanation would be that use of modern cementing techniques (third or fourth generation) (Herberts and Malchau 2000) expands the tolerance margins of the cementing process, which may compensate for technical difficulties with the exposure and overview.

Hedlund et al. (1995) reported a higher number of early dislocations after the posterior approach than after the lateral approach with trochanteric osteotomy, but without any increase in the rate of recurrent dislocation or revision. They found that the revision rates in patients operated using the lateral approach with trochanteric osteotomy or the posterolateral approach were similar. In our study, the posterolateral approach with Charnley THAs were

associated with an almost twofold increased risk of revision due to dislocation as compared to the lateral approach without trochanteric osteotomy.

When using the posterolateral approach, to prevent posterior dislocations it has been recommended in the international literature that one should suture the posterior joint capsule and the internal rotator muscles (Jolles and Bogoch 2004). This recommendation does not appear to have lowered the dislocation rate in the Charnley THAs in the late registration period, where revisions due to dislocations after the posterolateral approach had increased after 7 years. For the Exeter THA, however, Bystrom et al. found that with larger diameter heads (30 mm as compared to 26 and 28 mm), dislocation rates were similar between the lateral approach without trochanteric osteotomy and the posterior approach (Bystrom et al. 2003). For THA, Berry et al. (2005) found that the posterolateral approach gave an increased risk of dislocation. Our study verifies this finding for the Charnley THA, but not for the Exeter THA. This could indicate that the posterior approach is more technique-dependent and not so prone to dislocation if it is used with larger diameter heads or modular systems with the ability to adjust tension (Bystrom et al. 2003, Berry et al. 2005).

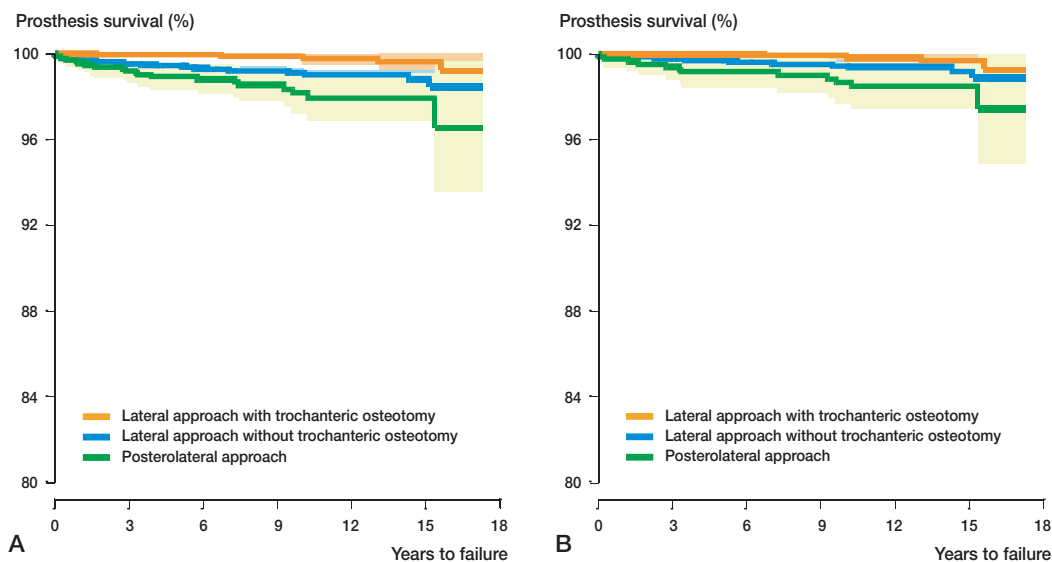
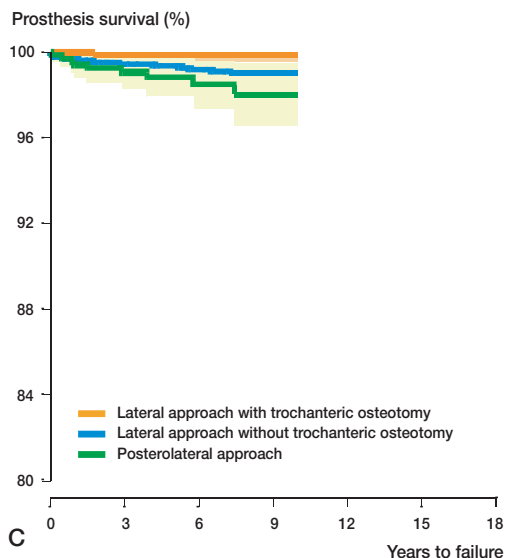


Figure 5. Survival curves based on Cox multiple regression (by surgical approach) based on 19,304 Charnley THAs performed between 1987 and 2004, with revision due to dislocation as endpoint and with a time-period analysis. A. 19,304 Charnley THAs performed 1987 through 2004; B. 6,320 Charnley THAs performed 1987 through 1994; C. 12,984 Charnley THAs performed 1995 through 2004.

Schinsky and co-workers (2003) found that when the posterior approach was used, the patients were 18.4 times ($p < 0.02$) more likely to be complication-free after 2 years of observation than patients operated with the lateral approach and trochanteric osteotomy. However, most of their complications did not require a revision.

In the literature, the reported rate of trochanteric nonunion and wire breakage after Charnley's trochanteric osteotomy varies. The incidence of trochanteric wire breakage has been reported to range from 16% to 33% (Wroblewski and Shelley 1985, Schmalzried et al. 1992). A large proportion of these patients require operation for wire removal (Clarke et al. 1979, Glassman 1992, Frankel et al. 1993, Nercessian et al. 1996). Disadvantages of the lateral approach with trochanteric osteotomy also include longer operation time, more bleeding, and complications with wire breakage, nonunion, and dislocation of the trochanter. In our study, these complications did not seem to impair the long-term survival of the THA.



In a Cochrane review of surgical approaches to the hip joint, Jolles et al. (2004) claimed that the quality and quantity of available information on the optimum choice of surgical approach for adult patients undergoing primary THA for OA was insufficient to enable a firm conclusion. Our study nevertheless shows that long-term survival varies according to the type of surgical approach used.

A trochanteric osteotomy is regarded to be technically more difficult than use of the posterolateral approach or the lateral approach without trochanteric osteotomy, but in our population-based pro-

spective study the long-term results were better when the lateral approach with trochanteric osteotomy was used.

The results concern the average surgeon and apply to an entire country, and as such they represent what can be expected using different approaches to the hip joint in an average surgical practice.

Some questions still remain to be answered, including the rates of complications of the trochanteric re-attachment technique that do not necessitate revisions, and objective figures on muscle strength and trochanteric pain after each approach. These issues require further investigation, preferably using randomized studies.

In this study we found better long-term results from the lateral approach with trochanteric osteotomy than from the lateral approach without trochanteric osteotomy and from the posterolateral approach, for Charnley THA. These differences have declined over the past 10 years, but the rate of dislocations was still lower in the trochanteric osteotomy group compared to posterolateral approach and lateral approach, and must thus be investigated further.

Contributions of authors

AJA wrote the draft manuscript and performed the statistical analysis. All authors contributed equally to the study plan, analysis of results, and revision of the manuscript.

No competing interests declared.

Arthursson A J, Furnes O, Espehaug B, Havelin L I, Soreide J A. Validation of data in the Norwegian Arthroplasty Register and the Norwegian Patient Register: 5,134 primary total hip arthroplasties and revisions operated at a single hospital between 1987 and 2003. *Acta Orthop* 2005; 76: 823-8.

Bannister G C, Miles A W. The influence of cementing technique and blood on the strength of the bone-cement interface. *Eng Med* 1988; 17: 131-3.

Berry D J, von Knoch M, Schleck C D, Harmsen W S. Effect of femoral head diameter and operative approach on risk of dislocation after primary total hip arthroplasty. *J Bone Joint Surg (Am)* 2005; 87: 2456-63.

Bystrom S, Espehaug B, Furnes O, Havelin L I. Femoral head size is a risk factor for total hip luxation: a study of 42,987 primary hip arthroplasties from the Norwegian Arthroplasty Register. *Acta Orthop Scand* 2003; 74: 514-24.

Charnley J. *Low friction arthroplasty of the hip*. Springer-Verlag, New York 1979.

Clarke R P, Shea Jr W D, Bierbaum B E. Trochanteric osteotomy: analysis of pattern of wire fixation failure and complications. *Clin Orthop* 1979; (141): 102-10.

Downing N D, Clark D I, Hutchinson J W, Colclough K, Howard P W. Hip abductor strength following total hip arthroplasty: a prospective comparison of the posterior and lateral approach in 100 patients. *Acta Orthop Scand* 2001; 72: 215-20.

Ebramzadeh E, Sarmiento A, McKellop H A, Llinas A, Gogan W. The cement mantle in total hip arthroplasty. Analysis of long-term radiographic results. *J Bone Joint Surg (Am)* 1994; 76: 77-87.

Espehaug B, Furnes O, Havelin L I, Engesaeter L B, Vollset S E. The type of cement and failure of total hip replacements. *J Bone Joint Surg (Br)* 2002; 84: 832-8.

Espehaug B, Furnes O, Havelin L I, Engesaeter L B, Vollset S E, Kindseth O. Registration completeness in the Norwegian Arthroplasty Register. *Acta Orthop* 2006; 77: 49-56.

Flivik G, Wulff K, Sanfridsson J, Ryd L. Improved acetabular pressurization gives better cement penetration: in vivo measurements during total hip arthroplasty. *J Arthroplasty* 2004; 19: 911-8.

Frankel A, Booth R E, Balderston Jr R A, Cohn J, Rothman R H. Complications of trochanteric osteotomy. Long-term implications. *Clin Orthop* 1993; (288): 209-13.

Furnes O, Lie S A, Havelin L I, Vollset S E, Engesaeter L B. Exeter and Charnley arthroplasties with Boneloc or high viscosity cement. Comparison of 1,127 arthroplasties followed for 5 years in the Norwegian Arthroplasty Register. *Acta Orthop Scand* 1997; 68: 515-20.

Garcia-Cimbrelo E, Munuera L. Early and late loosening of the acetabular cup after low-friction arthroplasty. *J Bone Joint Surg (Am)* 1992; 74: 1119-29.

Garellick G, Malchau H, Regner H, Herberts P. The Charnley versus the Spectron hip prosthesis: radiographic evaluation of a randomized, prospective study of 2 different hip implants. *J Arthroplasty* 1999; 14: 414-25.

Glassman A H. Complications of trochanteric osteotomy. *Orthop Clin North Am* 1992; 23: 321-33.

Hardinge K. The direct lateral approach to the hip. *J Bone Joint Surg (Br)* 1982; 64: 17-9.

Havelin L. The Norwegian Joint Registry. *Bull Hosp Jt Dis* 1999; 58: 139-47.

Havelin L I, Espehaug B, Vollset S E, Engesaeter L B, Langeland N. The Norwegian arthroplasty register. A survey of 17,444 hip replacements 1987-1990. *Acta Orthop Scand* 1993; 64: 245-51.

Havelin L I, Espehaug B, Vollset S E, Engesaeter L B. The effect of the type of cement on early revision of Charnley total hip prostheses. A review of eight thousand five hundred and seventy-nine primary arthroplasties from the Norwegian Arthroplasty Register. *J Bone Joint Surg (Am)* 1995; 77: 1543-50.

- Havelin L I, Engesaeter L B, Espehaug B, Furnes O, Lie S A, Vollset S E. The Norwegian Arthroplasty Register: 11 years and 73,000 arthroplasties. *Acta Orthop Scand* 2000; 71: 337-53.
- Hedlundh U, Hybbinette C H, Fredin H. Influence of surgical approach on dislocations after Charnley hip arthroplasty. *J Arthroplasty* 1995; 10: 609-14.
- Herberts P, Malchau H. Long-term registration has improved the quality of hip replacement: a review of the Swedish THR Register comparing 160,000 cases. *Acta Orthop Scand* 2000; 71: 111-21.
- Jolles B M, Bogoch E R. Posterior versus lateral surgical approach for total hip arthroplasty in adults with osteoarthritis. *Cochrane Database Syst Rev* 2004; CD003828.
- Masonis J L, Bourne R B. Surgical approach, abductor function, and total hip arthroplasty dislocation. *Clin Orthop* 2002; (405): 46-53.
- Moore A. The Moore self-locking vitallium prosthesis in fresh femoral neck fractures: a new low posterior approach (the southern exposure). In: American Academy of orthopaedic Surgeons 1995, editor. Instructional course lectures. St. Louis, CV Mosby, 1959.
- Morrey B F. Instability after total hip arthroplasty. *Orthop Clin North Am* 1992; 23: 237-48.
- Mulliken B D, Rorabeck C H, Bourne R B, Nayak N. A modified direct lateral approach in total hip arthroplasty: a comprehensive review. *J Arthroplasty* 1998; 13: 737-47.
- Nercessian O A, Newton P M, Joshi R P, Sheikh B, Eftekhari N S. Trochanteric osteotomy and wire fixation: a comparison of 2 techniques. *Clin Orthop* 1996; (333): 208-16.
- Ostgaard H C, Helger L, Regner H, Garellick G. Femoral alignment of the Charnley stem: a randomized trial comparing the original with the new instrumentation in 123 hips. *Acta Orthop Scand* 2001; 72: 228-32.
- Pai V S. A comparison of three lateral approaches in primary total hip replacement. *Int Orthop* 1997; 21: 393-8.
- Ranawat C S, Deshmukh R G, Peters L E, Umlas M E. Prediction of the long-term durability of all-polyethylene cemented sockets. *Clin Orthop* 1995; (317): 89-105.
- Schemper M, Smith T L. A note on quantifying follow-up in studies of failure time. *Control Clin Trials* 1996; 17: 343-6.
- Schinsky M F, Nercessian O A, Arons R R, Macaulay W. Comparison of complications after transtrochanteric and posterolateral approaches for primary total hip arthroplasty. *J Arthroplasty* 2003; 18: 430-4.
- Schmalzried T P, Kwong L M, Jasty M, Sedlacek R C, Haire T C, O'Connor D O, Bragdon C R, Kabo J M, Malcolm A J, Harris W H. The mechanism of loosening of cemented acetabular components in total hip arthroplasty. Analysis of specimens retrieved at autopsy. *Clin Orthop* 1992; (274): 60-78.
- Stark A, Brostrom L A, Wallensten R. Total hip replacement with or without trochanteric osteotomy. *Arch Orthop Trauma Surg* 1982; 100: 225-8.
- Wroblewski B M, Shelley P. Reattachment of the greater trochanter after hip replacement. *J Bone Joint Surg (Br)* 1985; 67: 736-40.