

## Successful conversion of a total femur knee-arthrodesing prosthesis to a functional knee construct—a case report

Jacob Bickels, Isaac Meller, Alexander Nirkin, and Yehuda Kollender

National Unit of Orthopedic Oncology, Tel-Aviv Sourasky Medical Center, Sackler Faculty of Medicine, Tel-Aviv University, Tel-Aviv, Israel  
Correspondence JB: jbickels@012.net.il  
Submitted 07-02-23. Accepted 07-03-20

Katznelson and Nerubay (1980) reported their experience with 5 cases of total femur endoprosthetic reconstruction in *Acta Orthopaedica Scandinavica* almost 3 decades ago. Their patients had primary bone sarcomas of the distal femur, the extent of which necessitated total femur resection in order to achieve wide surgical margins. Design features of the prosthesis they used for reconstruction included an Austin-Moore type head, a stabilizing platform that lay on the tibial plateau, and a long tibial stem (Figure 1). This prosthesis preserved hip motion but left the patient with a fixed knee. In 1999, a 30-year-old woman who had been similarly treated by the same authors in 1982 was referred to our institution with the request to improve her knee function. At that time she was an independent, unmarried social worker and was extremely frustrated by her inability to flex her knee. She had an osteosarcoma of the distal femur and was free of disease after surgery combined with pre- and postoperative chemotherapy. Physical examination upon referral showed considerable atrophy of all thigh muscles, but their contraction capability was preserved and sufficient muscle tissue was left for additional prosthetic coverage. We decided to replace a segment of her prosthesis to restore knee motion.

### *Prosthetic design, surgery, and outcome*

The diameter of the prosthetic femoral segment was evaluated preoperatively. A rotating-hinge, distal femoral component (Howmedica, Rutherford, NJ) was attached to a custom-made hollow cylinder whose inner diameter fitted the diameter of the original prosthetic femoral segment. This construct was also attached to a metal-backed, polyethylene tibial component which allowed rotation of the prosthetic knee (Figure 2). Surgery took place in June, 1999. Using the Black Max drilling system

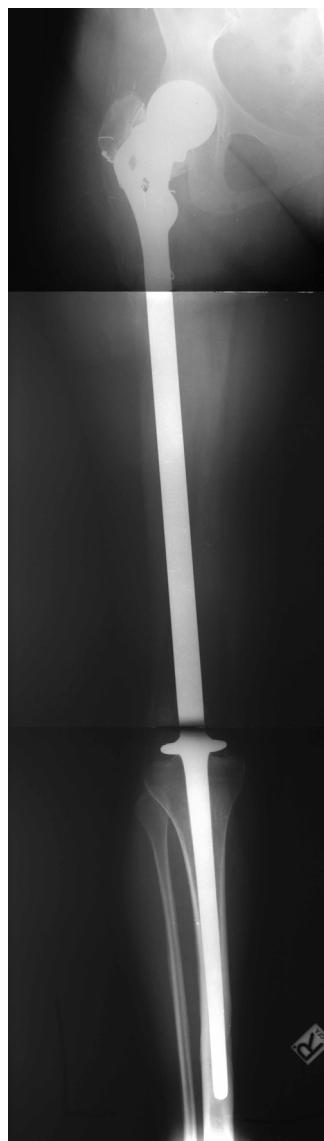


Figure 1. The prosthesis used for initial reconstruction after tumor resection. The prosthesis included an Austin-Moore type head, stabilizing platform, and a long tibial stem for a fixed knee.

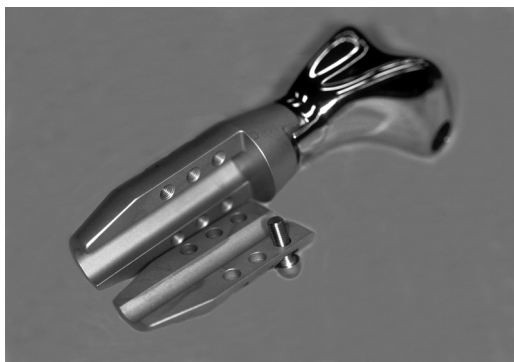

Figure 2. Rotating-hinge distal femur component connected to a hollow cylinder whose inner diameter fitted the diameter of the prosthetic femoral segment. This construct could attach to a metal-backed tibial component which allowed rotation of the prosthetic joint.

(Anspach, Lake Park, FL), the femoral segment was cut so that the remaining gap to the tibial plateau would match the size of the distal femur construct (Figure 3). The distal aspect of the prosthesis was then pulled from the tibia and a tibial osteotomy was performed as for a standard knee arthroplasty: approximately 1 cm of bone was removed with a cut perpendicular to the long axis of the tibia. The tibial component was then cemented into the tibia and the distal femoral component was connected to the prosthetic femoral segment and secured with interlocking screws (Figure 3).

Following surgery, knee motion was restricted in an immobilizing brace during wound healing. During that time, isometric exercises were carried out and full weight bearing was allowed. Active and passive range-of-motion exercises were practiced thereafter.

The patient's most recent follow-up evaluation was done in February, 2007, 7.5 years after surgery. Muscle strength was: biceps femoris, semitendinosus, and semimembranosus—4/5, quadriceps (sitting position)—2/5, gastrocnemius and soleus—4/5, and tibialis anterior—4/5. Passive knee motion was: extension—full, flexion—110°. Active knee motion in prone position was: 30° of extension lag, flexion—90°. The prosthesis was stable, with no clinical or radiological signs of loosening. The patient was ambulatory without the assistance of an orthopedic device, and was satisfied with her knee function.

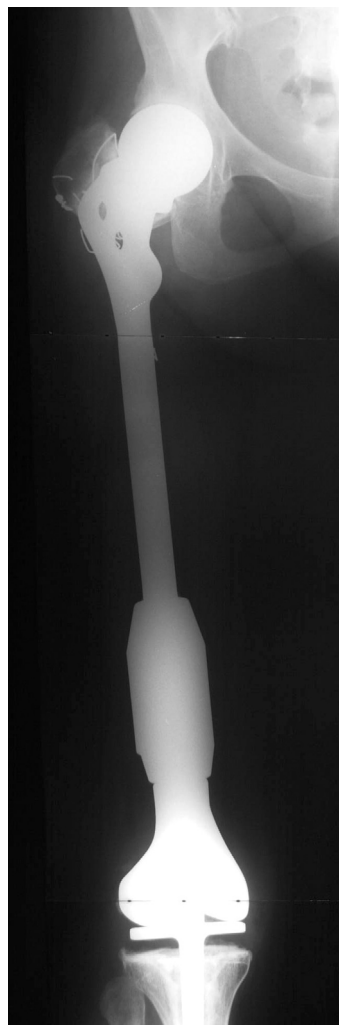


Figure 3. Postoperatively: the knee construct attached to the prosthetic femoral segment.

## Discussion

Resection arthrodesis around the knee has long been considered a viable treatment option in the management of large sarcomas of the distal femur or the proximal tibia (Enneking and Shirley 1977). It is a relatively simple procedure that allows limb-sparing and local tumor control. Function and body image are, however, considerably impaired. There have been few reports on conversion of a fused knee to an arthroplasty, and these relate to the conversion of a standard knee arthrodesis (Kim et al. 2003, Clemens et al. 2005). We believe this to be

the first reported demonstration of the conversion of a total femur knee-arthrodesing prosthesis to a functional knee construct. The design of the prosthesis that we used allows restoration of knee function in cases where the surrounding cuff of muscles allows coverage of the device and can mobilize a prosthesis. This procedure should only be offered to patients who can be committed to and withstand the burden of prolonged physiotherapy and a rehabilitation program.

We are grateful to Esther Eshkol for editorial assistance.

Clemens D, Lereim P, Holm I, Reikeras O. Conversion of knee fusion to total arthroplasty. Complications in 8 patients. *Acta Orthop Scand* 2005; 76: 370-4.

Enneking W F, Shirley P D. Resection arthrodesis for malignant and potentially malignant lesions about the knee using an intramedullary rod and local bone graft. *J Bone Joint Surg (Am)* 1977; 59: 223-35.

Katznelson A, Nerubay J. Total femur replacement in sarcoma of the distal end of the femur. *Acta Orthop Scand* 1980; 51: 845-51.

Kim Y H, Oh S H, Kim J S. Conversion of a fused knee with use of a posterior stabilized total knee prosthesis. *J Bone Joint Surg (Am)* 2003; 85: 1047-50.