

Regression of heterotopic ossification after starting warfarin—an effect mediated by inhibition of γ -carboxylation of osteocalcin?—a case report

Heikki V Valleala¹, Tom O Böhling², and Yrjö T Konttinen^{1,3,4}

Departments of ¹Medicine, Helsinki University Central Hospital, ²Pathology, HUSLAB and University of Helsinki, ³Medicine/invärtes medicin, Helsinki University Central Hospital and ORTON Orthopaedic Hospital of the Invalid Foundation, Helsinki, and ⁴COXA Hospital for Joint Replacement, Tampere, Finland.
Correspondence HV: heikki.valleala@hus.fi
Submitted 06-12-18. Accepted 07-03-05

The patient was a 54-year-old woman in whom SLE had been diagnosed at the age of 22, when she had presented with arthralgia, malar rash, and active glomerulonephritis. Initial treatment was methylprednisolone and cyclophosphamide for 12 months, and later on her lupus was well-controlled with low-dose glucocorticosteroids for 13 years. Then, at the age of 36 she was found to have developed petechiae and hematomas in her abdomen and lower extremities only 1 week after treatment with diltiazem had been started to control a newly diagnosed hypertension. On admission, her platelet count was only 3,000/mm³ but other blood cell counts were normal. Bone marrow examination showed normal numbers of megakaryocytes, suggesting peripheral consumption. Diltiazem-associated immune thrombocytopenia was suspected; the drug was withdrawn and she received high-dose methylprednisolone. The platelet counts soon reverted to her regular, slightly subnormal levels.

Soon after this incident, the patient had noticed red, swollen and painful nodules (usually 1–2 cm in diameter) in her thighs and lower legs. They hardened gradually and finally reached bony consistency. Radiographs of her right leg, taken 7 months after the episode of the grave thrombocytopenia and 5 months after she first noted the nodules, revealed multiple small soft tissue calcifications. During the following 7 years, while receiving low-dose

methylprednisolone and hydroxychloroquine, she experienced increasing discomfort because of an increasing number of small and slowly growing bony tumors. It was difficult for her to sit for any length of time. Radiographs of her legs and thighs (Figure 1A) showed that the soft tissue calcifications had increased in size. One such tumor, 2 cm × 1 cm × 0.5 cm in size, was removed from the anterior aspect of her right thigh for histological examination. It was found to be composed of lamellar bony trabeculae and of bone marrow with ongoing hematopoiesis (Figure 2), consistent with heterotopic ossification (Vanden Bossche and Vanderstraeten 2005).

As the ossification process seemed to be progressive, a trial was done with high-dose etidronate.

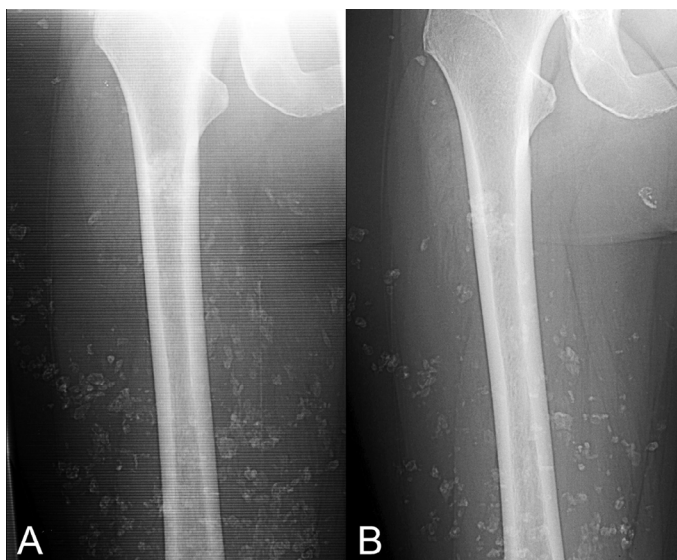

Figure 1. The right thigh before the start of anticoagulant therapy (A) and after 6 years of warfarin treatment (B).

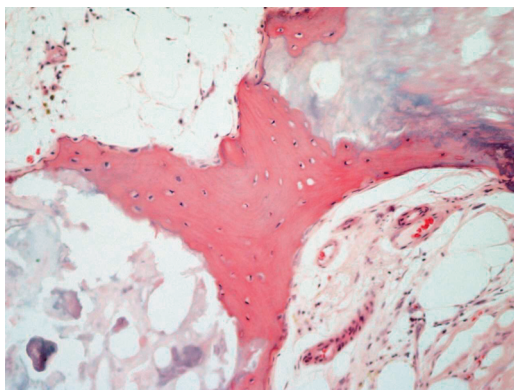


Figure 2. Mature lamellar bone containing regular osteocytes in a biopsy of one of the bone nodules in our patient (hematoxylin and eosin staining; original magnification: 200 \times).

She received two 12-week courses of etidronate, 1 g/day, with an interval of 12 weeks between the courses. The medication was associated with mild dyspepsia but no response to the treatment was noted.

During the previous year, the patient had had a mild cerebral infarction and tests after that were repeatedly positive for anti-cardiolipin antibodies. Anti-phospholipid syndrome was diagnosed, and as long-term anticoagulant therapy was considered necessary, warfarin was started soon after the last course of etidronate. During the following 6 years, her SLE ran a stable course while she was treated with low-dose methylprednisolone (2 mg daily) and hydroxychloroquine. Warfarin was used for her anti-phospholipid syndrome, and enalapril and hydrochlorothiazide for blood pressure. Gradually, the discomfort associated with her soft tissue ossifications in the lower limbs began to ease. Diminishing size and even partial disappearance of previously noted and long-lived heterotopic bone nodules was observed clinically and in the radiographs (Figure 1B).

Discussion

As the acquired form of heterotopic ossification is most frequently provoked by trauma (Vanden Bossche and Vanderstraeten 2005), bleeding might be an important precipitating factor (Vas et al. 1981) and appears to have initiated the process in

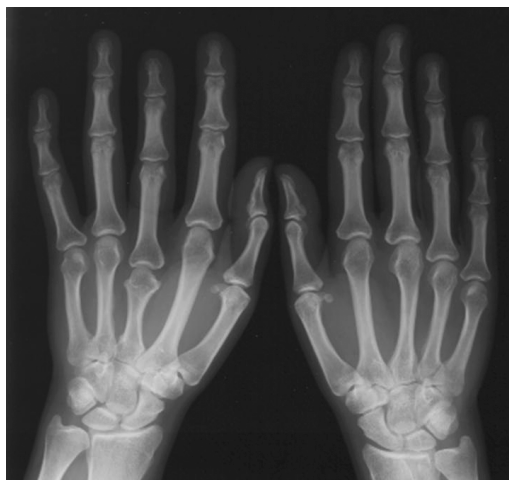

Figure 3. A short third metacarpal bone.

our case. It is important to note that heterotopic bone formation and dystrophic soft tissue calcification or calcinosis are fundamentally different. The former consists of lamellar bone, whereas the latter involves calcium phosphate deposits, which are not infrequently seen in damaged tissues.

Hereditary fibrodysplasia ossificans progressiva is an extremely rare, disabling, autosomal dominant disorder that becomes symptomatic during the first decade of life. It is characterized by heterotopic enchondral ossification of ligaments, fasciae, and striated muscles in a predictable pattern. Patients display characteristic congenital abnormalities of the skeletal system. Almost all patients have short great toes, due to synostosis or phalangeal deformities. Some patients have short and wide femoral necks, short thumbs, or abnormal metacarpals (Vanden Bossche and Vanderstraeten 2005). The gene defects of fibrodysplasia ossificans progressiva provide some hints as to the pathomechanisms of heterotopic ossification, as they are associated with a systemic overexpression of the potent bone morphogenetic protein BMP-4, and under-expression of multiple antagonists of this protein (Vanden Bossche and Vanderstraeten 2005). Our patient had a short third metacarpal bone on the right hand (Figure 3) and although the significance of this finding for the development of heterotopic ossification at sites of subcutaneous and intramuscular hematomas is not clear, it may indicate some underlying genetic predisposition to this type of unusual response.

Perioperatively administered non-steroidal anti-inflammatory drugs may prevent heterotopic ossification after hip arthroplasty (Vanden Bossche and Vanderstraeten 2005). However, the ability of pharmacological interventions to modify the long-term natural history of either developing or already established heterotopic ossification remains in doubt. Calcium-binding bisphosphonates, mainly etidronate, have been used to treat this condition. With this indication, bisphosphonates are thought to inhibit heterotopic ossification by binding to newly formed hydroxyapatite crystals. However, as bisphosphonates have no effect on bone matrix formation per se, the matrix undergoes mineralization once the drug is discontinued (Vanden Bossche and Vanderstraeten 2005). In our case, etidronate was not helpful.

One might argue that the disappearance of the bone nodules just represents a coincidence. However, the bony tumors grew relentlessly for almost 8 years and then they suddenly started to regress after initiation of warfarin therapy. This temporal association might still represent a pure coincidence if there was not a clear-cut mechanism, described in some detail below, which might explain this regression.

Osteocalcin is a major non-collagenous protein of bone matrix that has a role in bone formation. Osteocalcin is synthesized exclusively by osteoblasts and undergoes posttranslational vitamin K-dependent γ -carboxylation. Warfarin is a vitamin K antagonist that is able to inhibit γ -carboxylation. It is widely used to inhibit this type of posttranslational modification of coagulation factors II, VII, IX, X, protein C, and protein S—so also in our patient. This modification is necessary for their ability to bind calcium ions, which is necessary for blood clotting. An inhibitory effect of warfarin on

heterotopic ossification was suggested in a cohort of 227 patients with acute spinal cord injury. 33 were prophylactically treated with low-dose warfarin against deep venous thrombosis. None of these patients developed heterotopic ossification, whereas 15% of the untreated patients did (Buschbacher et al. 1992). Long-term use of warfarin may be associated with an increased risk of osteoporotic fractures (Gage et al. 2006); on the other hand, supplementation with vitamin K reduces bone loss (Cockayne et al. 2006). Our case further strengthens the evidence concerning the essential role of γ -carboxylation for the ability of osteocalcin to induce bone formation.

Contributions of authors

HV: conception of the case report, acquisition and interpretation of data, literature search, and manuscript preparation. YK: interpretation of data, literature search, and manuscript preparation. TB: microscopy, photography, and interpretation of histopathology.

Buschbacher R, McKinley W, Buschbacher L, Devaney C W, Coplin B. Warfarin in prevention of heterotopic ossification. *Am J Phys Med Rehabil* 1992; 71 (2): 86-91.

Cockayne S, Adamson J, Lanham-New S, Shearer M J, Gilbody S, Torgerson D J. Vitamin K and the prevention of fractures: systematic review and meta-analysis of randomized controlled trials. *Arch Intern Med* 2006; 166 (12): 1256-61.

Gage B F, Birman-Deych E, Radford M J, Nilasena D S, Binder E F. Risk of osteoporotic fracture in elderly patients taking warfarin: results from the National Registry of Atrial Fibrillation 2. *Arch Intern Med* 2006; 166 (12): 241-6.

Vanden Bossche L, Vanderstraeten G. Heterotopic ossification: a review. *J Rehabil Med* 2005; 37 (3): 129-36.

Vas W, Cockshott W P, Martin R F, Pai M K, Walker I. Myositis ossificans in hemophilia. *Skeletal Radiol* 1981; 7 (1): 27-31.