

# White blood cell scintigraphy for differentiation of infection and aseptic loosening

## A retrospective study of 76 painful hip prostheses

Lene Simonsen<sup>1</sup>, Anna Buhl<sup>1</sup>, Thue Oersnes<sup>2</sup> and Benn Duus<sup>2</sup>

Departments of <sup>1</sup>Clinical Physiology and Nuclear Medicine, <sup>2</sup>Orthopaedic Surgery, Bispebjerg Hospital, Copenhagen, Denmark.

Correspondence LS: lr01@bbh.regionh.dk

Submitted 06-09-18. Accepted 07-01-04

**Background** Diagnosis of an infected arthroplasty is often difficult. Fever, abnormal physical findings, radiographic changes, findings at bone scintigraphy, an elevated erythrocyte sedimentation rate, CRP, and leucocytosis are not specific enough. We evaluated the diagnostic value of white blood cell scintigraphy.

**Methods** We retrospectively reviewed 76 cases (66 patients) admitted for white blood cell scintigraphy with a clinical suspicion of infection in a hip prosthesis during the period 1995–2003. The leukocytes were labeled with <sup>99m</sup>Tc-HMPAO or with <sup>111</sup>In-oxin. Anterior and posterior views were taken of both hip joints at 3 different time points after injection: 1 h, 3 h, and 22 h. Infection was verified by means of bacteriological cultures, histopathological findings, intraoperative frozen sections, and follow-up (up to 3.5 years).

**Results** Of 76 scintigraphies, 51 were negative and 25 were positive. There were 81% true positive, 94% true negative, 6% false positive, and 19% false negative outcomes.

**Interpretation** White blood cell scintigraphy with additional late imaging is an effective tool for differentiation between loosening and infection in painful hip arthroplasty.

Accurate choice of diagnosis between aseptic loosening and infected painful hip arthroplasty is often difficult (Fitzgerald et al. 1977, Spangehl et al. 1998, Jackson and Schmalzried 2000). Markers of inflammation such as erythrocyte sedimentation

rate, C-reactive protein level, and white blood cell count are not specific for infection (Canner et al. 1984, Levitsky et al. 1991, Niskanen et al. 1996). Fluid cultures after joint aspiration have been reported, with large numbers of false positive and false negative results (Barrack and Harris 1993, Spangehl et al. 1998, 1999). In clinical practice, plain radiographs are used first to evaluate painful prostheses but they identify the cause of pain in only some of the cases (Weissman 1983, O'Neill and Harris 1984). Imaging modalities such as CT and MRI are limited by the artefacts caused by the prosthesis material (Tormanen et al. 1996).

Bone scanning using <sup>99m</sup>Tc-labeled phosphate complexes is highly sensitive but unspecific (Tehranzadeh et al. 1988, Segura et al. 2004). In histopathological analysis, the inflammatory reaction accompanying the infected prosthesis is identical to that present in aseptic loosening, with one important difference: neutrophils, usually absent in aseptic loosening, are often present in large numbers during infection (Tsukayama et al. 1996, Lonner et al. 1996). At least in theory, labeled white blood cell imaging is particularly well suited to distinguish between the inflamed aseptically loosened prosthesis (in which neutrophils are generally absent) and the infected prosthesis (in which neutrophils are present) (Palestro et al. 2002).

Table 1. Baseline patient characteristics

	Uninfected (n = 49)	Infected (n = 27)
Female <sup>a</sup>	30 (0.6)	11 (0.4)
Age <sup>b</sup>	73 (47–92)	74 (63–95)
Years since prior arthroplasty <sup>b</sup>	2.0 (0.07–14)	1.5 (0.17–14)
Primary indication <sup>a</sup>		
Osteoarthritis	18 (0.4)	7 (0.3)
Trauma	17 (0.4)	6 (0.2)
Revision	11 (0.2)	6 (0.2)
Unknown	3 (0.1)	8 (0.3)

<sup>a</sup> number (rate); <sup>b</sup> median (range)

## Patients and methods

We undertook a retrospective analysis of all white blood cell scintigraphies performed from May 1995 to September 2003 in patients with a painful hip prosthesis where loosening and/or infection were suspected. The reasons for joint replacement were osteoarthritis, trauma, and/or revision. 76 scintigraphies were performed in 66 patients. There were 62 total arthroplasties in 55 patients and 8 of these were revision implants. 32 were cemented, 8 were cementless, and 22 were hybrid (cementless acetabular and cemented femoral components). There were 14 hemiarthroplasties (only the femoral component) in 14 patients; 3 were cemented and 11 were cementless. 32 of the patients were operated. 20 of the arthroplasties were infected and 12 were loose (Table 1).

Patients with infection and without infection were similar regarding age, indication for initial implant, and time since the most recent arthroplasty. There were more men in the infected group, however, and more women in the uninfected group. Local signs of infection (erythema, warmth, edema, or fistula), elevated white blood cell count, and elevated C-reactive protein and erythrocyte sedimentation rate levels were present in both infected and uninfected patients (Table 2).

For white blood cell scintigraphy, leucocytes were isolated and labeled with <sup>111</sup>In-oxine (mean dose 36 MBq, range 14–51) (25 scintigraphies) or <sup>99m</sup>Tc-HMPAO (mean dose 628 MBq, range 359–1,092) (51 scintigraphies). Separation of white blood cells and the labeling methods were performed as described previously (Becker et al.

Table 2. Clinical and laboratory indications of infection. Values are number (rate)

	Uninfected (n = 49)	Infected (n = 27)
WBC > 9 mia/L	24 (0.5)	15 (0.6)
ESR > 40 mm/h	23 (0.5)	17 (0.6)
CRP > 10 mg/L	39 (0.8)	25 (0.9)
Local signs of infection	14 (0.3)	13 (0.5)

WBC: white blood cell count;  
ESR: erythrocyte sedimentation rate;  
CRP: C-reactive protein.

1988, Seabold et al. 1997, Datz et al. 1997). The scintigraphic images were acquired with a dual-head large-field-of-view gamma camera (Multispect; Siemens, Erlangen, Germany) equipped with low-energy parallel-hole collimators (140 keV photo-electric peak, 15% symmetrical window) for the <sup>99m</sup>Tc-HMPAO scintigraphy. In 32 cases of the 51 white blood cell scintigraphies performed with <sup>99m</sup>Tc, a <sup>99m</sup>Tc-MDP bone scintigraphy (mean dose 768 MBq) was performed with a mean of 14 days between the two studies (range 1–133). All the white blood cell scintigraphies in which the leukocytes were labeled with <sup>111</sup>In-oxine were dual-tracer studies with simultaneous <sup>99m</sup>Tc-MDP bone scintigraphy. The <sup>99m</sup>Tc-MDP (mean dose 775 MBq) was injected just after blood for labeling of the leucocytes was taken, and bone scintigraphy was performed before the labeled leucocytes were re-injected. The dual-tracer scintigraphy was done the next day (22 h after injection of the leucocytes). These scintigraphic images were acquired with medium-energy parallel-hole collimators (<sup>99m</sup>Tc: 140 keV photo-electric peak, 15% symmetrical window. <sup>111</sup>In: 247 keV photo-electric peak, 15% symmetrical window and 172 keV photo-electric peak, 15% symmetrical window). Static anterior and posterior images (256 × 256) of the hip region were performed 1 h (only <sup>99m</sup>Tc-HMPAO), 3 h, and 22 h after injection.

The scintigraphic images were evaluated by 2 experienced observers together as a consensus reading, and interpreted as being positive or negative for infection by visual analysis. The evaluation was done before the operation and independently of the surgeons. The images were considered posi-

tive for infection when periprosthetic uptake was greater than the activity in surrounding bone tissue and in the contralateral site. The scintigraphy was considered to be negative for deep infection when uptake was similar to that observed in healthy tissues of the contralateral and ipsilateral adjacent sites at any imaging time or when increased uptake that had been visible on 3-h images dramatically decreased to become scarcely visible on 22-h images. In the cases where a bone scintigraphy was also performed, the two scintigraphies were interpreted together.

The orthopedic surgeon determined the final diagnosis, based on operative findings and on bacteriological and histopathological data obtained from tissue biopsies and by follow-up (at least 1 year).

Infection was diagnosed when one or more of the following criteria were fulfilled: positive cultures from biopsy specimens, purulence at the time of surgery defined as the presence of pus identified by the surgeon, or acute inflammation consistent with infection on histopathological examination, defined as the presence of more than 10 neutrophil granulocytes per high power field in fresh frozen sections (Lonner et al. 1996). Infection was disproved in the absence of any of these criteria, and if surgery was not performed, in the absence of any suggestive sign or symptom over at least 1 year of follow-up.

On the basis of clinical parameters, we considered as being uninfected those patients for whom antibiotic treatment was not required by the end of follow-up. We considered as being infected those patients who were not operated but who required a justified antibiotic therapy with favorable clinical response during follow-up.

## Results

Of the 76 cases, 51 white blood cell scintigraphies were negative (48 patients) (Figure 1) and 25 white blood cell scintigraphies were positive (22 patients) (Table 3; Figure 2). Table 3 includes all cases; however, if only the operated hips were evaluated, the rates were similar (data not shown).

Of the true positives, 17 were diagnosed by surgery and 5 by favorable clinical response to prolonged antimicrobial therapy.

Table 3. Comparison of the scintigraphic results with operative results and clinical follow-up (n = 76)

Scintigraphic results	Number of sites	Rate
True positive	22	0.8
False positive	3	0.1
True negative	46	0.9
False negative	5	0.2
Positive predictive value (%)	88	
Negative predictive value (%)	90	
Likelihood ratio <sup>a</sup>	13	

<sup>a</sup> ([sensitivity] / 1 – [specificity])

Of the false positives, 2 were diagnosed by surgery and 1 was followed for more than 1 year without medical treatment. Of the true negatives, 11 were diagnosed by surgery and 35 were followed without any need of medical treatment for at least 1 year (up to 3.5 years) after the date of the scintigraphy. 4 of the false negatives were diagnosed to be positive by surgery and 1 by favorable clinical response to prolonged antimicrobial therapy. The organisms identified by culture in 15 of the infected hips were *Staphylococcus spp.* (n = 10), *Streptococcus spp.* (n = 3), *Enterococcus faecalis* (n = 1), and *Pseudomonas aeruginosa* (n = 1).

## Discussion

The gold standard for determining the presence of arthroplasty infection varies. We pooled all patients regardless of whether they were operated upon or not. We do not feel that it is relevant only to look into the group of patients that were operated, because it is an acceptable clinical endpoint for the outcome of treatment of arthroplasty infections that the patient did not receive any medical treatment one year after the antibiotic treatment was stopped. Furthermore, the rates of positive and negative results in the operated hips were similar to those in all cases (data not shown).

Bone scintigraphy has been the most frequently performed radionuclide study for evaluation of a painful joint replacement (Weiss et al. 1979). It is of limited value early after the operation, since it is positive for as long as 1 year after an uncomplicated hip replacement and for more than 2 years

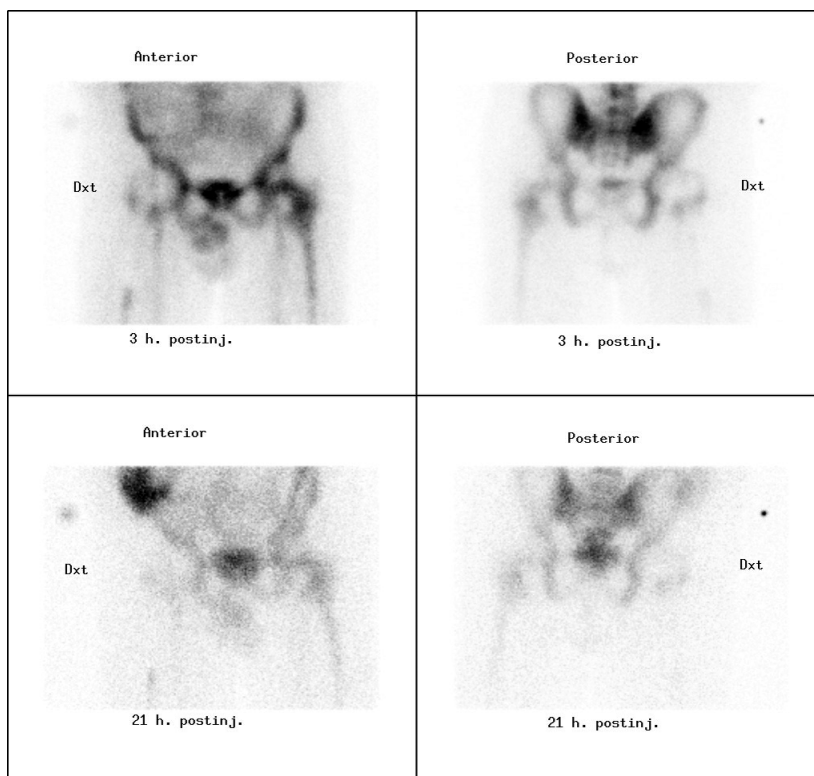


Figure 1. Normal white blood cell scintigraphy. Anterior and posterior images of the hips in a patient with an 8-month-old right-sided total hip prosthesis. The figure shows a normal distribution of  $^{99m}\text{Tc}$ -HMPAO leukocytes in the hip region. Note there is concordance in the distribution of leukocytes around the femoral component in the right hip in the images obtained 3 h and 21 h after the injection.

after insertion of a prosthesis without cement (Oswald et al. 1989). At bone scintigraphy, focally increased radionuclide uptake around the prosthesis is commonly considered to represent loosening, while diffusely increased uptake is commonly considered to represent infection (Williamson et al. 1979, Palestro and Torres 1997). However, infection may also be present in prostheses with focal uptake (Aliabadi et al. 1989, Mountford and Coakley 1989).

We found that white blood cell scintigraphy had a sensitivity and specificity of 81% and 94%, respectively. These values are similar to those in other studies (Mulamba et al. 1983, Mountford et al. 1986, Pring et al. 1986, Gomez-Luzuriaga et al. 1988, Magnuson et al. 1988, Moragas et al. 1991, Devillers et al. 1995, Wolf et al. 2001, Vanquickenborne et al. 2003, Love et al. 2004) where sensitivity and specificity were in the 75–100% range.

However, in the largest retrospective study on suspected hip prostheses comprising 116 patients, Teller et al. (2000) found a sensitivity of 64% and a specificity of 78% and concluded that routine use of white blood cell scintigraphy in combination with bone scintigraphy could not be used to differentiate between loosening and infection. Another study combined  $^{99m}\text{Tc}$  marrow scintigraphy with  $^{111}\text{In}$  leukocyte scintigraphy to detect infected total hip and knee arthroplasties and found a sensitivity of 46% and specificity of 100% (Joseph et al. 2001). In these studies, the white blood cell scintigraphies were done with  $^{111}\text{In}$ Indium. The  $^{99m}\text{Tc}$ -HMPAO has the advantage of better resolution, the possibility of doing SPECT studies, lower radiation dose, and the continuous availability of the tracer (in contrast to  $^{111}\text{In}$ Indium) (Becker et al. 1988). Recent studies of infected hip prostheses, where  $^{99m}\text{Tc}$  white blood cell scintigraphy was performed

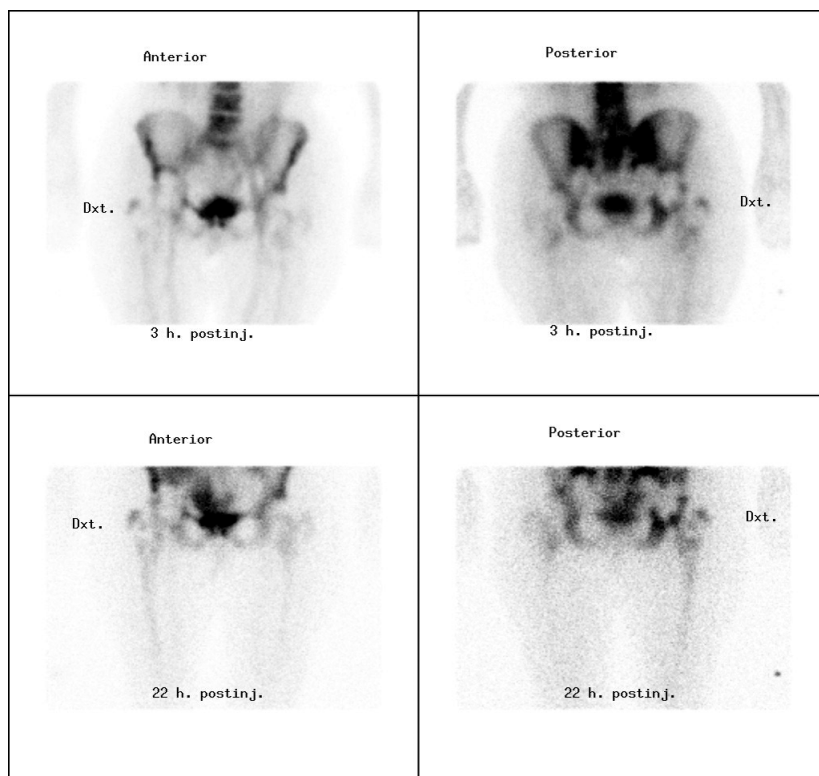


Figure 2. White blood cell scintigraphy showing an infected hip prosthesis. Anterior and posterior images of the hips in a patient with a 5-year-old right-sided total hip prosthesis. There is an abnormal distribution of  $^{99m}\text{Tc}$ -HMPAO leukocytes around the right femoral component. Note that the pathological leukocyte distribution increased from the image obtained 3 h after the injection to the image obtained 22 h after the injection.

both as planar images and SPECT, have shown that SPECT increases the sensitivity and specificity (Weon et al. 2000, Vanquickenborne et al. 2003). We used both  $^{111}\text{Indium}$  and  $^{99m}\text{Tc}$ -HMPAO.  $^{111}\text{Indium}$  labeling was routine at the beginning of the period (1995–1998). After that,  $^{99m}\text{Tc}$ -HMPAO labeling was introduced to the department and is now preferred. In 19 cases of white blood cell scintigraphy performed with  $^{99m}\text{Tc}$ -HMPAO, the primary indication was to exclude septic loosening of the hip prosthesis. Because the white blood cell scintigraphy was normal, there was no need for supplementary bone scintigraphy.

Leukocytes migrate actively from the circulation into inflamed tissue. They not only accumulate around infections but in the bone marrow as well. The distribution of hematopoietically active marrow varies, making it difficult—when the images are interpreted without comparison—to

distinguish uptake of labeled leukocytes in infection from uptake in aberrantly located but otherwise normal marrow. Moreover, the implantation of a prosthetic joint may produce additional variation in the location of normal bone marrow. This problem has been overcome by the addition of complementary bone marrow imaging performed with  $^{99m}\text{Tc}$ -sulfur colloid. Both labeled leukocytes and sulfur colloid accumulate in the bone marrow, but while bone infection stimulates leukocyte accumulation, it has been reported to reduce sulfur colloid accumulation. This makes white blood cell scintigraphy combined with bone marrow scintigraphy useful for the evaluation of the prosthetic joint, with an accuracy of more than 90% (King et al. 1990, Palestro et al. 1990, Palestro and Torres 1997, Seabold and Nepola 1999, El et al. 2004). We did not do a bone marrow scintigraphy; however, we compared the early white blood cell images

with the late images—and if there was increased leukocyte accumulation, we interpreted it as infection (Figure 2).

This technique has been shown to increase the diagnostic accuracy in other studies (Larikka et al. 2001, Dutton et al. 2004, Pelosi et al. 2004). In our study, 5 of 27 infected patients were false negative in the scintigraphy. 4 of these scintigraphies were performed with  $^{99m}\text{Tc}$ -HMPAO labeled leukocytes. We have no clear explanation for this result, though it may have been caused by a low-grade or chronic infection with a limited number of neutrophils (Glithero et al. 1993). In 2 patients, there was no clinical sign of infection during the operation. In 1 of these patients, 1 of 5 cultures from biopsy specimens was positive for *Staphylococcus aureus* and in the other patient all cultures from biopsy specimens showed the presence of *E. coli*. In 1 patient there were shady fluids during the operation, and all cultures from biopsy specimens were positive for *E. coli*. In 1 patient, there was purulence during the operation and the cultures from biopsy specimens were positive for *Streptococcus haemolytica*. 1 of the false negative patients was treated with antibiotics. During the operation there were positive signs of an abscess but the cultures from biopsy specimens were negative. The administration of antibiotics prior to scintigraphy might explain this false negative. However, Datz and Thorne (1986) have reported a large series showing no significant change in the sensitivity of white blood cell scintigraphy during antibiotic therapy. In a recent retrospective study on 210 patients with possible non-spinal osteomyelitis, Galperine et al. (2004) found that 17 patients had cold bone defects on white blood cell scintigraphy, and in all cases the site of the defect was the hip. All the patients had orthopedic hardware-related infection with *Staphylococcus*. This was the first time that cold lesions in white blood cell scintigraphy had been described in infected hip arthroplasties, although the phenomenon is well known during spinal bone infections (Palestro and Torres 1997), and it cannot be excluded that this may be an explanation for some of our false negative results.

There were 3 false positive white blood cell scintigraphies in our study. In 1 case the patients symptoms improved clinically, and the erythrocyte sedimentation rate and white blood cell count

decreased to normal levels without treatment with antibiotics before the operation, and the operation was cancelled. In 1 patient, the white blood cell scintigraphy showed marginally increased uptake at the distal point of the femoral component. During the operation, the femoral component was found to be loose but microbiological and histopathological analyses were negative. In the last patient, the white blood scintigraphy showed accumulation of leukocytes in the soft tissue around the hip and deep infection could not be excluded; however, during the operation infection was only found in the soft tissues.

One limitation of our study is that an exact diagnosis of prosthetic joint infection depends on microbiological or histopathological analysis. Surgery was performed on 32 of our 76 hips, while diagnosis was based on noninvasive assessments and clinical follow-up in the others. This was the case also in most of the studies we have referred to, however. Another important factor to be considered is that all the white blood cell scintigraphies were performed in a selected group of patients who were suspected of having deep infection.

In summary, we conclude that white blood cell scintigraphy with additional late imaging is an effective tool for differentiation between loosening and infection in painful hip arthroplasty.

#### Contributions of authors

LS: involved in the study design, data analysis, and drafting and revision of the manuscript. AB and TO: mainly involved in the study design and data collection. BD: mainly involved in the study design, and drafting and revision of the manuscript.

No competing interests declared.

Aliabadi P, Tume S S, Weissman B N, McNeil B J. Cemented total hip prosthesis: radiographic and scintigraphic evaluation. *Radiology* 1989; (173): 203-6.

Barrack R L, Harris W H. The value of aspiration of the hip joint before revision total hip arthroplasty. *J Bone Joint Surg (Am)* 1993; 75: 66-76.

Becker W, Schomann E, Fischbach W, Borner W, Gruner K R. Comparison of  $^{99m}\text{Tc}$ -HMPAO and  $^{111}\text{In}$ -oxine labelled granulocytes in man: first clinical results. *Nucl Med Commun* 1988; (9): 435-47.

- Canner G C, Steinberg M E, Heppenstall R B, Balderston R. The infected hip after total hip arthroplasty. *J Bone Joint Surg (Am)* 1984; 66: 1393-9.
- Datz F L, Thorne D A. Effect of antibiotic therapy on the sensitivity of indium-111-labeled leukocyte scans. *J Nucl Med* 1986; 27: 1849-53.
- Datz F L, Seabold J E, Brown M L, Forstrom L A, Greenspan B S, McAfee J G, Palestro C J, Schauwecker D S, Royal H D. Procedure guideline for technetium-99m-HMPAO-labeled leukocyte scintigraphy for suspected infection/inflammation. Society of Nuclear Medicine. *J Nucl Med* 1997; 38: 987-90.
- Devillers A, Moisan A, Jean S, Arvieux C, Bourguet P. Technetium-99m hexamethylpropylene amine oxime leukocyte scintigraphy for the diagnosis of bone and joint infections: a retrospective study in 116 patients. *Eur J Nucl Med* 1995; 22: 302-7.
- Dutton J A, Bird N J, Skehan S J, Peters A M. Evaluation of a 3-hour indium-111 leukocyte image as a surrogate for a technetium-99m nanocolloid marrow scan in the diagnosis of orthopedic infection. *Clin Nucl Med* 2004; 29: 469-74.
- El E, I, Blondet C, Moullart V, Saidi L, Havet E, Mertl P, Canarelli B, Schmit J L, Meyer M E. The usefulness of 99mTc sulfur colloid bone marrow scintigraphy combined with 111In leukocyte scintigraphy in prosthetic joint infection. *Nucl Med Commun* 2004; 25: 171-5.
- Fitzgerald R H, Jr., Nolan D R, Ilstrup D M, Van Scoy R E, Washington J A, Coventry M B. Deep wound sepsis following total hip arthroplasty. *J Bone Joint Surg (Am)* 1977; 59: 847-55.
- Galperine T, Dutronc H, Lafarie S, Neau D, Merino B, Cipriano G, Ragnaud J M, Fernandez P, Basse-Cathalinat B, Dupon M. Cold bone defect on granulocytes labelled with technetium-99m-HMPAO scintigraphy: significance and usefulness for diagnosis and follow-up of osteoarticular infections. *Scand J Infect Dis* 2004; 36: 209-12.
- Glithero P R, Grigoris P, Harding L K, Hesselwood S R, McMinn D J. White cell scans and infected joint replacements. Failure to detect chronic infection. *J Bone Joint Surg (Br)* 1993; 75: 371-4.
- Gomez-Luzuriaga M A, Galan V, Villar J M. Scintigraphy with Tc, Ga and In in painful total hip prostheses. *Int Orthop* 1988; 12: 163-7.
- Jackson W O, Schmalzried T P. Limited role of direct exchange arthroplasty in the treatment of infected total hip replacements. *Clin Orthop* 2000; (381): 101-5.
- Joseph T N, Mujtaba M, Chen A L, Maurer S L, Zuckerman J D, Maldjian C, Di Cesare P E. Efficacy of combined technetium-99m sulfur colloid/indium-111 leukocyte scans to detect infected total hip and knee arthroplasties. *J Arthroplasty* 2001; 16: 753-8.
- King A D, Peters A M, Stuttle A W, Lavender J P. Imaging of bone infection with labelled white blood cells: role of contemporaneous bone marrow imaging. *Eur J Nucl Med* 1990; 17: 148-51.
- Larikka M J, Ahonen A K, Junila J A, Niemela O, Hamalainen M M, Syrjala H P. Extended combined 99mTc-white blood cell and bone imaging improves the diagnostic accuracy in the detection of hip replacement infections. *Eur J Nucl Med* 2001; 28: 288-93.
- Levitsky K A, Hozack W J, Balderston R A, Rothman R H, Gluckman S J, Maslack M M, Booth R E, Jr. Evaluation of the painful prosthetic joint. Relative value of bone scan, sedimentation rate, and joint aspiration. *J Arthroplasty* 1991; 6: 237-44.
- Lonner J H, Desai P, Dicesare P E, Steiner G, Zuckerman J D. The reliability of analysis of intraoperative frozen sections for identifying active infection during revision hip or knee arthroplasty. *J Bone Joint Surg (Am)* 1996; 78: 1553-8.
- Love C, Marwin S E, Tomas M B, Krauss E S, Tronco G G, Bhargava K K, Nichols K J, Palestro C J. Diagnosing infection in the failed joint replacement: a comparison of coincidence detection 18F-FDG and 111In-labeled leukocyte/99mTc-sulfur colloid marrow imaging. *J Nucl Med* 2004; 45: 1864-71.
- Magnuson J E, Brown M L, Hauser M F, Berquist T H, Fitzgerald R H, Jr., Klee G G. In-111-labeled leukocyte scintigraphy in suspected orthopedic prosthesis infection: comparison with other imaging modalities. *Radiology* 1988; 168: 235-9.
- Moragas M, Lomena F, Herranz R, Garcia A, Piera C, Muxi A, Bassa P, Catafau A, Pavia A, Setoain J. 99Tcm-HMPAO leukocyte scintigraphy in the diagnosis of bone infection. *Nucl Med Commun* 1991; 12: 417-27.
- Mountford P J, Coakley A J. Role of technetium-99m phosphonate bone and indium-111 leukocyte scanning for detecting the infected hip prosthesis. *J Nucl Med* 1989; 30: 562-3.
- Mountford P J, Hall F M, Wells C P, Coakley A J. 99Tcm-MDP, 67Ga-citrate and 111In-leucocytes for detecting prosthetic hip infection. *Nucl Med Commun* 1986; 7: 113-20.
- Mulamba L, Ferrant A, Leners N, de Nayer P, Rombouts J J, Vincent A. Indium-111 leukocyte scanning in the evaluation of painful hip arthroplasty. *Acta Orthop Scand* 1983; 54: 695-7.
- Niskanen R O, Korkala O, Pammo H. Serum C-reactive protein levels after total hip and knee arthroplasty. *J Bone Joint Surg (Br)* 1996; 78: 431-3.
- O'Neill D A, Harris W H. Failed total hip replacement: assessment by plain radiographs, arthrograms, and aspiration of the hip joint. *J Bone Joint Surg (Am)* 1984; 66: 540-6.
- Oswald S G, Van Nostrand D, Savory C G, Callaghan J J. Three-phase bone scan and indium white blood cell scintigraphy following porous coated hip arthroplasty: a prospective study of the prosthetic tip. *J Nucl Med* 1989; 30: 1321-31.
- Palestro C J, Torres M A. Radionuclide imaging in orthopedic infections. *Semin Nucl Med* 1997; 27: 334-45.
- Palestro C J, Kim C K, Swyer A J, Capozzi J D, Solomon R W, Goldsmith S J. Total-hip arthroplasty: periprosthetic indium-111-labeled leukocyte activity and complementary technetium-99m-sulfur colloid imaging in suspected infection. *J Nucl Med* 1990; 31: 1950-5.
- Palestro C J, Kipper S L, Weiland F L, Love C, Tomas M B. Osteomyelitis: diagnosis with (99m)Tc-labeled anti-granulocyte antibodies compared with diagnosis with (111)In-labeled leukocytes--initial experience. *Radiology* 2002; 223: 758-64.

- Pelosi E, Baiocco C, Pennone M, Migliaretti G, Varetto T, Maiello A, Bello M, Bisi G.  $^{99m}\text{Tc}$ -HMPAO-leukocyte scintigraphy in patients with symptomatic total hip or knee arthroplasty: improved diagnostic accuracy by means of semiquantitative evaluation. *J Nucl Med* 2004; 45: 438-44.
- Pring D J, Henderson R G, Keshavarzian A, Rivett A G, Krausz T, Coombs R R, Lavender J P. Indium-granulocyte scanning in the painful prosthetic joint. *AJR Am J Roentgenol* 1986; 147: 167-72.
- Seabold J E, Nepola J V. Imaging techniques for evaluation of postoperative orthopedic infections. *Q J Nucl Med* 1999; 43: 21-8.
- Seabold J E, Forstrom L A, Schauwecker D S, Brown M L, Datz F L, McAfee J G, Palestro C J, Royal H D. Procedure guideline for indium-111-leukocyte scintigraphy for suspected infection/inflammation. Society of Nuclear Medicine. *J Nucl Med* 1997; 38: 997-1001.
- Segura A B, Munoz A, Brulles Y R, Hernandez Hermoso J A, Diaz M C, Bajen Lazaro M T, Martin-Comin J. What is the role of bone scintigraphy in the diagnosis of infected joint prostheses? *Nucl Med Commun* 2004; 25: 527-32.
- Spanghehl M J, Younger A S, Masri B A, Duncan C P. Diagnosis of infection following total hip arthroplasty. *Instr Course Lect* 1998; 47: 285-95.
- Spanghehl M J, Masri B A, O'Connell J X, Duncan C P. Prospective analysis of preoperative and intraoperative investigations for the diagnosis of infection at the sites of two hundred and two revision total hip arthroplasties. *J Bone Joint Surg (Am)* 1999; 81: 672-83.
- Tehranzadeh J, Gubernick I, Blaha D. Prospective study of sequential technetium-99m phosphate and gallium imaging in painful hip prostheses (comparison of diagnostic modalities). *Clin Nucl Med* 1988; 13: 229-36.
- Teller R E, Christie M J, Martin W, Nance E P, Haas D W. Sequential indium-labeled leukocyte and bone scans to diagnose prosthetic joint infection. *Clin Orthop* 2000; (373): 241-7.
- Tormanen J, Tervonen O, Koivula A, Junila J, Suramo I. Image technique optimization in MR imaging of a titanium alloy joint prosthesis. *J Magn Reson Imaging* 1996; 6: 805-11.
- Tsukayama D T, Estrada R, Gustilo R B. Infection after total hip arthroplasty. A study of the treatment of one hundred and six infections. *J Bone Joint Surg (Am)* 1996; 78: 512-23.
- Vanquickenborne B, Maes A, Nuyts J, Van Acker F, Stuyck J, Mulier M, Verbruggen A, Mortelmans L. The value of (18)FDG-PET for the detection of infected hip prosthesis. *Eur J Nucl Med Mol Imaging* 2003; 30: 705-15.
- Weiss P E, Mall J C, Hoffer P B, Murray W R, Rodrigo J J, Genant H K.  $^{99m}\text{Tc}$ -methylene diphosphonate bone imaging in the evaluation of total hip prostheses. *Radiology* 1979; 133: 727-9.
- Weissman B N. The radiology of total joint replacement. *Orthop Clin North Am* 1983; 14: 171-91.
- Weon Y C, Yang S O, Choi Y Y, Shin J W, Ryu J S, Shin M J, Lee S H, Lee H K. Use of Tc-99m HMPAO leukocyte scans to evaluate bone infection: incremental value of additional SPECT images. *Clin Nucl Med* 2000; 25: 519-26.
- Williamson B R, McLaughlin R E, Wang G W, Miller C W, Teates C D, Bray S T. Radionuclide bone imaging as a means of differentiating loosening and infection in patients with a painful total hip prosthesis. *Radiology* 1979; 133: 723-5.
- Wolf G, Aigner R M, Schwarz T. Diagnosis of bone infection using  $^{99m}\text{Tc}$ -HMPAO labelled leukocytes. *Nucl Med Commun* 2001; 22: 1201-6.