

No difference in migration or wear between cemented low-profile cups and standard cups

A randomized radiostereographic study of 53 patients over 3 years

Lars Palm¹, Jörgen Olofsson², Stig-Eric Åström², and Ingemar Ivarsson¹

Departments of Orthopaedic Surgery, ¹University Hospital Linköping, ²Central Hospital Norrköping, Sweden

Correspondence LP: lars.palm@lio.se

Submitted 07-01-27. Accepted 07-02-12

Background Minor design changes may cause major changes in implant performance. Thus, as part of a stepwise introduction of a new low-profile cup, we performed a randomized trial comparing it to a well-documented standard cup.

Patients and methods 60 patients, stratified according to sex, weight, and age, underwent cemented total hip arthroplasty using a Lubinus SP2 stem with ceramic head and were randomized to either the new low-profile Lubinus Flanged Anti-Luxation cup (FAL) or the Lubinus Standard Eccentric cup (Standard). 7 patients were excluded and 53 (28 FAL) were evaluated at 3, 6, 12, and 36 months postoperatively. Primary outcome variables, cup migration (MTPM), and wear (total 3-dimensional femoral head penetration) were measured with radiostereometry (RSA). Clinical outcome was evaluated with the western Ontario and McMaster osteoarthritis index (Womac) and the visual analog pain score (VAS).

Results We found no difference in migration between the FAL and Standard cups. There was no difference in wear between the two cups and there was no correlation between wear and migration. 3 cups (2 FAL and 1 Standard) showed continuous migration of a magnitude that indicated an increased risk of early loosening. Clinical outcome was excellent, without any difference between the 2 groups.

the incidence of cement-bone radiolucency and wear (Sarmiento et al. 1990) and lack of containment may adversely influence long-term stability (Laursen et al. 1998). The low-profile geometry also allows a larger range of free motion before impingement between the neck of the femoral component and the rim of the cup occurs. Such neck-to-rim contact can cause local abrasive wear of the cup, dislocation of the head, and might also influence the long-term stable fixation of the cup. On the other hand, the low-profile geometry implies a lesser degree of containment of the prosthetic head within the cup, thereby making it susceptible to instability—or ultimately dislocation in the case of malpositioning.

At the time of clinical introduction of a new low-profile cup, the Lubinus Flanged Anti-Luxation cup (FAL), a report of increased migration and wear of another low-profile design—the SHP cup—was published (Nivbrant et al. 1999). As a part of a careful stepwise introduction of this new implant, we therefore decided to investigate how the FAL cup compared to the well-documented Lubinus Eccentric cup (referred to here as Standard) (Link Gmbh & Co, Hamburg, Germany) in terms of migration and wear.

Low-profile acetabular components allow a higher degree of containment within the bony acetabulum, especially in shallow or dysplastic acetabuli. Complete bony containment of cups may reduce

Patients and methods

Study design

The study was designed as a prospective randomized controlled clinical trial. Inclusion criteria

Table 1. Patient data

	FAL		Standard	
	median	range	median	range
Age, years	70	60–80	69	60–78
Weight, kg	80	54–99	77	54–103
Female / Male	14 / 14		14 / 11	

were patients between 60 and 80 years of age who were awaiting THR for primary osteoarthritis and who, after being given written information, were willing to participate in the trial. Exclusion criteria were: any known malignancy, rheumatoid arthritis, previous hip fracture, or contralateral hip prosthesis. Patients with acetabular protrusion or dysplasia were excluded due to the risk of random allocation to an inappropriate acetabular implant.

Power analysis indicated a sample size of 25 patients in each group in order to give a 95% probability of detecting a 0.2-mm difference in cup migration between groups, a difference that could be considered clinically relevant. To safeguard against unforeseen exclusions, 10 additional patients, i.e. a total of 60 patients, were included. The local ethics committee approved the study design.

To ensure a similar distribution of confounding factors between groups, we used a matched-pair design in the randomization procedure. Patients were included and subsequently paired according to 3 matching variables; sex, body weight in 10-kg intervals, and age in 5-year intervals. Within each matched pair, one patient was randomized to either the Standard cup or FAL cup by flip of a coin and the other patient received the alternative acetabular implant.

7 patients were excluded; 2 died prior to 1 year of follow-up and 1 suffered a postoperative infection that necessitated further surgical intervention. 4 patients were excluded due to unacceptably high condition number (CN > 150) and/or a mean error of rigid body fitting (ME > 0.3) precluding reliable RSA analysis (Börlin et al. 2002). Thus, 28 FAL patients and 25 Standard patients were available for analysis (Table 1).

Implants

The femoral component, Lubinus SP-2, is an anatomically shaped CoCr stem with collar and matte




Figure 1. The Standard cup and the FAL cup.

surface finish. We used a 126° CCD angle and 28-mm aluminium oxide ceramic heads (BioloX; Link GmbH & Co, Hamburg, Germany) for all patients. The acetabular components, both Standard and FAL, are made from identical UHMW polyethylene, and have similar vertical and horizontal grooves on the back.

Both cup types are sterilized by Gamma irradiation (27 kGy) in an oxygen-reduced environment. The principal difference lies in the lower-profile design of the FAL cup, which has a 2.5-mm circular flange for centralization and cement pressurization, and 2.5-mm pegs for uniform cement mantle thickness. The opening of the FAL cup is directed 70° from the face of the cup to reduce the risk of dislocation, while the Standard cup opening is orthogonal to the face of the cup—but eccentric, to permit the use of thicker polyethylene cranially (Figure 1).

Surgical procedure

Implantation of cups was done according to the manufacturers' recommendations, using third-generation cementing technique with pulsatile lavage and pressurization of the gentamycin-containing cement (Palacos) before insertion of the cup. The size of the Standard cups was 2 mm smaller than that of the last reamer, giving a 1-mm cement mantle. The size of the FAL cups was equal to that of the last reamer in order to make the circular flange fit into the reamed cavity, which gives a 2.5-mm cement mantle. Between 6 and 8 tantalum markers (1 mm in diameter) were inserted into the periacetabular bone, and a further 6–8 markers (0.8 mm) were inserted into the cup (Table 2).

Table 2. Cup size and position

	FAL		Standard	
	median	range	median	range
Cup size, mm	54	48–56	52	46–56
Anteversión (°)	17	-3–34	17	2–29
Lateral inclination (°)	45	32–60	44	28–60

THR was performed under spinal anesthesia and all patients received prophylactic antibiotic treatment: Cloxacillin 1 g × 3 intravenously on the day of surgery and antithrombotic treatment (Dalteparin 5,000 U daily for 1 week).

Data collection

The RSA procedure was performed as described by Kärrholm et al. (1997). Radiographic films were scanned and digitized using Digtale version 1.1 software, and for analysis UmRSA 4.1 software (RSA Biomedical Innovations AB, city, Sweden) was used. RSA examinations were done within the first postoperative week, after 3 months, 6 months, 1 year, and 3 years. Double examinations were performed postoperatively and at 3 years.

Based on 100 double examinations, the standard error of measurements for our RSA equipment was calculated ($SE = SD \times (\Delta \text{migration}) / \sqrt{2}$) where ($\Delta \text{migration}$) represents the difference between the two double examinations.

The 95% confidence intervals for single measurement were calculated as $1.96 \times SE$ of measurement (Table 3). The clinical result was evaluated with Womac and VAS, at rest and during activity, preoperatively and at 3, 6, and 12 months postoperatively.

Statistics

Cup migration as MTPM (maximum total point motion) and wear (total, three-dimensional vector of femoral head penetration) at 1 and 3 years served as our primary outcome variables. Student's t-test was used for comparisons between groups. Other results are presented as group average values with SD and upper/lower 95% confidence limits of the difference between groups.

Results

Migration

There was no difference in MTPM values between the two groups ($p = 0.7$ and $p = 0.8$ at 1 and 3 years, respectively) (Figure 2; Table 4). MTPM values exceeding mean + 2 SD were seen in 3 cups (2 FAL, 1 Standard). Analysis of translations along and rotations around the x- (medial-lateral), y- (proximal-distal) and z- (ventral-dorsal) axis showed minimal differences between the groups (Table 5). Both cup types displayed the same pattern of translation

Table 3. Measurement errors

	Translation along			Rotation around		
	X	Y	Z	X	Y	Z
SE of measurement	0.04	0.03	0.06	0.12	0.12	0.09
95% CI for single measurement	0.07	0.06	0.11	0.24	0.23	0.17

Table 4. MTPM over time, mm

	FAL (n = 28)		Standard (n = 25)		Difference of means	95% CI of difference
	mean	SD	mean	SD		
3	0.40	0.25	0.46	0.33	-0.06	-0.22–0.10
6	0.59	0.46	0.55	0.48	0.04	-0.21–0.29
12	0.65	0.58	0.60	0.51	0.05	-0.24–0.34
36	0.73	0.66	0.77	0.57	-0.04	-0.37–0.30

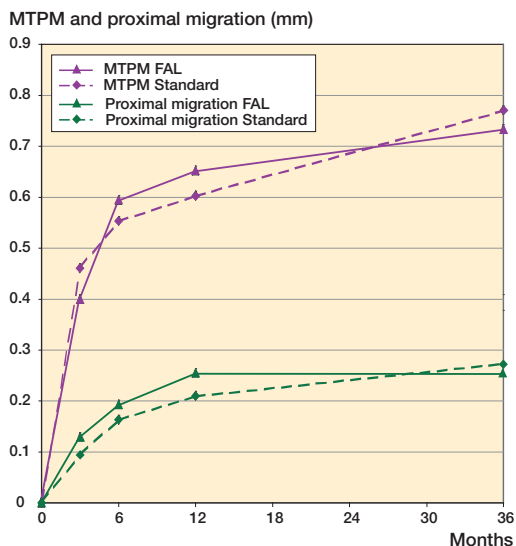


Figure 2. MTPM and proximal migration of FAL (n = 28; solid line) and Standard (n = 25; dashed line).

and rotation along the x-, y- and z-axis at 1 and 3 years, i.e. lateral, proximal, and posterior translations, and posterior tilt, retroversion, and increased

lateral inclination. The medial translation was the only individual parameter where the 95% CI did not include the zero value, thus suggesting a difference between groups. However, this difference of 0.15 mm, which may well be a random finding due to multiple comparisons, was small—and was therefore of no or limited clinical importance.

The 3 cups that showed increased MTPM values (see above) also showed increased proximal migration: in 2 cups exceeding mean + 2 SD and in 1 cup close to mean + 2 SD. The range of proximal migration of these 3 cups was 0.85–1.75 mm.

Wear

The wear measured was no different between the two cups (p = 0.9 and p = 0.7 at 1 and 3 years, respectively); nor was there any difference in femoral head penetration—in the medial, proximal, or posterior direction (Table 6). We found the progression of wear between 1 and 3 years to be negligible. Two cups, one of each type, showed wear exceeding mean + 2 SD, with range 0.62–0.88 mm.

Table 5. Migration at 1 year and 3 years

	FAL (n = 28)		Standard (n = 25)		Difference of means	95% CI of difference
	mean	SD	mean	SD		
<i>1-year migration</i>						
X-translation, mm, medial+ / lateral -	-0.08	0.18	-0.10	0.19	0.02	-0.01–0.12
Y-translation, mm, proximal+ / distal -	0.26	0.26	0.21	0.29	0.05	-0.10–0.19
Z-translation, mm, ventral+ / dorsal -	-0.02	0.20	-0.06	0.33	0.04	-0.11–0.19
X-rotation (°) anterior tilt + / posterior tilt -	-0.07	0.47	-0.02	0.56	-0.05	-0.33–0.23
Y-rotation (°) anteversion + / retroversion -	-0.05	0.33	-0.10	0.65	0.05	-0.23–0.34
Z-rotation (°) increase inclination + / decrease -	0.29	0.52	0.18	0.27	0.11	-0.11–0.33
<i>3-year migration</i>						
X-translation, mm, medial+ / lateral -	-0.01	0.23	-0.16	0.19	0.15	0.04–0.27
Y-translation, mm, proximal+ / distal -	0.25	0.35	0.27	0.35	-0.02	-0.21–0.17
Z-translation, mm, ventral+ / dorsal -	-0.01	0.29	-0.09	0.35	0.09	-0.08–0.27
X-rotation (°) anterior tilt + / posterior tilt -	-0.14	0.51	0.00	0.58	-0.14	-0.43–0.16
Y-rotation (°) anteversion + / retroversion -	-0.06	0.39	-0.11	0.65	0.05	-0.24–0.34
Z-rotation (°) increase inclination+ / decrease -	0.19	0.69	0.25	0.51	-0.06	-0.38–0.27

Table 6. Wear (mm) at 1 year and 3 years

	FAL (n = 28)		Standard (n = 25)		Difference of means	95% CI of difference
	mean	SD	mean	SD		
1 year	0.27	0.10	0.27	0.10	0.00	-0.04–0.04
3 years	0.28	0.12	0.27	0.16	0.02	-0.06–0.09

Table 7. Clinical results

	FAL		Standard	
	median	range	median	range
WOMAC				
preoperatively	36	17–75	34	9–64
3 months	83	52–100	69	36–100
6 months	84	56–99	83	45–100
12 months	85	60–100	83	46–100
VAS pain: at rest				
preoperatively	38	0–72	42	0–84
3 months	6	0–22	4	0–41
6 months	2	0–20	5	0–31
12 months	0	0–11	2	0–35
VAS pain: during activity				
preoperatively	70	38–98	71	21–100
3 months	12	0–38	17	0–63
6 months	7	0–36	10	0–49
12 months	4	0–36	10	0–56

Clinical

The overall clinical result was excellent in both groups (Table 7).

Discussion

At 1 and 3 years after implantation, we found no difference of clinically important magnitude in our primary outcome variables, MTPM and wear, for the Lubinus FAL cup and the Lubinus Standard cup.

Certain design features have long been considered prerequisites for successful cup fixation. These include grooves to improve fixation between cup and cement, spacers to enable a concentric cement mantle, and a flange to provide concentric placement and cement pressurization (Oh et al. 1984). In clinical practice many cup designs adhere to these concepts, which seem to work since cup loosening almost invariably occurs not between cup and cement, but between cement and bone. However, the importance of a concentric cement mantle, as well as the benefit of spacers to achieve it, is controversial. Sandhu et al. (2006) reported that even with spacers, the preferred concentric cement mantle is seldom attained while Faris et al. (2006) concluded that spacers did give a more uniform cement mantle but were associated with a higher initial failure rate. The new FAL cup comprises all

three of the above-mentioned features, while the Standard cup works well (historically) without the flange.

The mean proximal migration seen in our study is comparable to those in previous studies of the Lubinus cup: proximal migration of 0.2 mm at 2 years (Nivbrant et al. 1999) and 0.27 mm at 5 years (Nivbrant et al. 2001). At 3 years, we found that 3 cups (2 FAL and 1 Standard) showed appreciable migration, which increased with time. Although tolerable limits of early migration of cemented cups in relation to increased risk of clinical failure remain to be clearly established (Kärrholm et al. 1997), we believe that the magnitude of migration of these 3 cups indicates an increased risk of early loosening. Excessive wear was not seen in any of these cups.

Wear rates of 0.27–0.30 mm at 2 years have been reported for Lubinus cups with CoCr heads (Nivbrant et al. 1999, Digas et al. 2003) and 0.39 mm at 5 years with Biolox heads (Nivbrant et al. 2001). Although 2 cups in our material displayed wear in excess of the respective group mean + 2 SD, the mean wear rate was even lower than what has been previously reported. We found no correlation between excessive wear and increased migration, a finding indicating that the cause of migration and loosening also involves factors other than polyethylene wear.

In summary, 3 years after implantation the new low-profile FAL cup performs as well as the Standard eccentric Lubinus cup in terms of migration and wear. Based on our results, we believe that the FAL cup is safe to use when acetabular anatomy makes a low-profile implant a suitable option.

Contributions of authors

LP: study plan and design, recruitment of patients and surgery, data collection, interpretation, and preparation of article. SÅ, JO: recruitment of patients and surgery. II: study plan and design, recruitment of patients and surgery, interpretation of data, and manuscript review.

We thank Ulf Kallander for RSA analysis.

Funding

Waldemar Link GmbH & Co financed the 1- and 3-year RSA

- investigations. The sponsor had no role in the design of the study, in the collection, analysis, and interpretation of data, and in the drafting and revision of the manuscript.
- Börlin N, Thien T, Kärrholm J. The precision of radiostereometric measurements. Manual vs. digital measurements. *J Biomech* 2002; 35: 69-79.
- Digas G, Thanner J, Nivbrant B, Röhrl S, Ström H, Kärrholm J. Increase in early polyethylene wear after sterilization with ethylene oxide: radiostereometric analyses of 201 total hips. *Acta Orthop Scand* 2003; 74 (5): 531-41.
- Faris P, Ritter M, Keating M, Thong A, Davis K, Meding J. The cemented all-polyethylene acetabular cup: Factors affecting survival with emphasis on the integrated polyethylene spacer. *J Arthroplasty* 2006; 21 (2): 191-8.
- Kärrholm J, Herberts P, Hultmark P, Malchau H, Nivbrant B, Thanner J. Radiostereometry of hip prostheses: Review of methodology and clinical results. *Clin Orthop* 1997; [344]: 94-110.
- Laursen J O, Petersen B, Mossing N B. The Richards Series 2 total hip prosthesis: a 13-year study and radiographic evaluation. *Orthopedics* 1998; 21 (3): 277-82.
- Nivbrant B, Kärrholm J, Soderlund P. Increased migration of the SHP prosthesis: radiostereometric comparison with the Lubinus SP2 design in 40 cases. *Acta Orthop Scand* 1999; 70 (6): 569-77.
- Nivbrant B, Kärrholm J, Röhrl S, Hassander H, Wesslén B. Bone cement with reduced proportion of monomer in total hip arthroplasty. Preclinical evaluation and randomized study of 47 cases with 5 years' follow-up. *Acta Orthop Scand* 2001; 72 (6): 572-84.
- Oh I, Sanders T, Treharne R. Acetabular cup groove and pod design and its effect on cement fixation in total hip arthroplasty. *Clin Orthop* 1984; (189): 308-12.
- Sandhu H, Martin W, Bischay M, Pozo L. Acetabular cement mantles and component position. Are we achieving "ideal results" *J Arthroplasty* 2006; 21 (6): 841-5.
- Sarmiento A, Ebramzadeh E, Gogan W J, McKellop H A. Cup containment and orientation in cemented total hip arthroplasties. *J Bone Joint Surg (Br)* 1990; 72 (6): 996-1002.