

Bone regeneration 6 years after impaction bone grafting

A PET analysis

Gösta Ullmark¹, Jens Sörensen¹, Bengt Långström¹ and Olle Nilsson²

Departments of Orthopedics, ¹Länssjukhuset, SE-801 87 Gävle, ²Uppsala University Hospital, SE-751 85 Uppsala, Sweden

Correspondence GU: gosta.ullmark@lg.se

Submitted 06-. Accepted 06-10-30

Background Impacted morselized bone allograft in revision total hip arthroplasty for prosthetic loosening has gained widespread clinical use during the last decades. The clinical results are good but little is known about the bone regeneration in the graft.

Patients and methods 5 patients were revised with impaction of morselized frozen allograft and a cemented total hip arthroplasty (THA) due to loosening and osteolysis of a primary THA. We used positron emission tomography ([¹⁸F]-fluoride PET) to produce quantitative images of new bone formation in the allograft surrounding the femur stem 6 years after surgery.

Results The 5 patients had previously been analyzed by [¹⁸F]-fluoride PET during the first year after surgery (Sörensen et al. 2003). During the first year, bone formation proceeded through the graft layer and reached the cement layer surrounding the femoral stems. The clinical and radiographic results were excellent at 6 years. PET analyses at 6 years showed that the bone metabolism was significantly reduced in most areas of the proximal femur, compared to the elevated activity during the first year after surgery, and also normalized compared to the contralateral healthy femur. Graft bone metabolism distal to the stem tip remained slightly increased. Small patchy areas of increased uptake remained along the proximal femoral stem, probably reflecting small volumes of fibrous healing.

Interpretation The metabolism of the allografted bone had normalized compared to native bone, indicating full regeneration throughout the graft—and a good long-term prognosis for implant fixation.

The concept of impacted morselized bone allograft in revision total hip arthroplasty for prosthetic loosening has gained widespread clinical use during the last 2 decades. The clinical results are good (Gie et al. 1993, Elting et al. 1995, Kärrholm et al. 1999, Mickhail et al. 1999, Ullmark et al. 2002). Little is known about the physiological events that take place in a graft bed after surgery. Some morphological investigations of graft material originating from biopsies and autopsies have been reported (Nelissen et al. 1995, Linder 2000, Ullmark and Obrant 2002). To our knowledge, only 2 reports have been published concerning the metabolism taking place in a human bed of morselized bone graft (Piert et al. 1999, Sörensen et al. 2003). Using the PET technique, Sörensen et al. reported swift bone healing during the first year after surgery. In the present study, we report the results of analysis of the same patients by PET 6 years after surgery.

Patients and methods

Patients

5 patients (3 females) with ages ranging from 54 to 77 years at revision were included in the study. All 5 were treated with a revision THA and impaction of morselized bone allograft due to osteolysis resulting from loosening of a primary THA. Loss of bone stock was graded as II–IV according to the Endo Klinik classification (Engelbrecht and Heinert 1987). The primary THA had been performed

due to osteoarthritis in 4 patients and fracture sequelae in 1. One surgeon (GU) who was well acquainted with the surgical technique performed all surgical procedures. The acetabular component was also revised in 4 of the patients, with impaction grafting in 3.

Bone graft

Bone grafts were taken from fresh-frozen femoral heads harvested at primary arthroplasty for hip osteoarthritis, and stored at -80°C . The bone was morselized with a Howex milling machine (Gävle, Sweden), producing chips of sizes up to a maximum of $2 \times 4 \times 5$ mm. The milled bone chips were mainly defatted by rinsing in warm saline solution before impaction in the femoral revision cavern.

Surgical technique

Dedicated impaction instruments containing small holes aimed at further fat reduction of the graft were used. Through these holes in the phantom, a blood clot containing thrombocytes would be built up inside the graft bed in its impacted state. Cemented, matte (surface Ra 1.5 μm), 170 mm-long and collared Lubinus SP II stems (Waldemar Link, Hamburg, Germany) were used. The method has been described in detail previously (Sørensen et al. 2003).

Radiographic and clinical examinations

Plain radiographs, anterior and lateral views, were taken postoperatively at 15–24 months and 5–6 years after surgery. The radiographs were analyzed and interpreted by consensus between one of the authors (GU) and a radiologist. Clinical examination was performed preoperatively, at 15–24 months, and 6 years after surgery. The Charnley modification of the Merle d'Aubigné-Postel classification was used (Charnley 1979).

PET analyses

Scanning

We used a Siemens/CTI Exact HR plus scanner (Siemens/CTI, Knoxville, TN). The HR Plus has a FOV of 15 cm, yielding 63 transaxial slices. Patients were placed in the supine position on the camera bed. The legs were fixed in place using a

vacuum cushion. For injection of tracer, a venous catheter was inserted in an antecubital or dorsal hand vein. 30 min after intravenous injection of 200 MBq $[^{18}\text{F}]$ -fluorine, a section of the body from the knees to the upper pelvis was scanned in 2D whole-body mode. Emission scanning started from the knees (5 min per 15-cm bed position) and moved proximally to cover the entire hip prosthesis area in one session. Transmission scanning for attenuation correction was performed after completing the emission acquisition. The protocol was constructed to permit a semiquantitative comparison of the current data with historic data from the same patients during the first year after surgery, and on all occasions the stem area was then scanned from 35–50 min after tracer injection.

Image processing and analysis

All emission scans were corrected for attenuation, scatter, and decay, and reconstructed by a process of filtered back-projection. The analysis method has been described in detail elsewhere (Sørensen et al. 2003). Briefly, regions of interest (ROIs) were placed graphically according to Gruen zones, and standardized uptake values (SUVs) from these ROIs were calculated by the formula:

$$\text{SUV of tissue} = \text{activity in tissue (Bq/mL)} \times \text{body weight (g)} / \text{total injected dose (Bq)}$$

By setting average body density to 1 g/mL, this expression gives a unitless value of the regional tissue activity in proportion to the average activity/mL of the entire body. “Tip” corresponds to Gruen zone IV; “Mid” corresponds to Gruen zones III and V (i.e. 5 cm above the tip of the stem). Average values of the contralateral healthy femur are presented as “reference” in the text.

Statistics

Numerical results are presented as mean (SD), unless otherwise stated. Regional SUV measurements at 6 years were compared to the same region at 1 year, as well as to the reference region at the same time. Where applicable, differences in mean values were assessed with non-parametric Wilcoxon matched pairs test.

Table 1. Clinical and radiographic findings

Case	1	2	3	4	5
Radiographic finding					
cortical healing (Gruen zone)	IV	VII			V
new trabecular formation (Gruen zone)	I–VII	VI–VII		IV–V	VI
Clinical results ^a	10/18/18	9/16/18	14/17/17	12/18/18	13/18/18

^a Merle d'Aubigné-Postel score (1–18): (preoperatively / at 1 year / at 6 years).

Results

Clinical results

The clinical outcomes were excellent in 4 patients and good in 1 patient, who had slight residual pain diagnosed as tendonitis (Table).

Radiographic results

No subsidence was seen for any of the femoral stems on plain radiographs. No radiolucent lines had developed around the stems or cement mantles. Furthermore, new trabecular bone formation and cortical healing had occurred since the evaluation 15–24 months after surgery. The bone structure of the transplanted areas had normalized further (Table). A non-healed trochanter osteotomy in 1 of the patients, visible 15 months after surgery, was healed both radiographically and clinically after 6 years.

PET results

Mean values of quantitative ¹⁸F uptake in various regions are given in the Figure. 6 years after surgery, the femoral shafts could be clearly visualized bilaterally (operated and non-operated side) on ¹⁸F images. SUV in the non-operated femur (reference) was 2.0 (0.3), which was not statistically significantly different from the 1-year study (2.3 (1.1)). SUV in the Mid region was 2.4 (0.7), which was lower than at 1 year (5.2 (1.2); $p < 0.05$) and not significantly different from the reference ($p = 0.1$). SUV in the Tip region was 3.5 (0.6), which was lower than at 1 year (5.1 (1.0); $p < 0.05$) but still increased compared to the reference ($p < 0.05$).

Small discontinuous areas of elevated uptake were seen in all patients, more so along the proximal stem. These areas corresponded to identical locations of elevated uptake at 1 year, but SUVs were generally lower at 6 years.

The transverse profiles (using radial profile analysis, RPA) of uptake were approximately 20 mm in diameter at 6 years, larger than at 1 year. The reason for profiles having increased relative to 1-year values was more homogenous bone formation throughout the shaft, at approximately equal rates in native bone and graft.

Discussion

We used the PET technique to study bone metabolism and new bone formation in allografts surrounding the femur component in revision THA, 6 years after surgery with the impacted morselized bone allograft technique. Bone metabolism was significantly reduced in most areas of the proximal femur at 6 years compared to the elevated activity during the first year after surgery, and also normalized compared to the contralateral healthy femur. Applying the new technique of RPA, the diameter of maximum bone metabolism on transverse scans of the diaphysis had increased compared to that at 1 year. The reason for this finding is probably a more homogenous bone formation throughout the graft, with approximately equal rates in native bone and grafted bone.

During the first year after surgery there was an intense bone-forming activity, interpreted as bony healing inside the whole bed of impacted bone allograft. After 6 years this activity had diminished to that of normal bone metabolism, both in the native bone and in the graft. Our conclusions from these findings are that PET scans during the first year can reliably predict the results after a longer time period. The results from the contralateral, healthy femurs (i.e. the reference) remained unchanged from 1 to 6 years. The reliability of the method is strengthened by these findings. In addi-

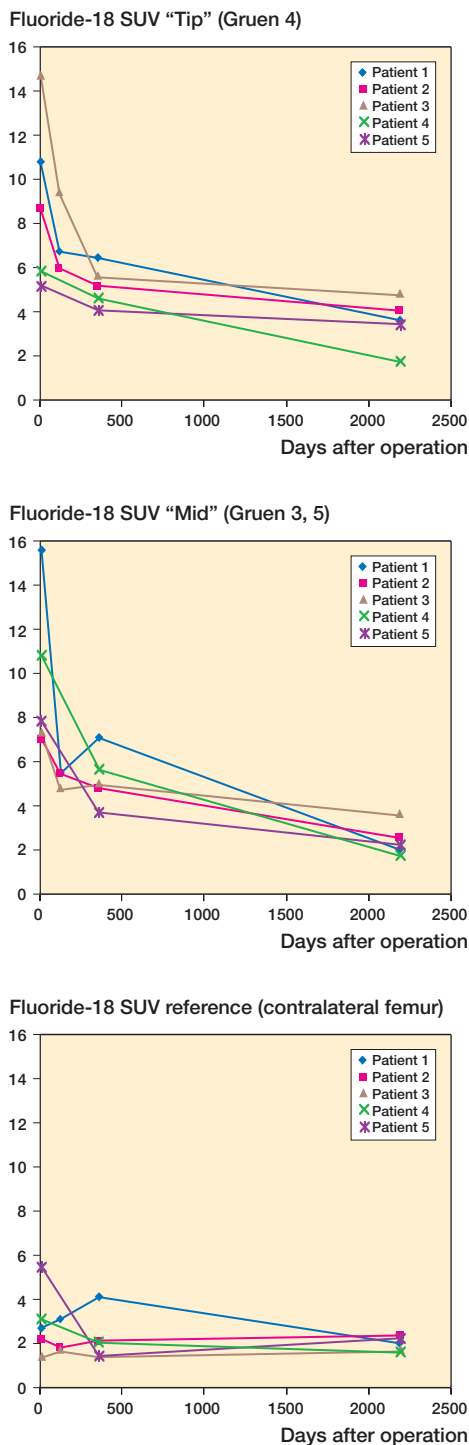


Figure 1. Mean values of $[^{18}\text{F}]$ -fluoride uptake. Measurements were done 1 cm distal to the prosthesis tip (upper), 5 cm proximal to the tip (middle), and in healthy contralateral femur diaphysis (lower).

tion, the current findings are supported by histological observations of 16 cases of impacted bone graft at revision THA during the first year after surgery. In one whole autopsy femur analyzed 4 years after surgery, the healing process was almost complete, to living bone, except for the proximal part in which minor amounts of fibrous tissue could still be found (Ullmark and Obrant 2002). The PET results were supported by signs of bone healing on plain radiographs.

Despite the limited number of patients in our study, the fact that PET data coincided with both histological findings and the results of previous PET studies—as well as the clinical and radiographic outcome in the same patients—leads us to conclude that the results probably give an accurate picture of bone regeneration in the allografts. Thus, the outcome of this study indicates a favorable effect on bone formation of the impaction bone allografting procedure, with rapid bone formation resulting in complete filling of the graft, followed by normalization of bone metabolism. Although the experimental design does not allow conclusions concerning specific details of the procedure, we will stress the importance of performing the surgical procedure according to the instructions from the instrument-manufacturer. The bone allograft was prepared to minimize the containment of donor marrow fat, and to maximize the containment of fibrin clots. This was achieved through reducing fat content within the chips and through the design of the impaction phantoms. These contained small holes, resulting in further fat reduction. and in blood, including thrombocytes and other bioactive agents, to enter the graft bed in its impacted state. In addition, the design of the femoral stem used in this study is important; the stem was matte (radius 1.5 μm) with a collar, and of a medium length (170 mm). This design results in a low tendency to subside.

There is still much to be learned about the physiological processes taking place in the allogenic bone graft in impaction bone grafting for revision THA, but our findings indicate a favorable long-term prognosis for fixation of the stem using this method. Rapid bone formation occurs, resulting in complete filling of the graft, which is then followed by normalization of bone metabolism.

- Charnley J. Numerical grading of clinical results. In: Low friction arthroplasty of the hip: theory and practice (ed. Charnley J). Springer-Verlag 1979: 20-4.
- Elting J J, Mikhail W E M, Zicat B A, Hubbell J C, Lane L E, House B. Preliminary report of impacting grafting for exchange femoral arthroplasty. *Clin Orthop* 1995; (319):159-67.
- Engelbrecht E, Heinert K. Klassifikation und Behandlungsrichtlinien von Knochensubstanzverlusten bei Revisionsoperationen am Hüftgelenk - mittelfristige Ergebnisse. Primäre und Revisionsalloarthroplastik Hrsg-Endo-Klinik, Hamburg. Berlin, etc: Springer-Verlag 1987: 189-201.
- Gie G A, Linder L, Ling R S M, Simon J-P, Slooff T J J H, Timperley A J. Impacted cancellous allografts and cement for revision total hip arthroplasty. *J Bone Joint Surg (Br)* 1993; 75:14-21.
- Kärrholm J, Hultmark P, Carlsson L, Malchau H. Subsidence of a non-polished stem in revisions of the hip using impaction allograft. *J Bone Joint Surg (Br)* 1999; 81: 135-42.
- Linder L. Cancellous impaction grafting in human femur: Histological and radiographic observations in 6 autopsy femurs and 8 biopsies. *Acta Orthop Scand* 2000; 71 (6): 543-52.
- Mikhail W E M, Wretenberg P F, Weidenhielm L R A, Mikhail M N. Complex cemented revision using polished stem and morselized allograft. *Arch Orthop Trauma Surg* 1999; 119: 288-329.
- Nelissen B G H H, Bauer T W, Weidenhielm L R A, Le Golvan D P, Mikhail W E M. Revision hip arthroplasty with the use of cement and impaction grafting, histological analysis of four cases. *J Bone Joint Surg (Am)* 1995; 77: 412-22.
- Patlak C S, Blasberg R G, Fenstermacher J D. Graphical evaluation of blood-to-brain transfer constants from multiple-time uptake data. *J Cereb Blood Flow Metab* 1983; 3: 1-7.
- Piert M, Winter E, Becker G A, Bilger K, Machulla H-J, Myller-Schauenburg W, Bares R, Becker H D. Allogenic bone graft viability after hip revision arthroplasty assessed by dynamic [¹⁸F]fluoride ion positron emission tomography. *Eur J Nucl Med* 1999; 26: 615-24.
- Sörensen J, Ullmark G, Långström B, Nilsson O. Rapid bone and blood flow formation in impacted morselized allografts. *Acta Orthop Scand* 2003; 74 (6): 633-43.
- Ullmark G, Obrant K. Histology of impacted graft incorporation. *J Arthroplasty* 2002; 17: 150-7.
- Ullmark G, Hallin G, Nilsson O. Impacted cortico cancellous allografts and cement for femoral revision of total hip arthroplasty using Lubinus and Charnley prostheses. *J Arthroplasty* 2002; 17 (2): 150-7.