

Sonography after total hip replacement

Reproducibility and normal values in 47 clinically uncomplicated cases

Eva M Hoefnagels¹, Marina Obradov², Monique Reijnierse², Patricia G Anderson³ and Bart A Swierstra¹

Departments of ¹Orthopaedics, ²Radiology, ³OrthoResearch, Sint Maartenskliniek, PO Box 9011, NL-6500 GM Nijmegen, The Netherlands

Correspondence BAS: b.swierstra@maartenskliniek.nl

Submitted 06-01-02. Accepted 06-05-20

Background and purpose Interpretation of sonographic data is difficult when hematoma after total hip replacement is suspected, as there are no normative data. We describe the normal sonographic image, focusing on the amount and location of postoperative fluid collections after a clinically uncomplicated, primary total hip replacement by the posterior approach. Inter- and intraobserver reproducibility is also considered.

Patients and methods We performed sonography of the hip in 47 patients between the second and the fifth postoperative day. Bone-to-capsule distance and deep and superficial extraarticular fluid collections were measured. Intraclass correlation coefficients were calculated.

Results The normal values of bone-to-capsule distance and amount of extraarticular fluid after total hip replacement were established from the upper bound of the 95% confidence interval. The upper bound for bone-to-capsule distance was 6 mm, for deep fluid collections 21 mm, and for superficial fluid collections 28 mm. In this clinically normal patient group, 4 patients had an extreme value (> 3 SD) for bone-to-capsule distance. For the deep and superficial fluid collections, no extremes were found. No correlation was found between bone-to-capsule distance and whether or not there was extraarticular fluid. Intraclass correlation coefficients were 0.98 for bone-to-capsule distance and 0.99 for fluid collection measurements.

Interpretation Sonography is a reproducible method for the evaluation of fluid collections after total hip replacement. The values measured can be helpful in decision making when there is clinical suspicion of postoperative hematoma after hip replacement by the posterior approach. ■

Major hematomas after total hip arthroplasty are feared because of increased infection risk (Eveillard et al. 2001, Saleh et al. 2002). When a postoperative hematoma is suspected, surgical drainage must be considered. As clinical assessment of hematoma formation has been shown to be unreliable, noninvasive diagnostic imaging is desirable (Kong et al. 1993, Möllenhoff et al. 1995, Parrini et al. 1998). Ultrasound is useful in the diagnosis of soft tissue hematomas, as it can detect amounts of fluid as little as 1 mL (Marchal et al. 1987). Detection of hematomas by ultrasound after total hip arthroplasty has been described (Strange-Vognsen et al. 1991, Kong et al. 1993, Möllenhoff et al. 1995, Gaulrapp and Zimmermann 2000). In daily practice, however, interpretation of the sonographic data is difficult, as the normal postoperative image has not been described yet in quantitative terms.

We assessed the normal sonographic image during the first week after primary total hip replacement, together with its clinical feasibility.

Patients and methods

Patient selection

All patients scheduled for primary total hip arthroplasty by the posterior approach were candidates for inclusion. Exclusion criteria were: hemorrhagic disorders, postoperative rehabilitation due to complicated surgery, thrombosis prophylaxis that deviated from the routine protocol, or participation in concomitant studies.

The daily number of total hip arthroplasties outweighed the capacity for sonographic measurements: only 1 patient per day could be scanned for this study. Moreover, these operations were performed by 7 surgeons. To address the capacity problem and to facilitate the selection of a random sample of patients, every week 3–4 patients were included by preconceived selection. Patients undergoing primary total hip replacement were numbered consecutively, starting with the first patient in operating room 1 and finishing with the last patient in operating room 4. A “lottery” computer program was used to select 3 numbers (patients) in order of priority. On the first postoperative day, the patients selected—provided they did not fulfill the exclusion criteria—were asked to give their (informed) consent to undergo a sonographic investigation. If the first preselected patient had to be excluded, or did not consent, patient 2 was approached, etc. In addition to other complications, clinical signs of hematoma, infection or wound healing disturbances were recorded.

The regional medical ethics committee granted permission for the study.

Sonography

For sonography we used the Philips ATL 5000 (Philips, The Netherlands). The examination was performed with a 2–5 MHz, 40 R curved transducer parallel to the prosthesis “neck”, according to the method of Van Holsbeeck et al. (1994). Sono CT and XRes technology were used. The amount of intracapsular fluid was quantified by the measurement of the bone-to-(pseudo) capsule distance at the anterior superior margin of the resected femur neck, adjacent to the prosthesis (Figure 1). Sonograms of the wounds were obtained with the same transducer. To assess extraarticular fluid collection, we scanned the thigh tissue longitudinally and transversally for the fluid. The measurements of superficial fluid collections (between skin and the fascia lata) and deep fluid collections (between fascia lata and the femoral cortex) were obtained in the transversal direction, perpendicular to the femur at the level of the greatest diameter. Fluid collection was identified as hypoechoic area in the soft tissues (Figure 2).

Sonography was performed either on the second, third, fourth or fifth postoperative day. Initially,

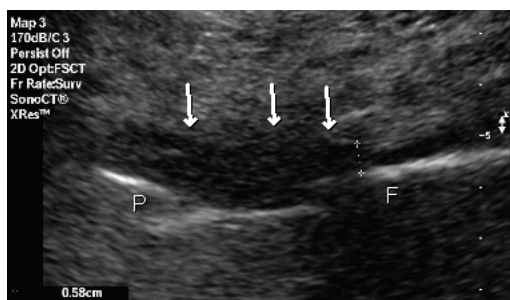


Figure 1. Sagittal anterior sonographic appearance of a hip prosthesis. Arrows show normal anterior part of the post-operative capsule in front of the prosthetic head (P) and the proximal femur (F). Callipers indicate bone-to-capsule distance.

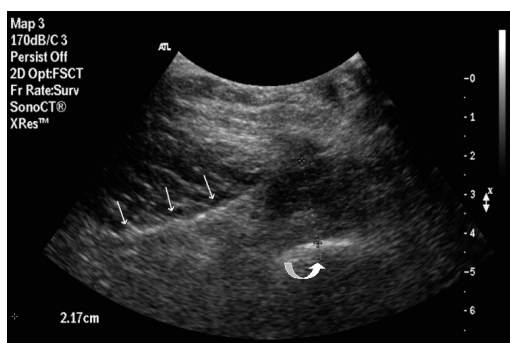


Figure 2. Transversal sonographic appearance of deep fluid collection between fascia lata (arrows) and femoral cortex (curved arrow). Callipers indicate measurement.

the patients were measured twice by each of the 2 independent radiologists. After determining the inter- and intra-observer correlation for the first 21 patients, the remaining 26 patients were measured twice by only 1 of the 2 radiologists.

Statistics

Intra- and interobserver reproducibility were determined by intraclass correlation coefficients (ICCs) that estimate the average correlation among all pairs of data. Any ICC value greater than 0.9 was considered excellent. The distribution of the data was assessed with box and whisker plots. A one-way ANOVA was used to determine if the bone-to-capsule distance was related to the interval in days between the operation time and the sonography, with alpha set at 0.05. Spearman rho analysis was used for analysis of correlation between bone-to-capsule distance and the presence of extraarticular fluid, with alpha set at 0.05.

Sonographic measurements (in mm) in 47 patients after total hip arthroplasty

	No. of patients	Mean	SD	95% CI	Median	Range
Bone-to-capsule distance	47	5	3	4–6	5	1–14
Deep fluid collection	22	16	9	12–21	16	4–39
Superficial fluid collection	7	17	9	6–28	14	8–28

Results

In the 47 patients (hips) included in the study, the median age at the time of operation was 63 (24–82) years and the mean body mass index was 26 (SD 4.1). The mean operation time was 61 (SD 14) min. The mean peroperative blood loss was 386 (SD 135) mL.

Sonographic findings

All the fluid collections identified were hypoechoic, without internal reflections. The bone-to-capsule distances and extraarticular fluid collections for the 47 patients are presented in the Table. An extraarticular fluid collection was present in 28 patients, and 1 patient had both superficial and deep fluid collections.

The number of days in the interval between the operation and the sonography had no apparent influence on the bone-to-capsule distance ($p = 0.3$). Thus, the data were combined for subsequent calculations.

According to the box and whisker plots, 4 outliers were present in the bone-to-capsule distance (with measurements of more than 3 SD from the mean). The extraarticular fluid collection measurements did not show outliers. There were no clinical complications in the patients with extreme values.

Reproducibility

The ICC for bone-to-capsule distance for the first 21 patients, measured by 2 radiologists, was 0.98 (95% CI: 0.96–0.99). The ICC for the extra articular deep and superficial fluid measurements was 0.99 (95% CI: 0.97–1.0).

Normal values

The biological variation in our clinically normal patient group is apparent by the wide range of the measurements and the large standard deviation.

Thus, the upper bound of the 95% CI was determined as normal value, being 6 mm for the bone-to-capsule distance, 21 mm for amount of deep fluid collection, and 28 mm for amount of superficial fluid collection (Table).

Correlation of sonographic signs

We found no correlation between bone-to-capsule distance and the presence of an extraarticular fluid collection. Also, in the 28 patients with an extraarticular fluid collection, there was no correlation between the amount of fluid (deep or superficial) and the bone-to-capsule distance.

Discussion

Hematomas can be visualized by sonography. Even routine sonography after total hip arthroplasty—to detect and evacuate hematomas to reduce the risk of infection—has been advocated (Möllenhoff et al. 1995). The question of how sonography after total hip arthroplasty should be put into practice, and when one should consider intervention, has received scant attention, however. Using sonography, Parrini et al. (1998) studied the effectiveness of postoperative drains after total hip replacement in 84 cases using a different surgical approach from the one we used (lateral as opposed to posterior), but no quantitative data were reported. In a study of 14 patients 5 years on average after hip arthroplasty, Weybright et al. (2003) showed overlap of the measurements of the bone-to-capsule distance in groups with and without effusion. They explained this by the inability of ultrasound to differentiate between synovitis and joint effusions. Tissue harmonic imaging was not routinely used, and thus the usefulness of their technique was not completely assessed. Möllenhoff et al. (1995) relied on sonographic findings for indica-

tion of reoperation or puncture of a hematoma to prevent infection, but they did not present specific guidelines. Gaulrapp and Zimmermann (2000) described the sonographic appearance at 4 weeks after hip replacement in 73 patients, but they did not report measurements. Strange-Vognsen et al. (1991) gave mean volume ranges for subcutaneous (6–100 mL) and deep (2–72 mL) fluid measurements in 35 cases, but no further calculations were done. Kong et al. (1993) graded hypoechoic areas found exclusively in the subcutaneous layer; however, no exact location of hematoma formation or normal values can be derived from that study.

Our study provides clear values for the normal postoperative sonographic image after total hip replacement. Our data can be considered to be representative for everyday practice, as bias regarding surgeon or peroperative procedure was avoided by the preconceived selection.

Our data are limited to the posterior approach, and other approaches may give other values. Another limitation is that we did not measure the postoperative hematoma in the soft tissues in three dimensions. However, we used the depth or thickness of the hematoma as a guide (Kong et al. 1993). A clear division could be made between hematomas in the subcutaneous layer and those that extended deeper to the fascia lata. One other issue that needs to be considered critically is the bone-to-capsule distance, which is measured on the anterior side of the hip. In the case of hematoma formation, the increase in this distance is probably limited by leakage of blood out of the “joint” through the partially repaired posterior capsule. This may be reflected by extraarticular fluid; yet, we found no correlation between the bone-to-capsule distance and the presence or magnitude of the extraarticular fluid in our patient group.

The excellent intraclass correlation coefficient for the 2 radiologists regarding the bone-to-capsule distance and extraarticular fluid collections implies that sonography is reproducible and thus reliable. Thus, it can be incorporated into the routine diagnosis of postoperative hematomas and routine imaging of the postoperative hip effusion.

Any bone-to-capsule distance greater than 6 mm, extraarticular deep fluid collection of more than 21

mm, and superficial fluid collection of more than 28 mm can be considered to be greater than normal. Of course, these values per se do not indicate surgical intervention, but are helpful when combined with other clinical parameters in the diagnostic work-up and therapeutic decision making process when unusual early pain arises in patients who have undergone total hip arthroplasty.

Contributions of authors

EMH: ran the clinical part of the study and wrote the manuscript. MO and MR: performed the sonographies and interpreted the results. PGA: analyzed the results. BAS: designed the study and completed the manuscript.

No competing interests declared.

Eveillard M, Mertl P, Canarelli B, Lavenne J, Fave M H, Eb F, Vives P. Le risque d'infection des prothèses totales de hanche réalisées en première intention. Évaluation sur une série continue de 790 cas. [Risk of deep infections in first intention total hip arthroplasties]. *Presse Med* 2001; 30:1868-75.

Gaulrapp H, Zimmermann T. Sonographische Veränderungen nach endoprothetischer Versorgung des Hüftgelenks [The value of sonography after total replacement of the hip joint]. *Ultraschall in Med* 2000; 21: 122-7.

Kong K, Jeyagopal N, Davies S J. Should we still stitch the subcutaneous fat layer? A clinical and ultrasound assessment in 50 hip operations. *Ann R Coll Surg Eng* 1993; 75: 23-5.

Marchal G J, Van Holsbeeck, M T, Raes M, Favril A A, Verbeke E E, Casteels-Vandaele M, Baert A L, Lauweryns J M. Transient synovitis of the hip in children: role of US. *Radiology* 1987; 162: 825-8.

Möllenhoff G, Walz M, Muhr G. Kontrolle von Wundheilungsstörungen mittels Sonographie anhand postoperativer Kontrollen nach TEP-Implantation. [Diagnosis of wound complications by sonography in postoperative monitoring after hip replacement]. *Chirurg* 1995; 66:188-91.

Parrini L, Baratelli M, Parrini M. Ultrasound examination of hematomas after total hip replacement. *Int Orthop* 1998; 12: 79-82.

Saleh K, Olson M, Resig S, Bershadsky B, Kuskowski M, Gioe T, Robinson H, Schmidt R, McElfresh E. Predictors of wound infection in hip and knee joint replacement: results from a 20 year surveillance program. *J Orthop Res* 2002; 20: 506-15.

Strange-Vognsen H H, Tørholm C, Lebech A, Hancke S. Hematomas and subcutaneous suture techniques in total hip replacement. An ultrasound study. *Arch Orthop Trauma Surg* 1991; 111: 51-2.

van Holsbeeck M T, Eyler W R, Sherman L S, Lombardi T J, Mezger E, Verner J J, Schurman J R, Jonsson K. Detection of infection in loosened hip prostheses: efficacy of sonography. *Am J Roentgenol* 1994; 163: 381-4.

Weybright P N, Jacobson J A, Murry K H, Lin J, Fessell D P, Jamadar D A, Kabeto M, Hayes C W. Limited effectiveness of sonography in revealing hip joint effusion: Preliminary results in 21 adult patients with native and postoperative hips. *Am J Roentgenol* 2003; 181: 215-8.