

Irradiation has no effect on the incorporation of impacted morselized bone

A bone chamber study in goats

Gerjon Hannink^{1,2}, B Willem Schreurs² and Pieter Buma^{1,2}

¹Orthopaedic Research Lab, ²Department of Orthopaedics, Radboud University Nijmegen Medical Centre, P.O. Box 9101, 6500 HB Nijmegen, the Netherlands

Correspondence: p.buma@orthop.umcn.nl

Submitted 06-01-03. Accepted 06-05-04

Background Gamma irradiation has been widely used for sterilization of bone allografts. However, gamma irradiation alters proteins. This is favorable when it reduces immunogenicity, but is undesirable when osteoinductive proteins are damaged. Although the effect of gamma irradiation on BMPs has been studied, the effect of irradiation on the process of incorporation of morselized bone chips remains unclear. We studied the effects of sterilization by gamma irradiation on the incorporation of impacted morselized allografts.

Methods Bone chambers with impacted allografts, rinsed impacted allografts, allografts that were rinsed and subsequently irradiated, and an empty control were implanted in proximal medial tibiae of goats. Incorporation was evaluated using histology and histomorphometry.

Results Histology revealed evidence of bone graft incorporation, which proceeded in a similar way in unprocessed, rinsed, and both rinsed and irradiated bone grafts. After 12 weeks, no difference in bone and tissue ingrowth was found between the unprocessed, the rinsed, and the rinsed and subsequently irradiated allografts. The amount of unresorbed graft remnant was highest in the unprocessed bone grafts.

Interpretation We conclude that sterilization with gamma irradiation does not influence the incorporation of impacted rinsed bone allografts.

gery in both the acetabulum (Schreurs et al. 2004) and the femur (Halliday et al. 2003, Schreurs et al. 2005). Despite promising clinical results with allografts, bone autografts remain the gold standard. However, the use of autografts is limited by the amount of graft available and additional donor site morbidity created by the harvest procedure. In order to obtain results that are more comparable with those of autografts, osteoconductivity is often promoted by rinsing allografts before impaction, thereby improving the incorporation process (Thoren et al. 1995, Van Der Donk et al. 2003). However, one remaining major disadvantage of using allografts is the potential risk of disease transmission.

Gamma irradiation has been widely used for (terminal) sterilization of bone allografts due to its efficacy in preventing transmission of both bacteria (Angermann and Jepsen 1991, Hilmy et al. 2000) and viruses (Hernigou et al. 2000, Smith et al. 2001). Due to changes in mechanical properties of bone by gamma irradiation, it has been used with some caution in clinical practice—especially in load-bearing applications. Irradiated morselized bone was found to be less strong, less stiff and significantly more brittle than fresh-frozen control bone when tested in compression models (Cornu et al. 2000). However, it has been shown that irradiated freeze-dried impacted grafts provide a more stable femoral reconstruction than fresh-frozen grafts when tested in a hip simulator (Cornu et al. 2003). On the other hand, the higher degree

Impacted morselized bone grafts are used successfully to restore bony defects in revision hip sur-

of compactness caused by impaction of irradiated bone may reduce the speed of the incorporation process (Tagil and Aspenberg 1998).

Irradiation has also been found to alter proteins. This is favorable when it reduces immunogenicity, but appears to be undesirable when osteoinductive proteins are altered or damaged. Osteoinductive proteins within the graft may be important in the process of incorporation. These proteins may be released during the resorptive phase of bone graft incorporation, and can have a profound effect on bone cell physiology. Although studies have been performed to determine the effect of irradiation on BMPs (Munting et al. 1988, Wientroub and Reddi 1988, Dziedzic-Goclawska et al. 1991, Ijiri et al. 1994, Andriano et al. 2000, Ripamonti et al. 2000, Pekkarinen et al. 2005), the effect of irradiation on the incorporation process of morselized bone chips remains unclear. We studied the effects of sterilization by gamma irradiation on the incorporation of impacted morselized allografts. Using a bone chamber model in goats, the process of bone incorporation was studied in fresh-frozen bone grafts, rinsed bone grafts, and bone grafts that had been both rinsed and irradiated, at 12 weeks after surgery.

Material and methods

Animals

12 mature female Dutch milk goats (*Capra Hircus Sana*) (45–56 kg) were obtained from the Central Animal Laboratory, Radboud University Nijmegen, the Netherlands. The goats received two bone chambers at each side in the cortical bone of the proximal medial tibia. We implanted an empty chamber, a chamber containing fresh-frozen impacted allograft, a chamber containing rinsed impacted allograft, and a chamber containing allograft that had been rinsed and subsequently irradiated. The position of implantation among the chambers and the side for each chamber were randomized. All procedures were approved by the Animal Ethics Committee of Radboud University Nijmegen.

Preparation of grafts

Cancellous allografts were obtained from the sternum of 6 donor goats. Familial bonds between



Figure 1. The bone ingrowth chamber. The chamber consists of two threaded half-cylinders held together by a cylindrical closed screw cap. 4 round ingrowth openings are located at the endosteal level.

donor and recipient goats were excluded. To prevent bias in terms of different immunological reactions, the allografts were pooled.

One-third of the pooled allograft was used as fresh-frozen allograft. Blood and marrow of the remaining two-thirds were removed macroscopically by rinsing the grafts with saline for approximately 1 min, leaving only a white bone structure. Rinsing was done using a high-pressure pulsatile lavage system (SurgiLav Plus; Stryker Nederland BV, Waardenburg, the Netherlands). Grafts were located in a sieve during rinsing. Half of the rinsed cancellous allograft was subsequently irradiated with a minimal dose of 25 kGy using a ^{60}Co gamma-ray source (Isotron BV, Ede, the Netherlands) at a temperature of -78.5°C (on dry ice). Bacterial cultures from all three types of grafts were negative. The grafts were stored at -80°C until use. Before implantation, they were thawed at room temperature and cut into pieces of $2 \times 2 \times 1$ mm using a rongeur.

Bone chamber

The bone ingrowth chamber used in this study was a modification of a large bone chamber (ROU) (Hannink et al. 2006), which was in turn based on the bone conduction chamber (Aspenberg and Wang 1993). The chamber consisted of two threaded half-cylinders held together by a cylindrical closed screw-cap, and was made of commercially pure titanium (Figure 1). The interior of the chamber had a diameter of 6 mm and a length of 8.5 mm. The outer diameter was 8 mm, and the overall length 13 mm. Two additional ingrowth openings were added to the original model (Han-

nink et al. 2006), resulting in a total of 4 round ingrowth openings, each 1.5 mm in diameter. All ingrowth openings were located at the same height, at endosteal level.

Impaction procedure

Impaction was performed by gradually filling the chamber with the allograft bone. A piston, slightly smaller in diameter, was used for impaction. The piston was guided by low-friction bearings, strictly limiting it to vertical movement. The chamber was clamped into a cylindrical holder. A constant force of 680 N was kept on the free end of the piston for 2 min. During this time, fluid could escape between the piston and the wall of the bone chamber and the ingrowth openings. The pressure applied was calculated to be 25 MPa. With this method of impaction, the mean volume fraction rises from about 35% in unimpacted grafts to about 65% in the impacted ones (Tagil and Aspenberg 1998). After impaction, the closed screw cap was screwed on.

Surgical technique

The goats were anesthetized by intravenous administration of sodium pentobarbital (0.5 mL/kg) and maintained after intubation with nitrous oxide, oxygen and isoflurane (1.5–2%). Under aseptic conditions, a longitudinal incision was made in the skin and fascia over the medial side of the proximal tibia. After raising the periosteum, a hole was drilled through the medial cortex at approximately 4 cm from the joint cleft using a 7.3-mm watercooled hollow diamond-tipped drill (Surgical Diamond Instruments; Scientific Developments GmbH, Munich, Germany). The hole was tapped, and bone debris from drilling was removed. The bone chamber was screwed in manually. The second bone chamber was placed at a distance of 10 mm distally from the first one. This was repeated for the other side. The subcutaneous layer and the skin were sutured. All animals were allowed unrestricted movement in their cages and had free access to water and food after the operation. After the implantation procedure, the animals received subcutaneous ampicillin (15 mg/kg/48 h) 3 times.

After 12 weeks, all goats were killed with an overdose of sodium pentobarbital (1 mL/kg). The tibiae were removed, and the bone chambers with surrounding cortex were fixed in 4% buffered for-

malin. After 1 day, the content was removed from the chambers and fixed additionally.

Evaluation

All specimens were scanned in a μ CT (μ CT20; Scanco Medical AG., Bassersdorf, Switzerland.) with an isotropic spatial resolution of 9 μ m to evaluate the bone volume fraction of the impacted graft remnants at the top of the chambers. Impacted irradiated bone could have a higher compactness, thereby influencing the incorporation process.

The scans were segmented into binary images. We used a local segmentation algorithm consisting of a standard edge-detection algorithm, extended to 3D, to find the location of the actual surface of the bone (Waarsing et al. 2004). From each specimen, a $4 \times 4 \times 2$ mm volume of interest was taken at the center of the top of the bone chamber. From the 3D-reconstructions, we determined the bone volume fraction (BV/TV) of the graft remnant.

Following μ CT scanning, the specimens were dehydrated using ethanol and embedded in polymethylmethacrylate. The specimens were cut with a microtome (Leica RM 2155; Leica Microsystems Nederland BV, Rijswijk, the Netherlands) parallel to the longitudinal axis of the chamber. Five 5- μ m thick sections taken at 0, 600, 1,200, 1,800 and 2,400 μ m from the center of each specimen, were used for histology and histomorphometry. All sections within each experiment were investigated in random order. The tests were done blind, but it was possible to see whether or not a specimen originated from the empty chamber group. The sections were stained with hematoxylin and eosin, and Goldner-Masson trichrome for routine histology. Histomorphometric analysis was performed using interactive computer-controlled image analysis (analySIS; Soft Imaging System GmbH, Münster, Germany). The bone ingrowth distance in each slide was calculated by dividing the area of new bone by the width of the specimen (Aspenberg and Wang 1993). In all specimens, marrow cavities surrounded by bone were included in the bone area. The total tissue ingrowth distance, which is the distance from the ingrowth end to the fibrous ingrowth frontier, was measured in the same way as bone ingrowth. The mean of 5 sections yielded a value for each specimen.

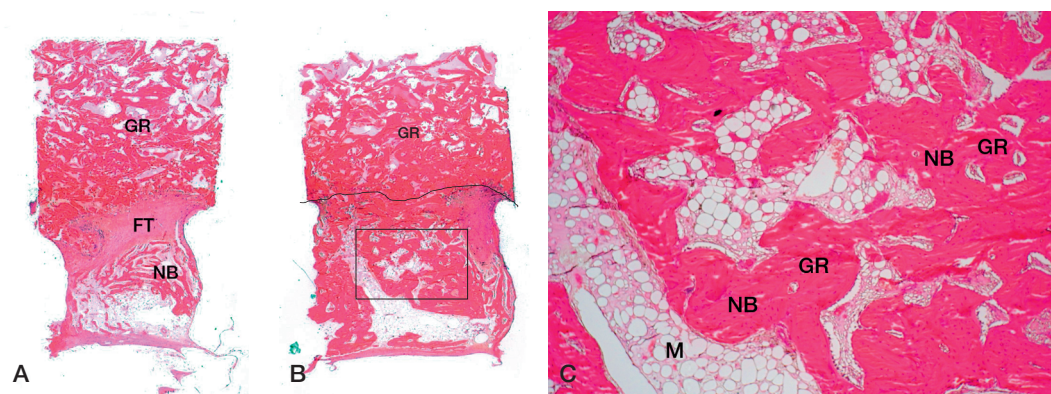


Figure 2. Hematoxylin and eosin (H&E) stained sections. (A) Typical example of bone chamber content. Graft remnants (GR) are still present in the top of the specimen. New bone (NB) formation takes place from the ingrowth openings up to the top of the chamber. Fibrous tissue (FT) precedes the bone ingrowth front. 12.5 × magnification (B) Overview of an rinsed and irradiated specimen. Unincorporated graft remnants (GR) are present at the top of the chamber. Incorporated graft remnants are present below the front of bone ingrowth. This front is indicated by a line. A detail of the area inside the box is given in the next panel. 12.5 × magnification (C) Detail showing the area of new bone formation. Within this area, new bone (NB) is apposed on graft remnants (GR) at the bottom of the chamber and a marrow cavity (M) has formed. 50 × magnification.

Statistics

Statistical analysis was performed using a univariate analysis of variance (SPSS software) with the factors goat, side, position and chamber type. To isolate the group or groups differing from the others, Tukey's multiple comparison procedure was used. Normality and homogeneity of variance were tested using the tests of Kolmogorov-Smirnov and Levene. When the assumption of normality or homogeneity of variance was not met, a Friedman repeated-measures ANOVA on ranks was performed. P-values less than 0.05 were considered to be significant. The study was designed to have 80% power in detecting a difference of 0.5 mm between the means of all groups.

Results

Cinical evaluation

No intraoperative complications occurred. All goats recovered well after surgery. There were no signs of inflammation, skin ulceration or wound healing problems. All bone chambers were strongly fixed into the tibia. In most cases the bone chambers were surrounded by a layer of callus and covered with fibrous tissue, irrespective of the contents of the chamber. No new bone formation was seen at the endosteal surface of the tibial cortex.

Histology

A layer of necrotic, nonvascularized graft remnant was present at the top of the chamber, either with fibrous tissue infiltration or only graft material as when inserted. Fibrous tissue was present between the new bone at the bottom of the chamber and the graft remnant at the top of the chamber. This fibrous tissue preceded the bone ingrowth front (Figure 2a). The graft material was penetrated by a loose mesenchymal-like tissue with blood sinusoids and capillaries. In the fresh-frozen allografts, a denser fibrous tissue was observed. This group showed a more sharply defined ingrowth frontier, where the fibrous tissue was organized more loosely at the transition with the graft remnants in the rinsed allografts and those that were both rinsed and irradiated. No difference in amount of vascularization was seen.

Newly formed bone was present in all bone chambers. New bone was formed by intramembranous ossification, growing upward into the chamber. The amount and appearance of the new bone varied between specimens—from young, woven bone surrounded by active osteoblasts to more mature lamellar bone with fatty marrow and trabeculae. If the resorption of the graft remnant was not complete, new bone was apposed on these remnants (Figure 2b and c). This apposition of new bone was only observed in allografts that had been

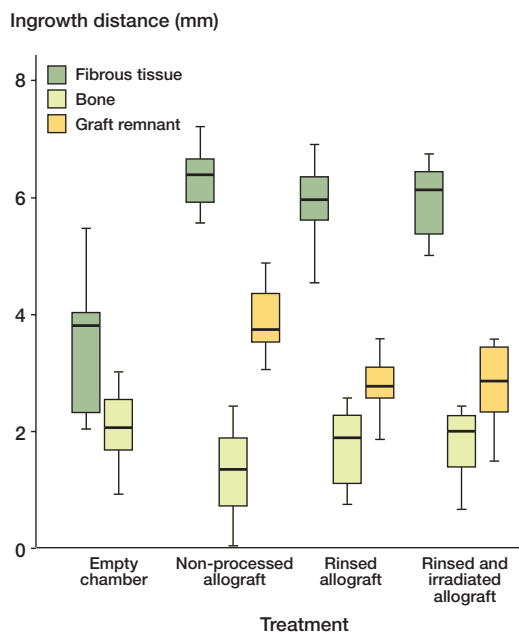


Figure 3. Box plot of histomorphometrical results. Rinsing and subsequent irradiation had no effect on total tissue ingrowth or bone ingrowth compared to rinsing and no rinsing of allografts. No rinsing resulted in more graft remnant at the top of the bone ingrowth chamber.

rinsed and those that had been both rinsed and irradiated.

Histomorphometry

Neither side ($p = 0.7$, $p = 0.5$, and $p = 0.4$) nor position ($p = 1.0$, $p = 1.0$, and $p = 0.7$) of the chamber affected bone ingrowth or total tissue ingrowth or amount of remaining graft, respectively. None

of the factors interacted. Rinsing of allografts and subsequent irradiation had no added effect on total tissue ingrowth or bone ingrowth distance relative to rinsing only ($p = 1.0$ and $p = 1.0$) or no processing ($p = 0.7$ and $p = 0.2$), respectively (Figure 3). However, no processing of allografts resulted in more graft remnant in the top of the chamber compared to rinsing ($p < 0.001$) and both rinsing and irradiation ($p < 0.001$) (Table 1). Irradiation after rinsing had no effect on the amount of graft remnant (resorption process) compared to rinsing alone ($p = 1.0$) (Figure 3). Ingrowth of fibrous tissue in the empty chamber was significantly less than in the other groups ($p < 0.001$). However, there was significantly more ingrowth of bone in the empty chamber than in the unprocessed allograft group ($p = 0.01$), but this was no different from bone ingrowth in the group with rinsed allograft ($p = 0.4$) and in the group with allograft that was rinsed and subsequently irradiated ($p = 0.5$). Furthermore, no difference in bone volume fraction (BV/TV) of the graft remnants between the groups was found using μ CT ($p = 0.6$) (Table 2).

Discussion

During sterilization by gamma irradiation, highly reactive hydroxyl radicals are formed due to ionization of water molecules. These free radicals have been speculated to impair the integrity of collagen molecules (Hamer et al. 1999). In addition, radiation may also denature bone morphogenetic proteins, thereby reducing the osteoinductive potential of the allograft.

Table 1. Bone ingrowth, soft tissue ingrowth and size of graft remnant in empty bone chambers and bone chambers containing unprocessed allografts, rinsed allografts, and rinsed and irradiated allografts

	Number of implants	Empty	Treatment groups		
			Unprocessed allograft	Rinsed allograft	Rinsed and irradiated allograft
Bone ingrowth	12	2.08 (0.62)	1.32 (0.71)	1.74 (0.66)	1.78 (0.63)
Soft tissue ingrowth	12	3.51 (1.21)	6.32 (0.50)	5.96 (0.66)	5.95 (0.62)
Size of graft remnant	12	–	3.99 (0.74)	2.79 (0.49)	2.77 (0.70)

Values are mean (SD) in mm.

Table 2. Bone volume fraction (%) of graft remnants

	Number of implants	Empty	Treatment groups		
			Unprocessed allograft	Rinsed allograft	Rinsed and irradiated allograft
BV/TV	12	–	66 (14)	69 (13)	69 (13)
Values are mean (SD), in percent.					

Controversial results concerning the effect of radiation sterilization on the osteoinductive potential of both bone and BMPs have been published. In some studies, irradiation has been found to inhibit (Buring and Urist 1967) or only partially destroy (Munting et al. 1988, Schwarz et al. 1988, Ijiri et al. 1994, Zhang et al. 1997) the osteoinductive capacity. In others, no effect of irradiation on the osteoinductive capacity has been found (Wientroub and Reddi 1988, Andriano et al. 2000, Ripamonti et al. 2000, Pekkarinen et al. 2005).

There have been few clinical reports of impaction grafting with irradiated bone grafts in hip revision surgery on both the femoral (Robinson et al. 2002, Bankes et al. 2003) and acetabular side (Holt et al. 2001, Buckley et al. 2005), using radiological and clinical scores as outcome measures. In one study evaluating femoral impaction grafting with the Exeter hip and unwashed irradiated (25 kGy) bone grafts, a lack of radiological incorporation and trabecular remodeling was found (Robinson et al. 2002). In contrast, in a 2–7-year follow-up study using rinsed fresh irradiated (25–30 kGy) allograft bone in 41 revision femoral arthroplasties, Bankes et al. (2003) found no significant difference in clinical or radiographical outcome. Comparing fresh-frozen and irradiated allograft bone in impaction grafting of the acetabulum, Holt et al. (2001) found no obvious difference in clinical performance with evidence of incorporation and remodeling after 6 months and 13 months for the irradiated graft, using 2 different radiographical criteria. Buckley et al. (2005), using unwashed irradiated (25 kGy) bone for acetabular revision surgery, showed an 88% survival rate at a mean follow-up time of 5 years, which is comparable with that of studies using unirradiated bone. In addition, Hamer et al. (1997) histologi-

cally examined 5 cases of re-revision where irradiated cortical allograft had been used. All cases showed favorable histological features, with soft tissue attachment by fibrous adhesion, union of graft to host, and osseous remodeling.

One explanation for the good performance of the rinsed and subsequently irradiated allografts in our study may be that the allograft was irradiated on dry ice and not at room temperature. Recently, Hamer et al. (1999) reported that irradiation of cortical bone at dry ice temperature gave partial protection against embrittlement compared to the more common practice of irradiating bone at room temperature. Freezing reduces the mobility of water molecules, and may therefore decrease the production of free radicals. Protection of the osteoinductive properties of bone allografts has been observed when irradiation was performed at low temperatures (Dziedzic-Goclawska et al. 1991). Furthermore, the removal of marrow by rinsing the allografts before irradiation may have been favorable, since gamma irradiation of human bone allografts alters medullary lipids and releases toxic compounds from osteoblast-like cells (Moreau et al. 2000). Another explanation may be that the osteoinductive capacity of bone allografts in impaction grafting may be less important than the osteoconductive capacity (when implanted in a healthy bone bed). Observations on retrieved human allografts suggest that large frozen allografts in humans are osteoconductive rather than osteoinductive (Enneking and Campanacci 2001).

In summary, we have found no negative effect on graft incorporation after impaction of rinsed and subsequently irradiated bone in an unloaded model. Further clinical studies are warranted.

Contributions of authors

GH: did most of the work. BWS: supervised the study from a surgical perspective. PB: supervised the study from a biological perspective.

This study was sponsored by Stryker Orthopaedics, Limerick, Ireland.

- Andriano K P, Chandrashekar B, McEnery K, Dunn R L, Moyer K, Balliu C M, Holland K M, Garrett S, Huffer W E. Preliminary in vivo studies on the osteogenic potential of bone morphogenetic proteins delivered from an absorbable puttylike polymer matrix. *J Biomed Mater Res* 2000; 53: 36-43.
- Angermann P, Jepsen O B. Procurement, banking and decontamination of bone and collagenous tissue allografts: guidelines for infection control. *J Hosp Infect* 1991; 17: 159-69.
- Aspenberg P, Wang J S. A new bone chamber used for measuring osteoconduction in rats. *Eur J Exp Musculoskel Res* 1993; 2: 69-74.
- Bankes M J K, Allen P W, Aldam C H. Results of impaction grafting in revision hip arthroplasty at two to seven years using fresh and irradiated allograft bone. *Hip Int* 2003; 13: 1-11.
- Buckley S C, Stockley I, Hamer A J, Kerry R M. Irradiated allograft bone for acetabular revision surgery. Results at a mean of five years. *J Bone Joint Surg (Br)* 2005; 87: 310-3.
- Buring K, Urist M R. Effects of ionizing radiation on the bone induction principle in the matrix of bone implants. *Clin Orthop* 1967; (55): 225-34.
- Cornu O, Banse X, Docquier P L, Luyckx S, Delloye C. Effect of freeze-drying and gamma irradiation on the mechanical properties of human cancellous bone. *J Orthop Res* 2000; 18: 426-31.
- Cornu O, Bavadekar A, Godts B, Van Tomme J, Delloye C, Banse X. Impaction bone grafting with freeze-dried irradiated bone. Part II. Changes in stiffness and compactness of morselized grafts - Experiments in cadavers. *Acta Orthop Scand* 2003; 74: 553-8.
- Dziedzic-Goclawska A, Ostrowski K, Stachowicz W, Michalik J, Grzesik W. Effect of radiation sterilization on the osteoinductive properties and the rate of remodeling of bone implants preserved by lyophilization and deep-freezing. *Clin Orthop* 1991; (272): 30-7.
- Enneking W F, Campanacci D A. Retrieved human allografts: a clinicopathological study. *J Bone Joint Surg (Am)* 2001; 83: 971-86.
- Halliday B R, English H W, Timperley A J, Gie G A, Ling R S M. Femoral impaction grafting with cement in revision total hip replacement - Evolution of the technique and results. *J Bone Joint Surg (Br)* 2003; 85: 809-17.
- Hamer A J, Suvarna S K, Stockley I. Histologic evidence of cortical allograft bone incorporation in revision hip surgery. *J Arthroplasty* 1997; 12: 785-9.
- Hamer A J, Stockley I, Elson R A. Changes in allograft bone irradiated at different temperatures. *J Bone Joint Surg (Br)* 1999; 81: 342-4.
- Hannink G, Aspenberg P, Schreurs B W, Buma P. Development of a large titanium bone chamber to study in vivo bone ingrowth. *Biomaterials* 2006; 27: 1810-6.
- Hernigou P, Gras G, Marinello G, Dormont D. Inactivation of HIV by application of heat and radiation: implication in bone banking with irradiated allograft bone. *Acta Orthop Scand* 2000; 71: 508-12.
- Hilmy N, Febrida A, Basril A. Validation of radiation sterilization dose for lyophilized amnion and bone grafts. *Cell Tissue Bank* 2000; 1: 143-8.
- Holt G M, Stockley I, Elson R A, Ibbotson C. A comparison of the performance of irradiated and non-irradiated bone graft in hip surgery. *Hip Int* 2001; 11: 18-24.
- Ijiri S, Yamamuro T, Nakamura T, Kotani S, Notoya K. Effect of sterilization on bone morphogenetic protein. *J Orthop Res* 1994; 12: 628-36.
- Moreau M F, Gallois Y, Basle M F, Chappard D. Gamma irradiation of human bone allografts alters medullary lipids and releases toxic compounds for osteoblast-like cells. *Biomaterials* 2000; 21: 369-76.
- Munting E, Wilmart J F, Wijne A, Hennebert P, Delloye C. Effect of sterilization on osteoinduction. Comparison of five methods in demineralized rat bone. *Acta Orthop Scand* 1988; 59: 34-8.
- Pekkarinen T, Hietala O, Jamsa T, Jalovaara P. Effect of gamma irradiation on the osteoinductivity of morphogenetic protein extract from reindeer bone. *Acta Orthop* 2005; 76: 231-6.
- Ripamonti U, Van Den Heever B, Crooks J, Tucker M M, Sampath T K, Rueger D C, Reddi A H. Long-term evaluation of bone formation by osteogenic protein 1 in the baboon and relative efficacy of bone-derived bone morphogenetic proteins delivered by irradiated xenogeneic collagenous matrices. *J Bone Miner Res* 2000; 15: 1798-809.
- Robinson D E, Lee M B, Smith E J, Learmonth I D. Femoral impaction grafting in revision hip arthroplasty with irradiated bone. *J Arthroplasty* 2002; 17: 834-40.
- Schreurs B W, Bolder S B, Gardeniers J W, Verdonschot N, Slooff T J, Veth R P. Acetabular revision with impacted morsellized cancellous bone grafting and a cemented cup. A 15- to 20-year follow-up. *J Bone Joint Surg (Br)* 2004; 86: 492-7.
- Schreurs B W, Arts J J, Verdonschot N, Buma P, Slooff T J, Gardeniers J W. Femoral component revision with use of impaction bone-grafting and a cemented polished stem. *J Bone Joint Surg (Am)* 2005; 87: 2499-507.
- Schwarz N, Redl H, Schiesser A, Schlag G, Thurnher M, Lintner F, Dinges H P. Irradiation-sterilization of rat bone matrix gelatin. *Acta Orthop Scand* 1988; 59: 165-7.
- Smith R A, Ingels J, Lochemes J J, Dutkowsky J P, Pifer L L. Gamma irradiation of HIV-1. *J Orthop Res* 2001; 19: 815-9.
- Tagil M, Aspenberg P. Impaction of cancellous bone grafts impairs osteoconduction in titanium chambers. *Clin Orthop* 1998; (352): 231-8.

- Thoren K, Aspenberg P, Thorngren K G. Lipid extracted bank bone. Bone conductive and mechanical properties. *Clin Orthop* 1995; (311): 232-46.
- Van Der Donk S, Weernink T, Buma P, Aspenberg P, Slooff T J, Schreurs B W. Rinsing morselized allografts improves bone and tissue ingrowth. *Clin Orthop* 2003; (408): 302-10.
- Waarsing J H, Day J S, van der Linden J C, Ederveen A G, Spanjers C, De Clerck N, Sasov A, Verhaar J A, Weinans H. Detecting and tracking local changes in the tibiae of individual rats: a novel method to analyse longitudinal in vivo micro-CT data. *Bone* 2004; 34: 163-9.
- Wientroub S, Reddi A H. Influence of irradiation on the osteoinductive potential of demineralized bone matrix. *Calcif Tissue Int* 1988; 42: 255-60.
- Zhang Q, Cornu O, Delloye C. Ethylene oxide does not extinguish the osteoinductive capacity of demineralized bone. A reappraisal in rats. *Acta Orthop Scand* 1997; 68: 104-8.