

## Review

# Reconstruction of the medial patellofemoral ligament for treatment of patellar instability

Martin Lind, Bent W Jakobsen, Bent Lund, and Svend Erik Christiansen

Division of Sports Trauma, Department of Orthopaedics, Aarhus University Hospital, Aarhus, Denmark  
Correspondence ML: martinlind@dadlnet.dk  
Submitted 06-09-17. Accepted 07-11-19

Chronic lateral patella instability is a result of anatomical abnormalities and insufficient soft tissue restraints, and is difficult to treat. The medial patellofemoral ligament (MPFL) is known to be the primary restraint for lateralization of the patella. This ligament is damaged at the primary dislocation and it often heals poorly and thus rarely regains its full function. Reconstruction of the MPFL may therefore be of value for chronic patellar instability and this procedure has gained popularity over the past decade. Here we review the techniques and results of MPFL reconstruction.

### Patellar instability

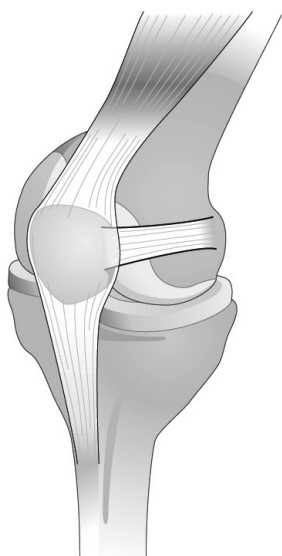
More than 100 surgical procedures have been described for treatment of patellar instability (Hughston 1968, Davis and Fithian 2002). This indicates that no single technique is superior, despite the fact that good results were usually announced in the original descriptions. It also indicates that lateral patellar instability is a multifaceted condition with multiple pathoanatomical variations.

In more than half of the patients, first-time patella dislocation that is left untreated or treated nonoperatively will lead to disability in the form of patellar instability, recurrent dislocations, anterior knee pain, and even femoropatellar osteoarthritis (Hawkins et al. 1986, Maenpaa and Lehto 1997). The natural history of nonoperatively treated patellar dislocation involves redislocation in 1 in 6

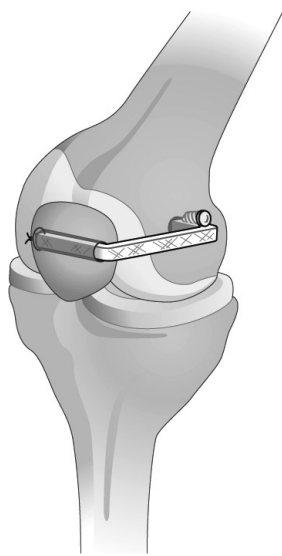
cases, other residual symptoms in 2 of 6 cases, and 3 of 6 cases will be asymptomatic (McManus et al. 1979). The annual incidence of acute patellar dislocation in Finnish children younger than 16 years was found to be 43 cases per 100,000 (Nietosvaara et al. 1994).

In 1 out of 4 patients, there is a family history of patella dislocation. Predisposing factors are dysplasia of the femoropatellar joint, excessive Q-angle, and general joint laxity. Others factors such as patella alta, genu valgum, foot pronation and external tibial torsion, increased femoral anteversion, and poor dynamic function of vastus medius obliquus (VMO) may have additional influence on patellar instability (Scuderi et al. 1988).

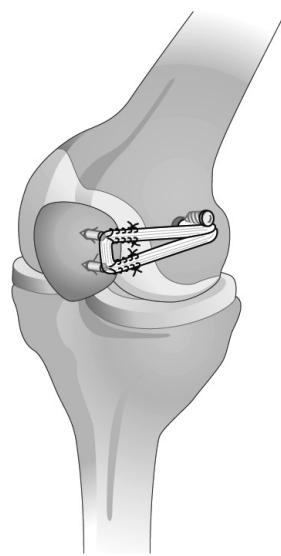
Anatomical studies give a clear description of the medial patellofemoral ligament, which inserts at the proximal two-thirds of the medial patella border and runs posteriorly to the medial adductor tubercle to insert in close relation to the origin of the proximal medial collateral ligament (MCL) and slightly distal to the adductor magnus insertion. The ligament fuses with the vastus medialis obliquus (VMO) aponeurosis. The proximal edge is well defined at the medial adductor tubercle (Tuxoe et al. 2002) (A in the Figure). Among the medial ligamentous retinacular structures (the superficial medial patellar retinaculum, the medial patellofemoral ligament, the medial patellotibial ligament, and the patellomeniscal ligament), the MPFL is the primary medial restraining structure



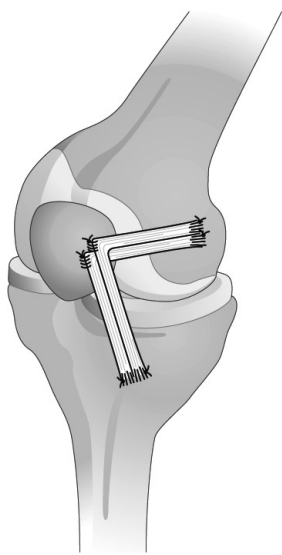
A. The normal MPFL, which inserts at the proximal two-thirds of the medial patella border and runs posteriorly to the medial adductor tubercle to insert in close relation to the proximal MCL insertion and the adductor magnus insertion.



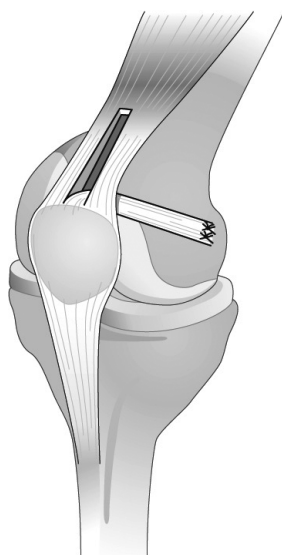
B. MPFL reconstruction with an autograft or allograft tendon fixed in bone canals in both patella and femoral condyle.



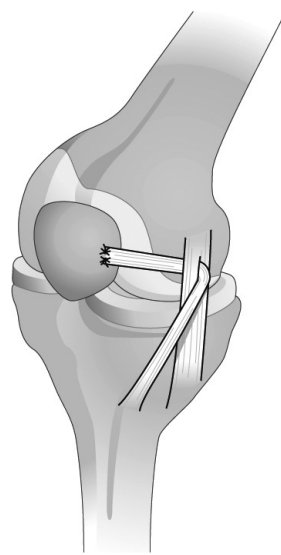
C. MPFL reconstruction avoiding drilling in the patella, using anchor fixation of the semitendinosus graft at the medial aspect of the patella and interference screw in the medial femoral condyle.



D. A technique with combined reconstruction of MPFL and medial patellofemoral ligament. Here semitendinosus and gracilis tendons are folded and sutured to the medial patella edge and medial femoral condyle. A distal limb of the tendon grafts is sutured to the proximal medial tibial periosteum to reconstruct the medial patellofemoral ligament.



E. MPFL reconstruction using the central portion of the quadriceps tendon. The tendon is released proximally and the patella insertion left intact. The tendon flap is passed subcutaneously to the medial femoral condyle, where fixation is performed by osteosutures.



F. MPFL reconstruction with the semitendinosus tendon. The tendon maintains its insertion at the pes anserinus and the proximal end of the tendon is transferred to the femoral insertion of the medial collateral ligament (MCL). The graft is then passed through an incision in the MCL femoral insertion, which subsequently acts as a pulley. Finally, the graft is sutured to the medial aspect of the patella.

towards lateralization of the patella and contributes up to 80% of the lateral restraining forces to the patella (Desio et al. 1998, Hautamaa et al. 1998). Mechanical studies have demonstrated that the MPFL has a strength of 200 N and an ability to stretch up to 26 mm before it ruptures. This indicates that full lateral dislocation of the patella is impossible without rupture of the ligament (Mountney et al. 2005).

In cases of patella dislocation the MPFL is injured in more than 90%, and the point of injury is the femoral attachment site (Sallay et al. 1996, Nomura 1999). The mechanical properties of the MPFL after injury are often insufficient, leading to increased medial laxity of the patella retinacular structures. This can lead to chronic patellar instability, especially in cases with dysplasia of the patellofemoral joint.

The effect of tibial tuberosity transfer (TTT) in the treatment of patellar instability is controversial. A recent *in vitro* study has shown that TTT has limited or no effect on lateral patella stability whereas MPFL reconstruction significantly stabilizes lateral movement of the patella (Ostermeier et al. 2006). A combination of proximal alignment (lateral release and medial retinacular plication) and TTT, the Roux procedure, showed good results with redislocation in 1 out of 25 patients (Peterson et al. 1988), while Myers et al. (1999) found redislocations in 4 out of 42 knees and Cox (1982) found redislocations in 9 of 116 patients. Scuderi et al. (1988) demonstrated a low rate of redislocation (1/52) in patients with isolated proximal realignment.

Based on the fact that most predisposing factors for first-time patella dislocation are static factors, it is surprising that in most of the proximal realignment procedures the intention is to improve the medial dynamic forces—by improving VMO function. The same theory has been applied to the distal realignment procedures. The medial static structures and bony abnormalities have only recently been given some attention.

As mechanical data have shown that the MPFL is the main restraint of patella lateralization and that the ligament is almost always torn in cases of patella dislocation, the treatment of chronic patellar instability with reconstruction of the MPFL seems to be justified. The aim of the procedure is to restore the medial tether of the patella. In this

paper we review the procedures and clinical results of MPFL reconstructions for chronic patellar instability.

### Literature

A PubMed search for medial patellafemoral ligament and reconstruction gave 68 hits. Of these, 23 were clinical studies and 8 papers were related to anatomical or biomechanical investigations. 4 papers were reviews on patellar instability and treatment. The papers that were not related to MPFL surgery mentioned the MPFL in relation to other surgical procedures. Some historical papers are also included in our review.

### Surgical techniques

Numerous different techniques for MPFL reconstruction have been described. All techniques aim to supply tendon tissue from the medial aspect of the patella to the insertion site of the natural MPFL at the adductor tubercle of the medial femoral condyle, in order to reconstruct the ligament. The sources of tendon described are numerous: semitendinosus, gracilis, partial quadriceps, partial semimembranosus, vastus medialis retinaculum, allografts, or artificial tendons. As early as 1992, a method was described with an artificial polyester ligament that was fixed in a transverse drillhole of the patella and subfascially fixed to the medial femoral condyle with a metal screw (Ellera Gomes 1992). Nomura et al. (2000) described a similar technique using an artificial polyester ligament with staple fixation at the femoral condyle (B in the Figure). More recently, several authors have described a similar technique with a free semitendinosus, gracilis, quadriceps, adductor tendon, or a vastus medialis retinaculum autograft (Muneta et al. 1999, Nomura and Inoue 2003, Ellera Gomes et al. 2004, Cossey and Paterson 2005, Steiner et al. 2006).

To avoid drilling in the patella, a technique with anchor fixation of the semitendinosus graft at the medial aspect of the patella and interference screw in the medial femoral condyle has been described (Schottle et al. 2005) (C in the Figure).

Drez et al. (2001) described a technique with combined reconstruction of the MPFL and medial patellatibial ligament. The semitendinosus and gracilis tendons are folded and sutured to the

## Results from clinical studies with MPFL reconstruction

Ref.	Technique	n	Follow-up (yr)	Redislocations	Clinical score
Ellera Gomes 1992	Artificial ligament in patella bone tunnel	30	3	0	Crosby Insall: 84% Good results, except cartilage damage (poor results) 16%
Drez et al. 2001	Various grafts, suture fixation. MPFL + patellofemoral ligament	19	3	1	Kujala: 88
Nomura et al. 2000	Artificial ligament in bone tunnel + staple	27	5–9	1	Crosby Insall: Good/excellent, n = 26
Ellera Gomes et al. 2004	Semitendinosus graft in patella bone tunnel	15	> 5	0	Crosby Insall: Good/excellent, n = 14
Deie et al. 2005	Semitendinosus transfer + lateral release VMO adv	39	5	0	Kujala: 92
Cossey and Paterson 2005	VMO graft Suture fixation Trillat	19	1–3	0	Lysholm: 95
Schottle et al. 2005	Semitendinosus Anchors + screw	15	4	1	Kujala: 87
Steiner et al. 2006	Add auto Suture + bone tunnel	34	2–10	0	Kujala: 90

Kujala score ranges from 0 to 100 with 100 as best results. Lysholm score ranges from 0 to 100 with 100 as best results. Score data are presented as mean score.

medial patella edge and medial femoral condyle. A distal limb of the tendon grafts is sutured to the proximal medial tibial periosteum to reconstruct the medial patellofemoral ligament (D in the Figure).

Another technique using the central portion of the quadriceps tendon has been described by Steensen et al. (2005). The tendon is released proximally and the patella insertion left intact. The tendon flap is passed subcutaneously to the medial femoral condyle, where fixation is performed by osteosutures (E in the Figure).

Deie et al. (2005) described a technique for children with mobilization of the semitendinosus tendon. The tendon maintains its insertion at the pes anserinus and the proximal end of the tendon is transferred to the femoral insertion of the MCL. The graft is then passed through an incision in the MCL femoral insertion, which subsequently acts as a pulley. Finally, the graft is sutured to the medial aspect of the patella. This technique does not involve bony drilling and is thus feasible in children (F in the Figure).

A critical aspect of MPFL reconstruction is achievement of isometry of the reconstruction during range of motion. Typically, an isometry test is performed before drilling or fixation in the femoral condyle. The femoral isometric point is identified using a suture or wire placed in the suggested reconstruction positions and then repetitive knee flexion and extension are performed to test isometry. Special care is taken to avoid excessive tension in flexion, since this can lead to cartilage overload and subsequent accelerated cartilage wear. The isometric point at the femoral condyle is usually located just distal to the adductor tubercle (Nomura et al. 2000).

#### Clinical results

In general, MPFL reconstructions have achieved very good patella stability with no redislocations in 5 of 8 studies and redislocation rates of less than 10% in 3 studies (Table). Also, success rates based on Kujala clinical scoring were generally high with score values around 80–90 of 100 possible.

One study demonstrated poorer outcome in patients with cartilage damage at the time of surgery (Ellera Gomes 1992). Although several operative techniques and choices of graft are described in the different studies, choice of graft and technique does not seem to influence the clinical results. Regarding complications, a patella fracture is described in the study by Ellera Gomes. In this study, an excessive drill canal diameter in the patella (7 mm) with violation of the anterior cortex was thought to be the cause of the patella fracture. In the study by Steiner et al. (2006) involving 34 patients, one patient developed a granuloma due to graft loosening following a traffic accident and three patients required screw removal due to local inflammation.

In the study by Nomura et al. (2000), where staples were used for femoral fixation, 11 out of 25 patients had localized pain at the staple sites.

Early use of artificial ligaments for MPFL reconstructions was later abandoned in favor of different autograft ligaments, despite the fact that no complications related to the artificial ligament grafts were described in the studies. The problems after intra-articular use of artificial ligaments probably lead surgeons to abandon the artificial ligaments for MPFL reconstruction (Murray and Macnicol 2004). One author was concerned about the excessive stiffness of the artificial ligaments compared to biological grafts (Ellera Gomes et al. 2004).

### Conclusion

Extensive anatomical studies of lesions in the MPFL after primary patella dislocation have indicated that in most cases the ligament is injured at the femoral insertion site, and similar studies in individuals with chronic patella dislocation have shown insufficient healing of the ligament in most of these patients (Nomura 1999). The mechanical importance of the MPFL has been demonstrated in *in vitro* studies on cadavers, where isolated injury to the MPFL was found to increase lateral patellar instability by 50% and reconstruction of the MPFL was necessary to restore normal lateral patella mobility (Hautamaa et al. 1998).

The various studies involving MPFL reconstruction have generally shown good clinical results. Most of these studies have not demonstrated any recurrence of dislocation and in the remaining

studies the redislocation rates were less than 7%, which must be considered successful in comparison to other patella stabilizing surgical procedures where redislocation rates of 10–35% have been described (Davis and Fithian 2002).

Complications that have been reported are local inflammation at screwholes and staples at the femoral condyle insertion. One serious complication with patella fracture was related to transverse patella drillhole technique, where the drill accidentally violated the anterior cortex of the patella (Ellera Gomes 1992). More recent techniques without patella drilling have been developed to avoid patella fractures (Schottle et al. 2005).

Acute and chronic repair of the MPFL has been attempted in several studies. Sallay et al. (1996) found no recurrence of patella dislocation in 16 patients with acute repair of the MPFL after a minimum of 2 years of follow-up. Vainionpaa et al. (1990) found 6 redislocations in 55 patients 2 years after acute MPFL repair. More than half of the patients also had lateral release performed. Only one randomized clinical trial has been conducted (Nikku et al. 1997). In that study, 125 patients were randomized to either individualized proximal realignment surgery or conservative brace treatment. No difference in patellar instability and clinical outcome was found, but recurrence of dislocation or instability occurred in 25% of operated patients and in 36% of the patients who were not operated. The study has, however, been criticized for unclear description of the MPFL repair technique and the use of additional procedures—especially lateral release—without clear indications (Davis and Fithian 2002). In general, these studies indicate that attempts to perform acute repair of the medial soft tissue or MPFL gives poorer results than reconstruction of the MPFL.

Procedures that are additional to MPFL repair or reconstruction are frequently performed, lateral retinacular release and tibial tuberosity transfers being the most frequent. Lateral release is typically performed with the argument that a tight lateral retinaculum adds to lateral tracking of the patella. However, there have been *in vitro* studies demonstrating that the lateral retinaculum is generally not important for lateralization of the patella after dislocation. On the contrary, the medial laxity due to MPFL lesion seems to be the main mechani-

cal problem, which suggests that the lateral release procedure is of limited value (Christoforakis et al. 2006).

Different anatomical abnormalities may be taken as indications for additional procedures such as trochlea dysplasia, increased Q-angle, or patella alta. These anatomical problems can be addressed with trochleaplasty to correct for lack of bony lateral restraints, and with tibial tuberosity transfers to obtain a more straight mechanical axis for the extensor apparatus. However, there have been no studies documenting any favorable effects of procedures additional to MPFL reconstruction.

In conclusion, MPFL reconstruction is a promising surgical treatment for chronic patellar instability. Randomized studies are required to compare the efficacy of MPFL reconstruction with proximal alignment techniques and tibial tuberosity transfers. In addition, the value of combined procedures such as lateral release and tibial tuberosity transfer must be confirmed.

- Christoforakis J, Bull A M, Strachan R K, Shymkiw R, Senavongse W, Amis A A. Effects of lateral retinacular release on the lateral stability of the patella. *Knee Surg Sports Traumatol Arthrosc* 2006; 14: 273-7.
- Cossey A J, Paterson R. A new technique for reconstructing the medial patellofemoral ligament. *Knee* 2005; 12: 93-8.
- Cox J S. Evaluation of the Roux-Elmslie-Trillat procedure for knee extensor realignment. *Am J Sports Med* 1982; 10: 303-10.
- Davis D K, Fithian D C. Techniques of medial retinacular repair and reconstruction. *Clin Orthop* 2002; (402): 38-52.
- Deie M, Ochi M, Sumen Y, Adachi N, Kobayashi K, Yasumoto M. A long-term follow-up study after medial patellofemoral ligament reconstruction using the transferred semitendinosus tendon for patellar dislocation. *Knee Surg Sports Traumatol Arthrosc* 2005; 13: 522-8.
- Desio S M, Burks R T, Bachus K N. Soft tissue restraints to lateral patellar translation in the human knee. *Am J Sports Med* 1998; 26: 59-65.
- Drez D, Jr., Edwards T B, Williams C S. Results of medial patellofemoral ligament reconstruction in the treatment of patellar dislocation. *Arthroscopy* 2001; 17: 298-306.
- Ellera Gomes J L. Medial patellofemoral ligament reconstruction for recurrent dislocation of the patella: a preliminary report. *Arthroscopy* 1992; 8: 335-40.
- Ellera Gomes J L, Stigler Marczyk L R, Cesar d C, Jungblut C F. Medial patellofemoral ligament reconstruction with semitendinosus autograft for chronic patellar instability: a follow-up study. *Arthroscopy* 2004; 20: 147-51.
- Hautamaa P V, Fithian D C, Kaufman K R, Daniel D M, Pohlmeier A M. Medial soft tissue restraints in lateral patellar instability and repair. *Clin Orthop* 1998; (349): 174-82.
- Hawkins R J, Bell R H, Anisette G. Acute patellar dislocations. The natural history. *Am J Sports Med* 1986; 14: 117-20.
- Hughston J C. Subluxation of the patella. *J Bone Joint Surg (Am)* 1968; 50: 1003-26.
- Maenpaa H, Lehto M U. Patellar dislocation. The long-term results of nonoperative management in 100 patients. *Am J Sports Med* 1997; 25: 213-7.
- McManus F, Rang M, Heslin D J. Acute dislocation of the patella in children. The natural history. *Clin Res* 1979; (139): 88-91.
- Mountney J, Senavongse W, Amis A A, Thomas N P. Tensile strength of the medial patellofemoral ligament before and after repair or reconstruction. *J Bone Joint Surg (Br)* 2005; 87: 36-40.
- Muneta T, Sekiya I, Tsuchiya M, Shinomiya K. A technique for reconstruction of the medial patellofemoral ligament. *Clin Orthop* 1999; (359): 151-5.
- Murray A W, Macnicol M F. 10-16 year results of Leeds-Keio anterior cruciate ligament reconstruction. *Knee* 2004; 11: 9-14.
- Myers P, Williams A, Dodds R, Bulow J. The three-in-one proximal and distal soft tissue patellar realignment procedure. Results, and its place in the management of patellofemoral instability. *Am J Sports Med* 1999; 27: 575-9.
- Nietosvaara Y, Aalto K, Kallio P E. Acute patellar dislocation in children: incidence and associated osteochondral fractures. *J Pediatr Orthop* 1994; 14: 513-5.
- Nikku R, Nietosvaara Y, Kallio P E, Aalto K, Michelsson J E. Operative versus closed treatment of primary dislocation of the patella. Similar 2-year results in 125 randomized patients. *Acta Orthop Scand* 1997; 68: 419-23.
- Nomura E. Classification of lesions of the medial patellofemoral ligament in patellar dislocation. *Int Orthop* 1999; 23: 260-3.
- Nomura E, Inoue M. Surgical technique and rationale for medial patellofemoral ligament reconstruction for recurrent patellar dislocation. *Arthroscopy* 2003; 19: E47.
- Nomura E, Horiuchi Y, Kihara M. A mid-term follow-up of medial patellofemoral ligament reconstruction using an artificial ligament for recurrent patellar dislocation. *Knee* 2000; 7: 211-5.
- Ostermeier S, Stukenborg-Colsman C, Hurschler C, Wirth C J. In vitro investigation of the effect of medial patellofemoral ligament reconstruction and medial tibial tuberosity transfer on lateral patellar stability. *Arthroscopy* 2006; 22: 308-19.
- Peterson L, Karlsson J, Brittberg M. Patellar instability with recurrent dislocation due to patellofemoral dysplasia. Results after surgical treatment. *Bull Hosp Jt Dis Orthop Inst* 1988; 48: 130-9.
- Sallay P I, Poggi J, Speer K P, Garrett W E. Acute dislocation of the patella. A correlative pathoanatomic study. *Am J Sports Med* 1996; 24: 52-60.

- Schottle P B, Fucentese S F, Romero J. Clinical and radiological outcome of medial patellofemoral ligament reconstruction with a semitendinosus autograft for patella instability. *Knee Surg Sports Traumatol Arthrosc* 2005; 13: 516-21.
- Scuderi G, Cuomo F, Scott W N. Lateral release and proximal realignment for patellar subluxation and dislocation. A long-term follow-up. *J Bone Joint Surg (Am)* 1988; 70: 856-61.
- Steensen R N, Dopirak R M, Maurus P B. Minimally invasive “crescentic” imbrication of the medial patellofemoral ligament for chronic patellar subluxation. *Arthroscopy* 2005; 21: 371-5.
- Steiner T M, Torga-Spak R, Teitge R A. Medial patellofemoral ligament reconstruction in patients with lateral patellar instability and trochlear dysplasia. *Am J Sports Med* 2006; 34: 1254-61.
- Tuxoe J I, Teir M, Winge S, Nielsen P L. The medial patellofemoral ligament: a dissection study. *Knee Surg Sports Traumatol Arthrosc* 2002; 10: 138-40.
- Vainionpaa S, Laasonen E, Silvennoinen T, Vasenius J, Rokkanen P. Acute dislocation of the patella. A prospective review of operative treatment. *J Bone Joint Surg (Br)* 1990; 72: 366-9.