

Supplementary pedicle screw fixation in spinal fusion for degenerative spondylolisthesis in patients aged 65 and over

Outcome after a minimum of 2 years follow-up in 82 patients

Chin-Hsien Wu^{1,2}, Yu-Hsien Kao^{1,2}, Shih-Chieh Yang^{1,2}, Tsai-Sheng Fu¹, Po-Liang Lai¹, and Wen-Jer Chen¹

Departments of Orthopaedics, ¹Chang Gung Memorial Hospital and College of Medicine, Chang Gung University, Taoyuan, Taipei, ²E-DA Hospital and I-Shou University, Kaohsiung, Taiwan
Correspondence WJC: chenwenj@adm.cgmh.org.tw
Submitted 06-12-09. Accepted 07-07-29

Background There have been few reports assessing the outcome of laminectomy and posterolateral fusion with pedicle screw fixation for degenerative spondylolisthesis in the elderly. In a retrospective study, we assessed the clinical and radiographic outcome of this treatment in degenerative spondylolisthesis patients aged ≥ 65 years.

Patients and methods 82 patients (61 females) aged ≥ 65 years underwent laminectomy and posterolateral fusion with pedicle screw fixation for degenerative spondylolisthesis. The median age at surgery was 69 (65–79) years. The mean bone mineral density before surgery was -1.9 (-1.0 to -2.5). After an average of 3 (2–11) years follow-up, patients were classified as “satisfied” or “dissatisfied” according to self-reported outcomes and also as “solid fusion” or “no solid fusion” according to the radiographic findings.

Results At final follow-up, the average Oswestry disability index (ODI) score was lower than the preoperative score (30 vs. 56) ($p = 0.03$). Four-fifths of the patients stated that they were satisfied with the outcome. Almost three-quarters of the patients achieved definite fusion. Although patients with advanced age or reduced bone mineral density were not more likely to have dissatisfactory results ($p = 0.8$ and $p = 0.6$, respectively) they were more likely to have radiographic results showing “absence of solid fusion” ($p = 0.005$ and $p < 0.001$, respectively).

Interpretation We believe that supplementary pedicle screw fixation after laminectomy and posterolateral

fusion will be an effective choice for the ever-increasing number of patients aged ≥ 65 years who will be prone to develop degenerative spondylolisthesis. ■

Degenerative spondylolisthesis is secondary to degenerative osteoarthritis of the disc and facet joints of the involved segments (Matsunaga et al. 1990), and is the most common spondylolisthesis type in the elderly.

Advances in surgical technique and perioperative patient management coupled with a rapid increase in people aged ≥ 65 years (WHO 2003) have led to a substantial increase in the number of spinal fusion procedures. Between 1979 and 1988, the use of lumbar decompression in Americans aged ≥ 65 years increased by 80%. The incidence of fusion surgery employed for this age group increased by 450% (NASS 1994). Deyo et al. (1992), who analyzed the Washington State Hospital discharge registry, reported an increase in complications after spinal fusion surgery, particularly in patients aged > 64 years; the complication rates increased as patient age increased. Osteoporosis-related complications, such as pseudarthrosis and screw loosening, were also cited as a significant issue. However, Conley et al. (1990) proposed that patients aged ≤ 60 years had a 50% likelihood of

achieving an excellent outcome and patients > 60 years had an 80% likelihood of achieving an excellent outcome.

In this retrospective study, we analyzed the outcome of laminectomy and posterolateral fusion with pedicle screw fixation in degenerative spondylolisthesis patients aged \geq 65 years and determined the factors affecting the outcome.

Patients and methods

Between 1995 and 2002, 99 patients aged \geq 65 years underwent laminectomy and posterolateral fusion with pedicle screw fixation for degenerative spondylolisthesis in our department. Before surgery, repeated clinical and neurologic examinations and image investigations, including plain radiographs and myelograms, or MRI were performed in all patients. Patients were considered for surgery only after nonoperative treatment, including physiotherapy, oral analgesics and non-steroidal anti-inflammatory drugs, epidural steroids and facet injection, and home exercise had proved unsuccessful. Patients with malnutrition (serum albumin level < 3.0 g/dL) or high cardiac risk were not considered for surgery. Of the 99 patients, 17 were lost to follow-up. The remaining 82 patients (61 females) had a median age at surgery of 69 years (65–79) years. Spondylolisthesis occurred at one level in 44 patients and at two levels in 38 patients. 19 patients had a fusion to the sacrum.

Average operative time was 172 (120–256) min. Average blood loss during surgery was 555 (200–1200) mL. Average hospital stay was 8 (7–28) days. Pedicle screw instrumentation included TriFix G (Aspine, Oakland, CA) in 25 patients, IQL (A-spine, Taiwan) in 45 patients, and ISOLA (AcroMed, Cleveland, OH) in 12 patients. Follow-up examinations were performed at 3 months, 6 months, 1 year, and annually thereafter. All patients attended follow-up examinations for a minimum of 2 years. The mean follow-up time was 3 (2–11) years.

Clinical assessment

At each follow-up visit, the clinical result and complications were evaluated and a radiographic assessment was performed. The Oswestry disability index (ODI) questionnaire was used preoperatively

and at the final follow-up. The mean number of comorbidities was 0.6 (0–3). Preoperative comorbidities included hypertension, diabetes mellitus, old cerebrovascular accident, cancer, asthma, and rheumatoid arthritis.

Radiographic assessment

Bone mineral density (BMD) was measured by dual-energy X-ray absorptiometry (DEXA) scans and presented as T-scores. The mean bone mineral density before surgery was -1.9 (-1.0 to -2.5). Fusion status was assessed using plain radiographs, including flexion-extension films. Solid fusion was defined as visible, continuous trabeculae of bridging fusion masses over the bilateral transverse processes and no motion in flexion and extension on stress radiographs. Probable fusion was defined as unclear bony trabecular continuity with no radiolucent interruption or motion in stress radiographs. Radiolucent interruption of the fusion mass was labeled pseudarthrosis.

At final follow-up, patients were classified as “satisfied” or “dissatisfied” according to self-reported outcomes, and also as “solid fusion” or “no solid fusion” according to the radiographic findings. Factors such as age, sex, BMD, grade of spondylolisthesis, fused segments, fused to the sacrum, preoperative ODI scores, presence of comorbidity, and absence of solid fusion were examined.

Statistics

Data were analyzed using the SPSS statistical software package. The ODI scores were compared preoperatively and at final follow-up using paired t-tests. Age, preoperative ODI scores, and BMD were compared between groups by independent t-tests. Patient sex, grade of spondylolisthesis, fused segments, fusion to the sacrum, presence of comorbidity, and absence of solid fusion were compared by Fisher’s exact test. A two-tailed value of $p < 0.05$ was considered statistically significant.

Results

Clinical outcome

Oswestry disability index scores. At final follow-up, the average ODI score was lower than the preoperative score (30 vs. 56) ($p = 0.03$). Of the 82

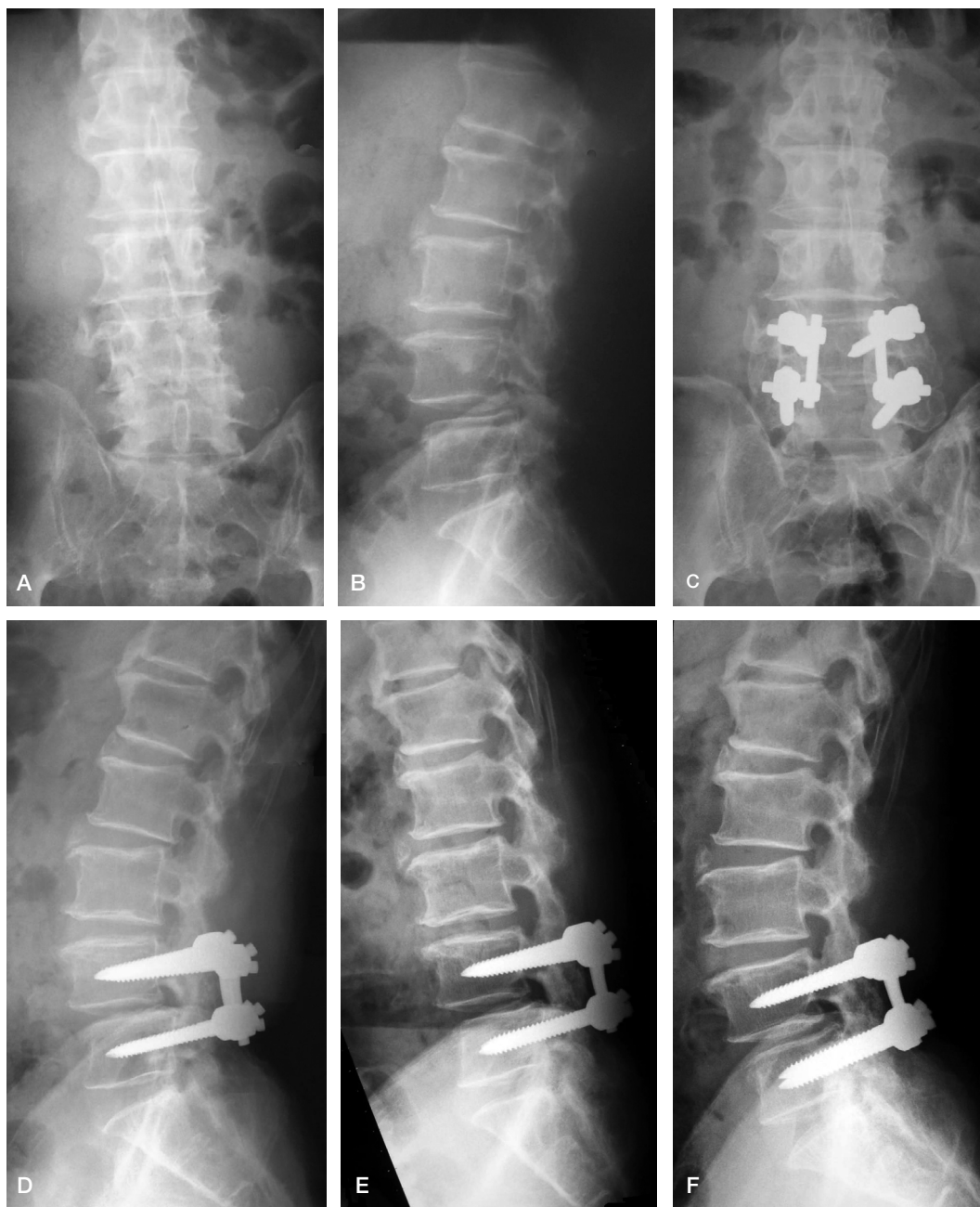

Figure 1. A 67-year-old man. Preoperatively, anteroposterior (A) and lateral (B) views showing degenerative spondylolisthesis at L4/L5. Two years postoperatively, anteroposterior (C), lateral (D), flexion (E) and extension (F) views showed stable implants, solid fusion, and no motion in flexion and extension on stress radiographs.

patients, 71 achieved greater than 25% improvement in ODI scores.

Patient satisfaction. 41/82 patients had satisfactory results, 24 reported that they were somewhat satisfied, 8 were somewhat dissatisfied, and 9 were

dissatisfied. 61 patients stated that they would undergo the same treatment and 21 patients stated that they would not. 65 patients were assigned to the “satisfied” group and 17 were assigned to the “dissatisfied” group.

Radiographic outcome

At final follow-up, 62/82 patients had fusion, 19 patients had a probable fusion, and 1 had a pseudarthrosis.

Complications

No deaths occurred. No major medical complications (acute myocardial infarction, cerebrovascular accident, pneumonia, etc.) were noted perioperatively. There were 2 deep infections and 1 superficial infection. All infections were eradicated. 1 patient had persistent pain over the bone graft donor site for 2 years. 3 patients underwent implant removal because of pain. 2 patients had dislodged rods and 2 patients had loosened screws that did not back out. Only 2 patients had degeneration of an adjacent segment.

We also attempted to determine what factors were predictive of a “dissatisfied” or “no solid fusion” result. Factors such as age, sex, BMD, grade of spondylolisthesis, fused segments, fusion to the sacrum, preoperative ODI scores, presence of co-morbidity, and absence of solid fusion were analyzed. When factors were compared between satisfied and dissatisfied groups (Table 1), patients with higher preoperative ODI scores were more likely to be dissatisfied ($p = 0.08$). Although patients with advanced age or less BMD were not more likely to have expressed dissatisfaction ($p = 0.8$ and $p = 0.6$, respectively) they were more likely to have absence of solid fusion as their radiographic result ($p = 0.005$ and $p < 0.001$, respectively) when factors were compared between the groups with solid fusion and no solid fusion (Table 2).

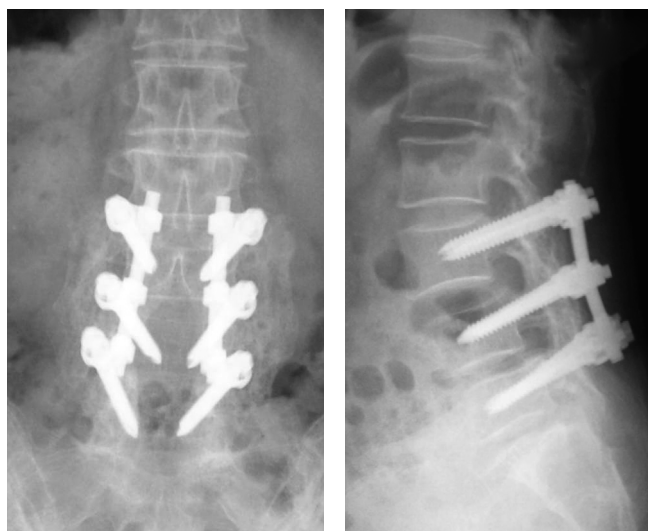


Figure 2. A 72-year-old woman with degenerative spondylolisthesis at L3/L4 and L4/L5. Two years postoperatively, anteroposterior (A) and lateral (B) views showed stable implants and solid fusion.

Table 1. Factors that may be predictive of a “dissatisfied” result

	Satisfied (n = 65)	Dissatisfied (n = 17)	P-value
Mean age	69	70	0.8 ^a
Sex (female)	46	15	0.2 ^b
Mean BMD (T-score)	-1.87	-1.82	0.6 ^a
Grade of spondylolisthesis (grade 2)	20	4	0.8 ^b
Fused segment (two segments)	31	7	0.8 ^b
Mean preoperative ODI scores	55	60	0.08 ^a
Co-morbidity	32	10	0.6 ^b
Fusion to the sacrum	13	6	0.2 ^b
Not solid fusion	17	3	0.5 ^b

^a Independent t-test.
^b Fisher's exact test.

Table 2. Factors that may be predictive of a “not solid fusion” result

	Solid (n = 62)	Not solid (n = 20)	P-value
Mean age	69	71	0.005 ^a
Sex (female)	48	13	0.4 ^b
Mean BMD (T-score)	-1.78	-2.11	< 0.001 ^a
Grade of spondylolisthesis (grade 2)	17	7	0.6 ^b
Fused segment (two segments)	30	8	0.6 ^b
Mean preoperative ODI scores	56	55	0.6 ^a
Co-morbidity	36	8	0.2 ^b
Fusion to the sacrum	15	4	1.0 ^b

^a Independent t-test.
^b Fisher's exact test.

Discussion

Failure of nonoperative treatment, neurological deficit, and severe neurogenic claudication are indications for surgical treatment in patients with degenerative spondylolisthesis: laminectomy only (Caputy and Luessenhop 1992), laminectomy with spinal fusion (Herkowitz and Kurz 1991), or laminectomy with spinal fusion and instrumentation (Hirabayashi et al. 1991).

Some authors have recommended laminectomy alone for the elderly. In elderly patients, decompression is the most important factor when relieving symptoms, and the addition of a spinal fusion will increase the postoperative morbidity. Herron and Trippi (1989) also proposed that fusion is unnecessary; it can be reserved as a second-stage procedure. Kirkaldy-Willis et al. (1974) recommended a combination of fusion and decompression for patients less than 55 years of age. In proposing the same principle, Wiltse et al. (1976) raised the age limit for spinal fusion from 55 years to 65 years.

Mardjetko et al. (1994) performed a meta-analysis of the literature from 1970 to 1993, and reviewed 25 studies comprising 889 spondylolisthesis patients with stenosis. They found that laminectomy alone increased the risk of translational instability, frequently resulting in severe pain due to instability. Kaneda et al. (1986) suggested performing spinal fusion following decompression for all cases. Bridwell et al. (1993) reported that when properly performed, pedicle screw fixation prevents progression of spondylolisthesis, maintains preoperative sagittal alignment, and gives a high fusion rate. An animal study by McAfee et al. (1989) demonstrated that spinal instrumentation can increase the fusion rate in the destabilized canine lumbar spine. Numerous questions have been raised about the use of pedicle screw fixation. One such question is whether pedicle screw fixation offers a substantial advantage over spinal fusion without pedicle screw fixation. In comparative studies, Zdeblick (1993) demonstrated the clinical and radiographic superiority of arthrodesis with supplementary pedicle screw fixation. France et al. (1999) found no major benefit, and Fischgrund et al. (1997) found no major clinical benefit, but rather a higher rate of radiographic arthrodesis with pedicle screw fixation. However, few authors

have assessed the outcome of laminectomy and posterolateral fusion with pedicle screw fixation in degenerative spondylolisthesis in patients aged ≥ 65 years.

There are two principal concerns when performing spinal fusion surgery with pedicle screw fixation in the elderly: (1) an increase in the number and severity of co-morbidities resulting in a high rate of morbidity and mortality postoperatively, and (2) osteoporosis-related complications such as pseudoarthrosis and screw loosening/pull-out because of osteopenia, which was diagnosed in 50% of the women aged ≥ 65 years by dual-energy X-ray absorptiometry scans in Taiwan (Tsai et al. 1991). Stoll et al. (1993) demonstrated that for patients aged 60–85 years, advancing age had no effect on the mortality rates associated with decompression. In men aged > 71 years, however, advancing age increased the mortality rate for spinal fusion because of an increase in the number of medical co-morbidities in these patients. Deyo et al. (1992) reported an increase in complications after spinal fusion surgery, particularly among patients over 64 years of age. Ramirez and Thisted (1989) found that lumbar spinal fusion for patients aged ≥ 60 years is associated with greater postoperative morbidity, mortality, and inpatient use of resources than spinal surgery without lumbar fusion. Additional pedicle fixation in the lumbar spinal fusion procedure seems to increase the complication rate.

In our study, all patients were at least 65 years old. Laminectomy, posterolateral fusion, and pedicle screw fixation were performed during the same operation for elderly patients. Internal fixation enhances stability and facilitates an accelerated rehabilitation program that benefits older patients. The reduction in mean ODI scores at final follow-up relative to the preoperative scores was 44%. Four-fifths of patients stated that they were satisfied with their surgical outcome and three-quarters said that they would undergo the same treatment again. Almost three-quarters of patients achieved definite fusion. However, there was no correlation between presence of solid fusion and patient satisfaction. The final result of instrumented posterolateral fusion for degenerative spondylolisthesis is undoubtedly multifactorial. Many studies have reported that successful fusion does not influence patient outcome (Fischgrund et al. 1997,

France et al. 1999). Many patients with low back pain fail to improve following successful lumbar fusion (Gibson et al. 1999). Instrumented posterior lumbar interbody fusion (PLIF) has recently become the popular procedure for patients with degenerative lumbar spine disease, to resolve this condition (Steffee and Brantigan 1993). The advantages of instrumented circumferential (360°) fusion are not only higher fusion rates (> 95%) than with posterolateral fusion (Gertzbein et al. 1996), but also removal of the disc as a source of pain (Hee et al. 2001). Instrumented PLIF, an alternative circumferential fusion that uses a single posterior approach, is performed to achieve anterior support and restore disc height, lumbar lordosis, and spinal mechanics (Wang et al. 2005). Instrumented PLIF seems to be the panacea for degenerative lumbar spine diseases. However, further studies should be designed to address this issue. Sagittal alignment also plays an important role in the result of instrumented posterolateral fusion. Generally speaking, lordosis in the elderly should not be compared to that in young adults; instead, proper balance and C7 plumb line are more important. To the best of our knowledge, there have been very few published reports on changes in sagittal balance following elderly lumbar spinal instrumentation and fusion. Kim et al. (2006) reported that a sagittal Cobb angle difference between lumbar lordosis and thoracic kyphosis of > 20° is advisable in most circumstances in order to achieve optimal sagittal balance. We believe that further study is required to address this issue.

Although no statistically significant difference in preoperative ODI scores between satisfied and dissatisfied groups existed, there was a trend toward higher preoperative ODI scores in the dissatisfied group. Although there was no difference in age and BMD between patients in the satisfied group and those in the dissatisfied group, there was a trend toward advanced age and lower BMD in the group without solid fusion. The complication rate was not as high as generally thought. The incidence of degeneration of an adjacent segment in these elderly patients was also lower than in our previous study on the general population (Lai et al. 2004). No perioperative deaths occurred. No major complications such as pneumonia, cardiovascular accident, myocardial infarction, pulmonary embolism, or deep vein thrombosis were observed.

The bias related to patient selection should be noted, however, because patients with malnutrition (i.e. a serum albumin level of < 3.0 g/dL) or high cardiac risk were not considered for surgery.

As life expectancy increases and surgical technique and perioperative patient management advance, spinal fusion in patients aged ≥ 65 years has increased. We propose that supplementary pedicle screw fixation after laminectomy and posterolateral fusion for degenerative spondylolisthesis will be an effective choice in patients in this age group. Although no equivalent group exists to which this series can be compared, this study has demonstrated significant clinical improvement in ODI scores and a relatively high rate of satisfaction and fusion together with a relatively low complication rate.

Age alone is not a contraindication for laminectomy and posterolateral fusion with pedicle screw fixation in degenerative spondylolisthesis patients.

Contributions of authors

CHW collected data and wrote the manuscript. YHK and SCY reviewed medical records and radiographs. TSF and PLL helped in writing the manuscript. WJC led the study and revised the manuscript.

Bridwell K H, Sedgewick T A, O'Brien M F, et al. The role of fusion and instrumentation in the treatment of degenerative spondylolisthesis with spinal stenosis. *J Spinal Disord* 1993; 6: 461-72.

Caputy A J, Luessenhop A J. Long-term evaluation of decompressive surgery for degenerative lumbar stenosis. *J Neurosurg* 1992; 77: 669-76.

Conley F K, Cady C T, Lieberson R E. Decompression of lumbar spinal stenosis and stabilization with Knodt Rods in the elderly patient. *Neurosurgery* 1990; 26: 758-63.

Deyo R A, Cherkin D C, Loeser J D, et al. Morbidity and mortality in association with operations on the lumbar spine. The influence of age, diagnosis, and procedure. *J Bone Joint Surg (Am)* 1992; 74: 536-43.

Fischgrund J S, Mackay M, Herkowitz H N, et al. 1997 Volvo Award Winner in clinical studies. Degenerative lumbar spondylolisthesis with spinal stenosis: a prospective, randomized study comparing decompressive laminectomy and arthrodesis with and without spinal instrumentation. *Spine* 1997; 22: 2807-12.

France J C, Yaszemski M J, Cain J E, et al. A randomized prospective study of posterolateral lumbar fusion: outcomes with and without pedicle screw instrumentation. *Spine* 1999; 24: 553-60.

- Gertzbein S D, Betz R, Clements D et al. Semirigid instrumentation in the management of lumbar spinal conditions combined with circumferential fusion: a multicenter study. *Spine* 1996; 21 (16): 1918-25.
- Gibson J N, Grant I C, Waddell G. The Cochrane review of surgery for lumbar disc prolapse and degenerative lumbar spondylosis. *Spine* 1999; 24 (17): 1820-32.
- Hee H T, Castro F P Jr, Majd M E et al. Anterior /posterior lumbar fusion versus transforaminal lumbar interbody fusion: analysis of complications and predictive factors. *J Spinal Disord* 2001; 14 (6): 533-40.
- Herkowitz H W, Kurz L T. Degenerative lumbar spondylolisthesis with spinal stenosis. *J Bone Joint Surg (Am)* 1991; 73: 802-8.
- Herron L D, Trippi A C. L4-5 degenerative spondylolisthesis: the results of treatment by decompressive laminectomy without fusion. *Spine* 1989; 14: 534-8.
- Hirabayashi S, Kumano K, Kuroki T. Cotrel Dubousset pedicle screw system for various spinal disorders. *Spine* 1991; 16: 1298-304.
- Kaneda K, Kazama H, Satoh S, et al. Follow-up study of medial facetectomies and posterolateral fusion with instrumentation in unstable degenerative spondylolisthesis. *Clin Orthop* 1986; (203): 159-67.
- Kim Y J, Bridwell K H, Lenke L G et al. An analysis of sagittal spinal alignment following long adult lumbar instrumentation and fusion to L5 or S1: can we predict ideal lumbar lordosis? *Spine* 2006; 31 (20): 2343-52.
- Kirkaldy-Willis W H, Paine W E, Couchoix J. Lumbar spinal stenosis. *Clin Orthop* 1974; (99): 30-50.
- Lai P L, Chen L H, Niu C C et al. Relation between laminectomy and development of adjacent segment instability after lumbar fusion with pedicle fixation. *Spine* 2004; 29: 2527-32.
- Mardjetko S M, Connolly P J, Shott S. Degenerative lumbar spondylolisthesis: A meta-analysis of literature 1970-1993. *Spine* 1994; 19: 2256S-65S.
- Matsunaga S, Sakou T, Morizono Y, et al. Natural history of degenerative spondylolisthesis: Pathogenesis and natural course of the sliplpage. *Spine* 1990; 15: 1204-10.
- McAfee P C, Farey I D, Sutterlin C E, et al. 1989 Volvo Award in basic science. Device-related osteoporosis with spinal instrumentation. *Spine* 1989; 14: 919-26.
- North American Spine Society Outcome survey form. Presented at the ninth annual meeting of the North American Spine Society. Minneapolis, MN, October 1994.
- Ramirez L F, Thisted R. Using a national health care base to determine surgical complications in community hospitals. Lumbar disectomy as an example. *Neurosurgery* 1989; 25: 218-25.
- Steffee A D, Brantigan J W. The variable screw placement spinal fixation system. Report of a prospective study of 250 patients enrolled in Food and Drug Administration clinical trials. *Spine* 1993; 18: 1160-72.
- Stoll J E, Oldridge N B, Juan Z, et al. Surgery benefits lifespan. *Orthopedics Today* 1993; 2: 22-3.
- Tsai K S, Huang K H, Chieng P U, et al. Bone mineral density of normal chinese women in Taiwan. *Calcif Tissue Int* 1991; 48: 161-6
- Wang J C, Mummaneni P V, Haid R W. Current treatment strategies for the painful lumbar motion segment: posterolateral fusion versus interbody fusion. *Spine* 2005; 30 (16): 33S-43S.
- Wiltse L L, Kirkaldy-Willis W H, McIvor G W. The treatment of spinal stenosis. *Clin Orthop* 1976; (115): 83-91.
- World health organization (WHO) regional office for the Western Pacific. Ageing and Health: A Health Promotion Approach for Developing Countries. 2003.
- Zdeblick T A. A prospective, randomized study of lumbar fusion: preliminary results. *Spine* 1993; 18: 983-91.