

From the Division of Orthopedic and Trauma Surgery,  
Department of Surgery, Oulu University Hospital,  
University of Oulu  
Oulu, Finland

**Stability-based classification for ankle fracture management  
and the syndesmosis injury in ankle fractures due to a  
supination external rotation mechanism of injury**

**Harri Pakarinen**

UNIVERSITY of OULU  
OULUN YLIOPISTO



---

ACTA ORTHOPAEDICA SUPPLEMENTUM NO. 347, VOL. 83, 2012

**informa**  
healthcare

## Contact address

---

Harri Juhani Pakarinen, MD  
Division of Orthopedic and Trauma Surgery,  
Department of Surgery,  
Oulu University Hospital  
FI 90029 OYS  
Oulu, Finland  
E-mail: harri.pakarinen@ppshp.fi

*No financial support or conflict of interests*

Copyright © Informa Healthcare Ltd 2012. ISSN 1745–3674. Printed in England – all rights reserved  
Cover illustration: “Talar shift or not.” Design by Petri Pirnes  
This supplement is based on the Doctoral thesis by Harri Juhani Pakarinen  
*DOI 10.3109/17453674.2012.745657*

Printed in England  
by Latimer Trend & Company Limited  
2012

# Thesis at a glance

Question	Patients and methods	Measures	Results	Answer
1 Is stability-based ankle fracture classification useful in choosing between non-operative and operative treatment of ankle fractures, and how many ankle fractures can be treated non-operatively?	A retrospective study of 253 ankle fractures in skeletally mature patients, 160 of whom were included in the study to obtain an epidemiological profile in a population of 130,000.	Outcome was assessed using the scoring system of Olerud–Molander, the RAND 36-Item Health Survey, and the Visual Analog Scale (VAS) to measure pain and function after a minimum follow-up of 2 years.	Non-operatively treated patients had more displacement of the distal fibula after treatment, but less pain and better functional scores. No non-operatively treated patient had late displacement or needed operative fracture fixation during follow-up.	Stability-based fracture classification is a simple and useful tool in decision-making as regards the method of treatment and about half of the ankle fractures can be treated non-operatively with success.
2 Is exploration or repair of the AITFL beneficial?	A retrospective study of 288 patients with Lauge-Hansen SE4 ankle fractures; the AITFL was explored and repaired in one group (n=165), and a similar operative method was used but the AITFL was not explored in another group (n=123).	The clinical outcome was measured using the Olerud-Molander scoring system with a minimum follow-up of 2 years.	No significant difference was found between these two treatment protocols.	Exploration and repair of the AITFL is not needed in these fractures
3 Is the hook test or the clinical ER stress test sufficiently sensitive enough to detect syndesmosis injury? What is the interobserver agreement of these tests?	A prospective study of 140 patients with SE4 ankle fractures. The stability of the distal tibiofibular joint was evaluated by the hook and ER stress tests. Clinical tests were carried out by the main surgeon and assistant, separately, after which a 7.5-Nm standardized external rotation stress test for both ankles was carried out.	The sensitivity and specificity of both clinical tests were calculated using the standard 7.5-Nm external rotation stress test as reference. Kappa statistics and percentage agreement were calculated.	The hook test had a sensitivity of 0.25 and a specificity of 0.98. The external rotation stress test had a sensitivity of 0.58 and a specificity of 0.9. Both tests had excellent interobserver reliability; the agreement was 99% for the hook test and 98% for the stress test.	The interobserver agreement was excellent for both the hook test and the clinical stress test, but sensitivity of these tests was insufficient for detecting unstable syndesmosis injury in SE4 type ankle fractures when using a standardized 7.5-Nm external rotation stress test as a reference.
4 Does transfixation of the unstable syndesmosis influence the functional outcome?	A prospective randomized study of 140 patients with SE4 ankle fractures. The 7.5-Nm standardized ER stress test for both ankles was performed; if it was positive, the patient was randomized to either syndesmosis transfixation or no fixation treatment groups.	Outcome was assessed using the Olerud-Molander scoring system, RAND 36-Item Health Survey, and VAS to measure pain and function after a minimum of one year of follow-up.	There was no significant difference between these two groups.	Syndesmotic transfixation with a screw in this fracture pattern had no influence on the functional outcome or pain.



# Contents

LIST OF PUBLICATIONS, 2

ABBREVIATIONS, 2

ABSTRACT, 3

INTRODUCTION, 4

Anatomical and biomechanical considerations of ankle fractures, 4

Epidemiology of ankle fractures, 6

Mechanism of injury and classification, 6

Diagnosis, 7

Decision-making between non-operative or operative treatment, 8

AIMS OF THE STUDIES, 11

PATIENTS, 12

METHODS, 13

RESULTS, 16

DISCUSSION, 19

CONCLUSION, 22

REFERENCES, 23

## List of papers

1. Pakarinen H J, Flinkkilä T E, Ohtonen P P, Ristiniemi J Y. Stability criteria for nonoperative ankle fracture management. *Foot Ankle Int* 2011; 32(2): 141–7.
2. Pakarinen H J, Flinkkilä T E, Ohtonen P, P Ristiniemi JY. Anterior inferior tibiofibular ligament exploration and repair in Weber B-type ankle fracture: a comparative retrospective study. *Eur J Orthop Surg Traumatol* 2011; 21(8): 593–6.
3. Pakarinen H, Flinkkilä T, Ohtonen P, Hyvönen P, Lakovaara M, Leppilahti J, Ristiniemi J. Intraoperative assessment of the stability of the distal tibiofibular joint in supination-external rotation injuries of the ankle: sensitivity, specificity, and reliability of two clinical tests. *J Bone Joint Surg (Am)* 2011; 93(22): 2057–61.
4. Pakarinen H J, Flinkkilä T E, Ohtonen P P, Hyvönen P H, Lakovaara M T, Leppilahti J I, Ristiniemi J Y. Syndesmotic injury and fixation in supination-external rotation ankle fractures: a prospective randomized study. *Foot Ankle Int* 2011; 32(12): 1103–9.

---

## Abbreviations

<b>95% CI</b>	95% confidence interval
<b>AITFL</b>	anterior inferior tibiofibular ligament
<b>AP</b>	anteroposterior
<b>CT</b>	computed tomography
<b>ER</b>	external rotation
<b>MRI</b>	magnetic resonance imaging
<b>OM</b>	Olerud-Molander
<b>ORIF</b>	open reduction internal fixation
<b>SD</b>	standard deviation
<b>SER</b>	supination external rotation
<b>STTCS</b>	superior tibiotalar clear space
<b>TFCS</b>	tibiofibular clear space
<b>TFOL</b>	tibiofibular overlap
<b>TTCS</b>	tibiotalar clear space
<b>VAS</b>	visual analog scale

## Abstract

The aim of this thesis was to confirm the utility of stability-based ankle fracture classification in choosing between non-operative and operative treatment of ankle fractures, to determine how many ankle fractures are amenable to non-operative treatment, to assess the roles of the exploration and anatomical repair of the AITFL in the outcome of patients with SER ankle fractures, to establish the sensitivities, specificities and interobserver reliabilities of the hook and intraoperative stress tests for diagnosing syndesmosis instability in SER ankle fractures, and to determine whether transfixation of unstable syndesmosis is necessary in SER ankle fractures.

The utility of stability based fracture classification to choose between non-operative and operative treatment was assessed in a retrospective study (1) of 253 ankle fractures in skeletally mature patients, 160 of whom were included in the study to obtain an epidemiological profile in a population of 130,000. Outcome was assessed after a minimum follow-up of two years. The role of AITFL repairs was assessed in a retrospective study (2) of 288 patients with Lauge-Hansen SE4 ankle fractures; the AITFL was explored and repaired in one group (n=165), and a similar operative method was used but the AITFL was not explored in another group (n=123). Outcome was measured with a minimum follow-up of two years. Interobserver reliability of clinical syndesmosis tests (study 3) and the role of syndesmosis transfixation (study 4) were assessed in a prospective study of 140 patients with Lauge-Hansen SE4 ankle fractures. The stability of the distal tibiofibular joint was evaluated by the hook and ER stress tests. Clinical tests were carried out by the main surgeon and assistant, separately, after which a 7.5-Nm standardized ER stress test for both ankles was performed; if it was positive, the patient was randomized to either syndesmosis transfixation (13 patients) or no fixation (11 patients) treatment groups. The sensitivity and specificity of both clinical tests

were calculated using the standard 7.5-Nm external rotation stress test as reference. Outcome was assessed after a minimum of one year of follow-up. Olerud-Molander (OM) scoring system, RAND 36-Item Health Survey, and VAS to measure pain and function were used as outcome measures in all studies.

In study 1, 85 (53%) fractures were treated operatively using the stability based fracture classification. Non-operatively treated patients reported less pain and better OM (good or excellent 89% vs. 71%) and VAS functional scores compared to operatively treated patients although they experienced more displacement of the distal fibula (0 mm 30% vs. 69%; 0–2 mm 65% vs. 25%) after treatment. No non-operatively treated patients required operative fracture fixation during follow-up. In study 2, AITFL exploration and suture lead to equal functional outcome (OM mean, 77 vs. 73) to no exploration or fixation. In study 3, the hook test had a sensitivity of 0.25 and a specificity of 0.98. The external rotation stress test had a sensitivity of 0.58 and a specificity of 0.9. Both tests had excellent interobserver reliability; the agreement was 99% for the hook test and 98% for the stress test. There was no statistically significant difference in functional scores (OM mean, 79.6 vs. 83.6) or pain between syndesmosis transfixation and no fixation groups (Study 4)

Our results suggest that a simple stability-based fracture classification is useful in choosing between non-operative and operative treatment of ankle fractures; approximately half of the ankle fractures can be treated non-operatively with success. Our observations also suggest that relevant syndesmosis injuries are rare in ankle fractures due to an SER mechanism of injury. According to our research, syndesmotic repair or fixation in SER ankle fracture has no influence on functional outcome or pain after minimum one year compared with no fixation.

## Introduction

Rotational ankle fractures caused by indirect trauma and distal tibial fractures caused by direct axial loading are distinct entities both involving the same joint, but with substantially different treatments and prognoses. This thesis only addresses rotational ankle fractures, which are among the most common fractures treated by orthopedic surgeons. There is general consensus that the stability of the ankle mortise is the most important factor when choosing between operative and non-operative treatment (Yde and Kristensen 1980a, Yde and Kristensen 1980b, Bauer et al. 1985b, Kristensen and Hansen 1985, Phillips et al. 1985, Michelson 1995, Michelson 2007). Bi- and trimalleolar fractures are considered unstable injuries and should be treated operatively (Yde and Kristensen 1980b, Phillips et al. 1985, Ali et al. 1987, Michelson 1995, Michelson et al. 2007); however, in lateral malleolus fractures the ankle joint can be stable or unstable, depending on the mechanism of injury (Lauge-Hansen 1950, Yde and Kristensen 1980a, Yde and Kristensen 1980b, Michelson 1995, Michelson et al. 2007). There are currently no uniformly accepted criteria to estimate which lateral malleolus fractures can be considered stable and amenable to non-operative treatment.

Ideally, a classification system would help physicians determine the appropriate treatment method (Michelson et al. 2007), but neither of the two most widely used classification systems for ankle fractures, the Lauge-Hansen (Lauge-Hansen 1950) and Weber (Muller et al. 1979) systems, predicts fracture instability, and the values of these systems in choosing a treatment method are limited (Lindsjo 1985a, Bauer et al. 1987b, Nielsen et al. 1990, Broos and Bisschop 1991, Rasmussen et al. 1993, Michelson et al. 1997, Gardner et al. 2006c, Hara-guchi and Armiger 2009). Since the stability of the fractured ankle is the most important factor in choosing between operative and non-operative treatment, Michelson *et al.* proposed a stability-based ankle fracture classification system that more clearly addressed this aspect (Michelson et al. 2007). Operative treatment is indicated only for fractures in which the talus can move pathologically from the ankle mortise, which is the case in all bi- and trimalleolar fractures and lateral malleolar fractures with positive stress tests, and thus instability of the ankle mortise (Michelson et al. 2007) (Figure 1).

One factor affecting dynamic congruency (stability of the ankle mortise) is possible injury to the tibiofibular syndesmo-

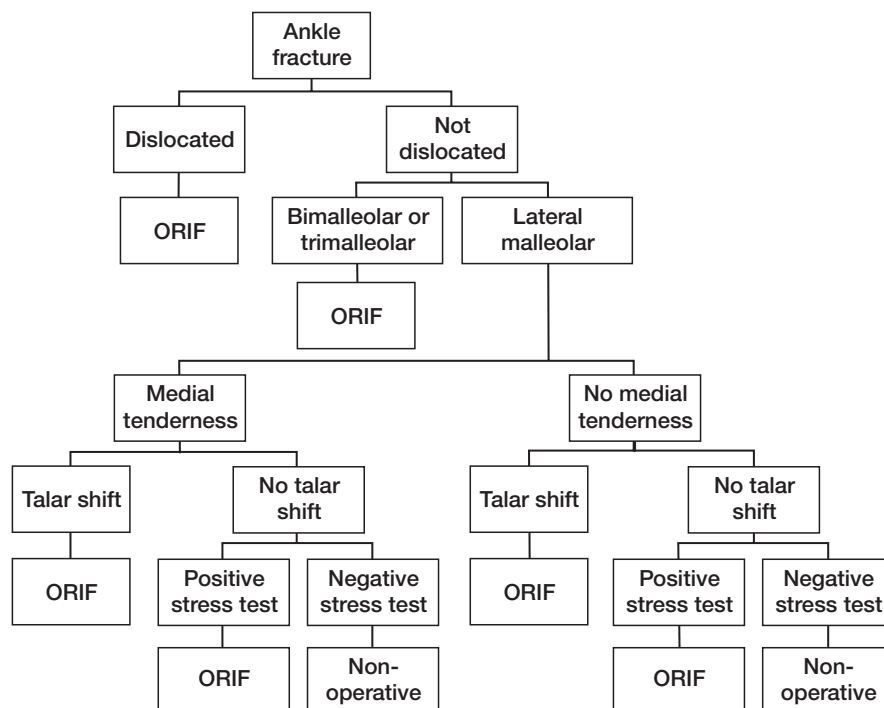


Figure 1. Decision tree for ankle fracture management (Michelson et al. 2007).

sis. Although syndesmosis injuries are apparent in ankle fractures that start above the tibial plafond (Lauge-Hansen 1950, Boden et al. 1989, Yamaguchi et al. 1994, Chissell and Jones 1995, van den Bekerom et al. 2010), there are unsuspected syndesmosis disruptions in lateral malleolus fractures that start at the level plafond (Leeds and Ehrlich 1984, Takao et al. 2001, Jenkinson et al. 2005, Weening and Bhandari 2005, Stark et al. 2007). Spiral lateral malleolus fractures starting at the level of the tibial plafond are the most common malleolar fractures; in this type of injury the AITFL is always ruptured (Lauge-Hansen 1950). There are, however, no clinical studies to confirm this observation.

Unstable syndesmosis may result in late instability, pain, and early osteoarthritis, especially in high fibular fractures, although little is known about its relevance in distal lateral malleolus fractures (Ramsey and Hamilton 1976, Leeds and Ehrlich 1984, Clarke et al. 1991, Chissell and Jones 1995, Tornetta 2000). Babis and Cedell recommended primary repair of AITFL ruptures in addition to syndesmosis fixation (Cedell 1965, Babis et al. 2000), but there are no clinical comparative studies of whether anatomical repair of the AITFL influences outcome.

There is no gold standard for diagnosing syndesmosis injury and instability. Preoperative plain radiographs rarely show syndesmosis injuries (Beumer et al. 2004, Nielson et al. 2004), and diagnoses must be made using intraoperative tests that demonstrate instability of the distal tibiofibular joint (Jenkinson et al. 2005, Stark et al. 2007). Many syndesmosis tests, like the hook and intraoperative stress tests are subject to numerous sources of error and the reliability of these tests is poorly understood. An intraoperative standardized 7.5-Nm ER stress test under fluoroscopy after internal fixation of fractured malleoli (Jenkinson et al. 2005) may have fewer sources of error and increase the detection rate of syndesmotic instability in SER-type ankle fractures. Additionally, this method may be more accurate than other tests (Jenkinson et al. 2005).

This thesis focuses on the usefulness of our stability-based classification of ankle fractures as well as the clinical relevance of syndesmosis injuries in ankle fractures due to an SER mechanism of injury.

### Anatomical and biomechanical considerations of ankle fractures

The ankle joint consists of the articulation of three bones: the distal aspect of the tibia, the distal aspect of the fibula, and the saddle-shaped talus. The articulations of this joint complex occur primarily between the dome of the talus and the tibial plafond. A medial facet of the talus articulates with the medial malleolus of the tibia, and a lateral facet articulates with the lateral malleolus (Michelson 1995). The lateral, medial, and syndesmotic ligaments support the ankle joint. Laterally, the distal aspect of the fibula is attached to the hind foot by three

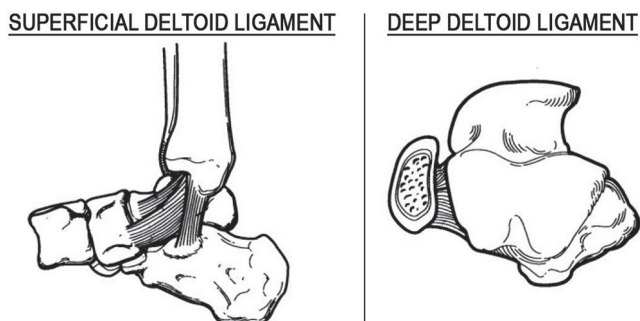


Figure 2. The two-component deltoid ligament.

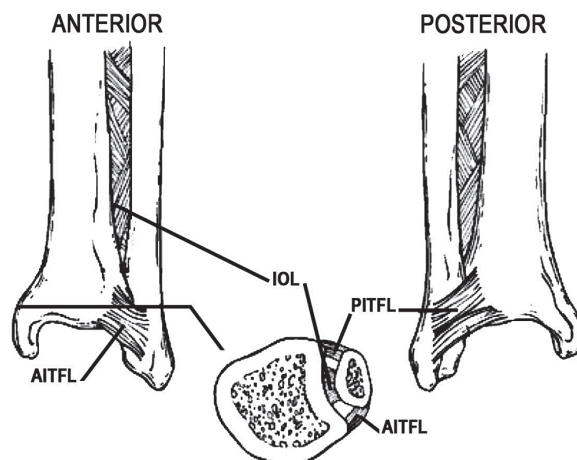


Figure 3. Distal tibiofibular syndesmosis.

ligaments: the anterior talofibular ligament, the calcaneofibular ligament, and the posterior talofibular ligament. The medial side of the ankle joint is stabilized by the two-component deltoid ligament (Figure 2). The distal tibiofibular connection, the distal tibiofibular syndesmosis, consists of the AITFL, the posterior inferior tibiofibular ligament, and the interosseous ligament, which is a distal part of the interosseus membrane (Beumer 2007) (Figure 3).

Normal plantar flexion and dorsiflexion are a combination of sliding and rolling (Sammarco et al. 1973). The dome of the talus is wider anteriorly than posteriorly, and as the ankle dorsiflexes the intramalleolar distance increases by approximately 1.5 mm as the fibula moves posterolaterally and rotates externally 2 degrees through the tibiofibular syndesmosis (Close 1956, Lundberg 1989). The syndesmosis binds the tibia to the fibula, while the deep deltoid ligament primarily prevents ER of the talus by pulling the talus to internal rotation when the ankle dorsiflexes (Rasmussen et al. 1983, Rasmussen 1985). Under normal physiological conditions, the ankle joint sustains peak loads of nearly four times the body weight (Procter and Paul 1982); during weight-bearing, 80–90% of the load is transmitted through the tibial plafond to the dome of the talus (Calhoun et al. 1994) and 17% is transmitted through the fibula (Lambert KL 1971).

If the injury pattern in a fractured ankle allows ER of the talus, the ankle mortise is unstable (Yablon et al. 1977, Harper 1983, Michelson 1995) and appears as a lateral shift of the talus on a two-dimensional plain radiograph. Sectioning of the AITFL does not itself cause instability of the talus (Rasmussen 1985), while sectioning of the deep deltoid ligament leads to talar instability when associated with lateral side injury (Harper 1983). Even 1 mm of talar displacement decreases the contact area in the tibiotalar joint by more than 40% (Ramsey and Hamilton 1976, Clarke et al. 1991). According to clinical and biomechanical studies, the medial malleolus and deltoid ligament are the primary sources of ankle stability (Pettrone et al. 1983, Phillips et al. 1985, Michelson et al. 1992, Harper 1995, Earll et al. 1996, Sasse et al. 1999, Michelson et al. 2002).

### Epidemiology of ankle fractures

The crude incidence of ankle fractures is reported to be 107–187 per 100,000 person-years (Bengner et al. 1986, Daly et al. 1987, Court-Brown et al. 1998, Jensen et al. 1998), and there is evidence that the epidemiology has changed since the 1950s (Bengner et al. 1986, Bauer et al. 1987, Kannus et al. 1996). The incidence was previously higher in men than in woman (Bengner et al. 1986, Daly et al. 1987, Court-Brown et al. 1998, van Staa et al. 2001), but in recent decades the age-specific incidence of ankle fractures in elderly women has more than doubled (Bengner et al. 1986, Kannus et al. 1996, Kannus et al. 2002). The most common age for ankle fracture is between 45 and 64 years (Buhr and Cooke 1959, Court-Brown et al. 1998). Young men between 15 and 24 years of age and females older than 40 years of age have the highest age-specific incidences (Bengner et al. 1986, Daly et al. 1987, Kannus et al. 1996, Court-Brown et al. 1998, Jensen et al. 1998).

Although the incidence of ankle fractures is well recorded, very little is known regarding the proportion of ankle fractures that require operative treatment. An epidemiological study reported that 45% of fractures were treated operatively (Jensen et al. 1998), but otherwise there are no published studies on this subject.

### Mechanism of injury and classification

Rotational ankle fractures are caused by indirect trauma. The deforming force is either internal or ER, abduction, or adduction (Lauge-Hansen 1950).

The basic goals of a classification system are to describe the fracture pattern accurately and to provide information for clinical choice of the appropriate treatment method. The Lauge-Hansen (Lauge-Hansen 1950) classification system was originally developed as a clinical tool to help obtain and maintain closed reduction of ankle fractures. The system has a two-part

nomenclature in which the first word presents the foot position at injury (supination or pronation) and the second word indicates the direction of the deforming force.

Supination of the foot achieves tension on the lateral ankle structures, while pronation achieves tension on the medial structures. Therefore, in a SER fracture, the injury begins anteriorly and progresses around the ankle, resulting in severity stages I to IV depending on the number of injured structures. The structures that are damaged are (in order) the AITFL, the lateral malleolus, the posterior aspect of the capsule or the posterior malleolus, and the medial malleolus or the deltoid ligament. SER stage-II fracture is a short oblique fracture of the distal fibula whereas SER stage-IV fracture has an associated medial side injury. Pronation-ER, supination-abduction, and pronation-abduction fractures are graded in the same way. Pronation-ER stage-I fracture is an isolated fracture of the medial malleolus and when the injury progresses around the ankle and it results the high fibular fracture at stage-III and finally posterior tibio-fibular ligament injury or fracture of the posterior malleolus at stage-IV. Supination-adduction stage-I is a lateral ligament injury or the transverse fibular fracture below the tibial plafond whereas stage-II fracture has an associated vertical fracture of the medial malleolus. Thus, pronation-abduction stage-I injury is a medial avulsion fracture and at stage-II the fibular bending forces causes often laterally comminuted transverse fibular fracture.

Lauge-Hansen originally proposed that an understanding of the mechanism of injury would facilitate the closed reduction, and reversing the mechanism of injury could result in optimum reduction (Lauge-Hansen 1950). However, later cadaver studies were unable to reproduce Lauge-Hansen's injury patterns completely (Michelson et al. 1997, Haraguchi and Armiger 2009). In addition, the many subgroups of the Lauge-Hansen system make it cumbersome to implement in clinical practice.

The Weber classification system (Muller et al. 1979), developed along with modern operative fracture stabilization techniques, is based on the concept that the lateral malleolus is the key to stability of the fractured ankle. The Weber classification divides ankle fractures into three types on the basis of the anatomy of the lateral malleolus fracture. Type A fractures are lateral malleolus fractures distal to the tibial plafond, type B fractures begin at the level of the tibial plafond, and type C fractures begin proximal to the level of the tibial plafond (Muller et al. 1979). This system is simple to use, but ignores medial side injury. Many studies consider associated medial malleolar fracture or deltoid ligament injury more important than the level of a fibular fracture (Pettrone et al. 1983, Phillips et al. 1985, Michelson et al. 1992, Harper 1995, Earll et al. 1996, Sasse et al. 1999, Michelson et al. 2002).

Neither the Lauge-Hansen nor the Weber system is reliable, since the interobserver reliability for both systems is only poor to fair (Nielsen et al. 1990, Thomsen et al. 1991, Rasmussen et al. 1993, Brage et al. 1998, Craig and Dirschl 1998). In addition, neither system is prognostic; fewer than 10% of studies

using the Weber classification and fewer than half of the studies using the Lauge-Hansen classification have suggested that these classifications can predict outcome (Cedell 1967, Eventov et al. 1978, Hughes et al. 1979, Beauchamp et al. 1983, Pettrone et al. 1983, Bauer et al. 1985a, Rowley et al. 1986, Ali et al. 1987, Bauer et al. 1987b, Ahl et al. 1989, Broos and Bisschop 1991, Makwana et al. 2001, Lash et al. 2002, Egol et al. 2004, Michelson et al. 2007).

Michelson et al. suggested a classification system (Figure 1) based on the stability of the fractured ankle (Michelson et al. 2007). They screened all English-language papers (1966 to December 2004) pertaining to the clinical treatment of ankle fractures in which outcome comparisons between treatments and/or fracture patterns could be made. The results supported the hypothesis that a stability-based ankle fracture classification system can be prognostic. For unstable ankle fractures, the radiographic outcomes were better after surgery when the decision for surgery was made on the basis of stability. The final reduction was shown to be a good predictor for clinical outcome (Tunturi et al. 1983, Phillips et al. 1985). Overall, non-operative treatment outcomes were also better with stability-based treatment (Michelson et al. 2007).

## Diagnosis

Although most patients with ankle sprains who present to emergency departments undergo radiography, fewer than 15% have a fracture (Brooks et al. 1981, Brand et al. 1982, Dunlop et al. 1986, Lloyd 1986, Sujitkumar et al. 1986). Meticulous clinical examination using the Ottawa ankle rules may reduce the number of unnecessary radiographs by 30–40% (Stiell et al. 1995, Bachmann et al. 2003). If clinical examination suggests a fracture, plain radiography is indicated, with three standard radiographic views of the injured ankle: AP, mortise (the true AP of the ankle; (Goergen et al. 1977), and lateral. There is some debate regarding the number of radiographic views that are necessary (Cockshott et al. 1983, Vangsness et al. 1994, Brage et al. 1998, Brandser et al. 2000); Winkler et al. suggested that if only mortise and lateral views are used, up to 98% of the accuracy of the use of all three standard radiographs can be achieved (Winkler et al. 1990).

Since plain radiographs do not reveal dynamic incongruity, ER stress or weight-bearing radiographs have been used in an attempt to demonstrate instability associated with lateral malleolar fracture and deltoid ligament injury (Pankovich 1979, Pankovich and Shivaram 1979, Michelson et al. 2001, Weber et al. 2010). Gravity stress radiographs are considered to be as useful as the manual stress radiograph for determining complete deltoid ligament injury in association with an isolated distal fibular fracture (Gill et al. 2007). However, it is unclear whether a positive radiograph alone is a sufficient criterion for surgical intervention (Egol et al. 2004). Clinical signs that suggest an unstable fracture pattern include lateral

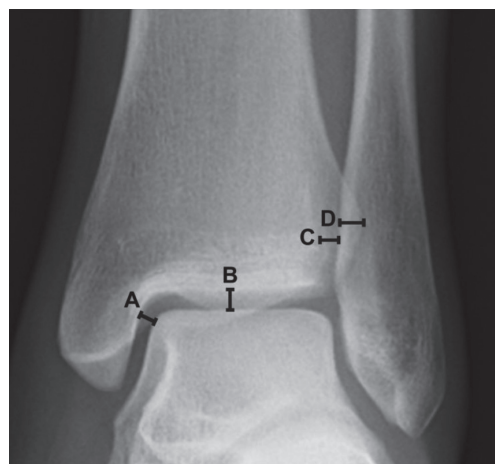

Figure 4. Radiographic parameters. A = TTCS, B = STTCS, C = TFCS, and D = TFOL.

side fracture with medial tenderness, swelling, and ecchymosis; however, these clinical signs did not predict widening of the medial clear space on stress radiographs (Egol et al. 2004). Michelson et al. suggested that patients with isolated lateral malleolus fractures should always undergo a stress test (Michelson et al. 2007).

Plain radiographs can sometimes reveal syndesmosis injury if the ankle is in subluxation or luxation and the diastase of the injured syndesmosis or displacement of the talus can be seen (Edwards and DeLee 1984). ER stress radiographs may also help if the diastasis of the injured syndesmosis is not visible on plain radiographs (Beumer 2007). Syndesmosis integrity is assessed by measuring the TFCS and TFOL on AP view. TFCS, the distance between the posterolateral or anterolateral border or the incisura of the tibia and the medial border of the fibula (Pettrone et al. 1983, Leeds and Ehrlich 1984, Sclafani 1985, Harper and Keller 1989), is measured at the level of the epiphyseal scar approximately 1 cm proximal to the tibial plafond (Leeds and Ehrlich 1984, Wuest 1997, Elgafy et al. 2010) (Figure 4). The TFCS should be less than 6 mm as measured between the posterolateral border of the tibial incisura and the medial border of the fibula on AP and mortise views (Harper and Keller 1989). The TFOL is the horizontal distance between the medial border of the fibula and the lateral border on the anterior tibial tubercle (Pettrone et al. 1983); it is considered normal if it is longer than 6 mm on the AP and longer than 1 mm on the mortise view (Harper and Keller 1989) (Figure 4). Medial TTCS and STTCS are also used to assess syndesmosis injury because accompanying delta ligament injury may lead to lateral shift of the talus (Beumer 2007). The TTCS is measured as the distance between the lateral border of the medial malleolus and the medial border of the talus at the level of the talar dome (Joy et al. 1974, Jenkinson et al. 2005) (Figure 4). The TTCS should not exceed the STTCS (Figure 4) on the AP view or 4 mm on

the mortise view (Pettrone et al. 1983), but no real validation of these parameters exist.

A CT scan provides more detail about bony fracture anatomy, and is needed especially with plafond injuries (Magid et al. 1990). CT has been used to study the displacement of the fracture site and congruence of the tibiotalar joint (Michelson et al. 1992), or to describe the normal anatomy of distal tibiofibular joint (Ebraheim et al. 1997, Elgafy et al. 2010). There are no clinical studies using CT to evaluate the stability of the fractured ankle. MRI provides additional information about concomitant soft tissue, especially delta ligament and syndesmotic injuries (Vogl et al. 1997, Nielson et al. 2004, Gardner et al. 2006c, Beumer 2007, Koval et al. 2007, Cheung et al. 2009), but it does not aid assessment of syndesmosis stability. Ultrasound, when compared to MRI, has been reported to have a sensitivity of 0.66 and a specificity of 0.91 (Milz et al. 1998); however, the validity of ultrasound imaging is dependent on the experience of the examiner, and ultrasound is not performed routinely for diagnosis of syndesmosis injuries (Beumer 2007). Arthroscopy is also useful for diagnosing syndesmosis injuries (Ogilvie-Harris and Reed 1994, Takao et al. 2003), but it is invasive and there is no quantitative data on how much displacement may be considered to be still within normal limit (Beumer 2007).

Usually, diagnosis of syndesmosis injury must be made via clinical tests that attempt to demonstrate distal tibiofibular joint instability. In the squeeze test, the fibula is compressed toward the tibia at the midpoint of the calf; the test is considered positive when the compression produces pain distally at the area of syndesmosis (Hopkinson et al. 1990, Teitz and Harrington 1998). The ER stress test is performed by applying ER stress to the ankle. A positive finding is pain at the area of syndesmosis or widening of the TFCS or TTCS assessed (intraoperatively) with fluoroscopy after internal fixation of fractured malleoli (Boytim et al. 1991, Ogilvie-Harris and Reed 1994, Jenkinson et al. 2005). The Cotton test (Cotton FJ 1910) and its modification the hook test create lateral translation of the fibula. The Cotton test was originally used to diagnose Pott's fracture, and it is actually a lateral translation test of the foot (Cotton FJ 1910). The fibular translation or rotation tests are considered positive when sagittal translation or rotation of the fibula with respect to the tibia can be achieved (Ogilvie-Harris and Reed 1994, Candal-Couto et al. 2004) (Figure 5).

Although these tests are widely used in clinical practice, no studies of their interobserver reliabilities have been published. Jenkinson et al. (2005) modified the ER test and used a special tool, the F-fork, to generate a standardized ER force. Xenos and Beumer (Xenos et al. 1995, Beumer et al. 2003) separately studied the ER stress test in cadavers and noted that a 7.5-Nm force is sufficient to demonstrate instability of the distal tibiofibular joint. This 7.5-Nm torque has also been applied in clinical studies (Xenos et al. 1995, Jenkinson et al. 2005, Stoffel et al. 2009). The standardized 7.5-Nm ER stress test has fewer sources of error than other intraoperative syndesmosis tests, although its reproducibility has not been studied.

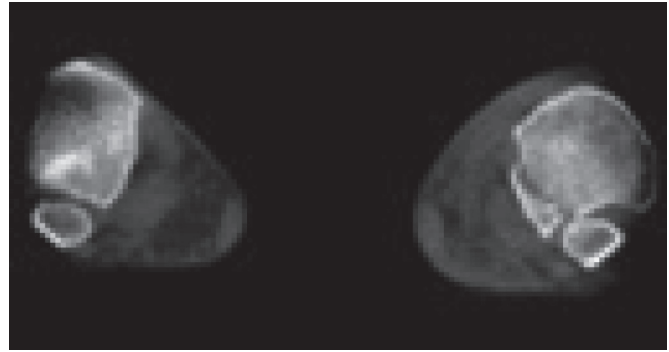


Figure 5. Sagittal translation of the fibula (on the right side) at gravity ER stress in intraoperative CT scan.

### Decision-making between non-operative or operative treatment

The stability of the fractured ankle is the critical determinant in clinical decision-making. Fractures associated with unstable ankle mortise may lead to late instability, pain, and osteoarthritis, and in general operative treatment is indicated (Yde and Kristensen 1980b, Purvis 1982, Phillips et al. 1985, Ali et al. 1987, Michelson 1995, Michelson et al. 2007). Fractures with stable ankle mortise can be treated non-operatively (Yde and Kristensen, 1980a, Yde and Kristensen 1980b, Bauer et al. 1985b, Kristensen and Hansen 1985, Phillips et al. 1985, Michelson 1995). Good long-term functional results support this decision-making paradigm; after more than twenty years of follow-up, the closed treatment of stable SER stage-II fractures was associated with good clinical results in more than 94% of cases (Bauer et al. 1985b, Kristensen and Hansen 1985).

Most studies agree that bi- and trimalleolar fractures are unstable injuries that should be treated operatively (Yde and Kristensen 1980b, Phillips et al. 1985, Ali et al. 1987, Michelson 1995, Michelson et al. 2007). The treatment of displaced unimalleolar distal fibular fracture, however, is controversial. Researchers favoring the Weber classification consider displacement of the lateral malleolus to be the most important factor in choosing between operative and non-operative treatment. The acceptable amount of displacement of the distal fibula has varied between 0 and 5 mm (Bauer et al. 1985a, Lehto and Tunturi 1990, Muller et al. 1991, Michelson 1995, Wiss 2006); tibiotalar contact stress does not increase substantially unless the displacement of the lateral malleolar fracture is more than 5 mm (Brown et al. 1994). A CT study revealed that in an isolated lateral malleolar ankle fracture, the ER of the fracture fragment is relative only to the proximal fibula and is not associated with derangement of the talofibular articulation (Michelson et al. 1992). Michelson and colleagues have suggested that displacement alone is of minor importance, and ankle stability is the key factor in choosing the appropriate treatment (Fig. 1; (Michelson et al. 1992, Michelson 1995, Michelson et al. 2007).

Non-operative treatment of ankle fracture requires stability to restore alignment and to allow bony healing. Stability of the fracture is considered an important factor for healing. Especially if, associated soft tissue injury is extensive, when the blood supply is marginal and when the fracture comes into contact with synovial fluid (Buckwalter et al. 2001). Nonunion of ankle fractures is uncommon, but non-operative treatment of unstable fracture may lead to malunion and posttraumatic osteoarthritis (Marsh and Saltzman 2001).

SER injuries (Weber B) are considered to be the most common cause of all indirect fibular fractures, while syndesmosis injuries are apparent in Weber C-type ankle fractures (Lauge-Hansen 1950, Boden et al. 1989, Yamaguchi et al. 1994, Chissell and Jones 1995, van den Bekerom et al. 2010). However, syndesmosis may be intact or ruptured in SER ankle fractures (Leeds and Ehrlich 1984, Takao et al. 2001, Jenkinson et al. 2005, Weening and Bhandari 2005, Stark et al. 2007). According to Lauge-Hansen, the most typical fracture pattern is a spiral lateral malleolus fracture starting at the level of the tibial plafond; the fracture starts anteriorly, and the AITFL is always ruptured (Lauge-Hansen 1950). It is controversial whether AITFL rupture alone renders distal tibiofibular syndesmosis unstable. Boden et al. suggested that syndesmosis is unstable only when the fibular fracture is 3–4.5 cm proximal to the ankle joint and the deltoid ligament is torn (Boden et al. 1989). The intraoperative ER stress of an isolated AITFL (Lauge-Hansen stage 1) injury has a tibiofibular diastase of 10–12 mm (Cedell 1967). If syndesmosis is considered unstable, most authors recommend its repair to prevent late instability, pain, and early osteoarthritis (Ramsey and Hamilton 1976, Leeds and Ehrlich 1984, Clarke et al. 1991, Chissell and Jones 1995, Tornetta 2000). The clinical relevance of syndesmosis injury and the effect of repair on outcome are especially poorly known in ankle fractures due to the SER mechanism of injury.

### **Non-operative treatment**

Stable fractures can be treated with a short cast or functional brace. Weight bearing can be allowed as tolerated, and patients usually start to weight-bear when symptoms ease. The long-leg cast is not necessary, and good results have been reported with high-top shoes and with use of an elastic bandage (Zeegers et al. 1989, Ryd and Bengtsson 1992).

### **Operative treatment**

Rigid fixation of the lateral and medial malleolus with a small fragment plate and screws is the most common operative method for unstable fractures. The lateral malleolus is usually fixed with one-third plate with two or three 3.5 mm cortical screws on either side of the fracture site with or without an additional compression with lag screw (Hahn and Colton 2007). Kirchner wires are mainly used for temporary fixation to hold reduction, but Koval *et al.* recommend augmentation with a plate fixation with intramedullary Kirchner wire when

the bone is osteopenic (Koval et al. 1997). The plate is usually placed at the lateral side of the fibula, but one-third of patients have lateral pain or irritation after placement of lateral hardware; a posterior plate may reduce hardware problems (Brown et al. 2001). The lag screw technique may also decrease the hardware prominence, but lag screw fixation is only recommended for patients under 50 years old with a simple uncomminuted fracture (Kim and Oh 1999, Tornetta and Creevy 2001). A posterior plate can improve the mechanics of fixation for very distal fibular fracture or for osteopenic bone (Schaffer and Manoli 1987), and some researchers routinely prefer a posterior plate for SER ankle fractures (Winkler et al. 1990, Ostrum 1996). A posterior plate may rarely cause peroneal tendinitis (Treadwell and Fallat 1993).

If the medial malleolar fracture requires fixation it is usually reduced and fixed with two 3.5-mm or 4.0-mm partially threaded cancellous screws. If the medial fragment is small, or if there are comminuted osteoporotic fragments, some researchers prefer tension band fixation (Hughes, 1980, Ostrum and Litsky 1992, Georgiadis and White 1995, Skie et al. 1995). Posterior malleolar fractures of more than 30% of the articular surface can lead to instability of the ankle in the posterior direction, and thus fixation is recommended (Jaskulka et al. 1989, Raasch et al. 1992, Scheidt et al. 1992). Fixation of the posterior malleolus may also stabilize the syndesmosis when injured, especially with high fibular fractures (Gardner et al. 2006a). When the fibula is reduced, the posterior malleolus usually reduces spontaneously. The fragments are fixed with 3.5-mm or 4.0-mm partially threaded cancellous screws from front to back or vice versa.

### **Syndesmosis injury**

Syndesmosis repair techniques are usually based on temporarily transfixing the distal fibula to the tibia to allow soft tissue healing. Technical aspects of syndesmosis screw fixation vary among surgeons (Weening and Bhandari 2005, Monga et al. 2008, Bava et al. 2010), and there is no consensus regarding the number of cortices, screw size, or foot position during screw insertion. A larger screw is stronger and easier to remove due to its large head, but there is no biomechanical advantage of a 4.5-mm screw over a 3.5-mm screw (Thompson and Gesink 2000, Beumer et al. 2005). A biomechanical study demonstrated that two syndesmosis screws could make a stronger construct than a single screw (Xenos et al. 1995), three cortical syndesmosis screws allow some fibular movement and may not break or loosen compared to four screw cortices (Marsh and Saltzman 2001, Beumer et al. 2005), but three or four cortices of fixation can be used to stabilize syndesmosis injuries (Moore et al. 2006, Wikeroy et al. 2010). Previously, stability comparable to a tricortical 3.5-mm screw was achieved with two Kirchner wires (Peter et al. 1994), and it has been suggested that bioabsorbable syndesmosis screws are well tolerated and avoid the need for subsequent screw removal (Thordarson et al. 2001, Hovis et al. 2002).

Olerud found a one-degree limitation of ankle dorsiflexion for every degree of ankle plantar flexion during syndesmotom screw insertion (Olerud 1985). In contrast, however, a cadaver study revealed that compression of the syndesmosis in plantarflexion led to no difference in maximal dorsiflexion before and after syndesmotom compression (Tornetta et al. 2001). The optimal level of syndesmotom transfixation required to resist ER forces is 2–5 cm (McBryde et al. 1997, Miller et al. 1999), and the screw should be parallel to the joint to avoid displacement of the fibula in an inferior or superior direction (Amendola 1992). Endobutton-type suture transfixation could be as effective as traditional syndesmotom screw fixation (Cottom et al. 2009, Soin et al. 2009). However, a clear majority (97.4%) of trauma surgeons favor the use of a syndesmotom screw for fixation, and more than half of them employ a small fragment screw across three cortices (Monga et al. 2008). Some researchers (Cedell 1965, Babis et al. 2000, Kabukcuoglu et al. 2000, Nelson 2006) have rec-

ommended primary suture repair of AITFL ruptures in addition to syndesmosis fixation. AITFL repair was common in the early 1990s but was later abandoned, and there are no clinical comparative studies of whether anatomical AITFL repair influences outcome.

#### ***Postoperative treatment***

A variety of postoperative protocols have been proposed to date, from active motion protected with a brace to non-weight bearing in a plaster cast (Ahl et al. 1988, Finsen et al. 1989, Cimino et al. 1991, Ahl et al. 1993, Hedstrom et al. 1994, van Laarhoven et al. 1996), but comparative studies identified no differences in short- or long-term results. Most surgeons allow no (73%) or at most partial (16%) weight-bearing after syndesmotom transfixation (Monga et al. 2008), likely to avoid screw breakage (Beumer et al. 2005). There are no comparative studies of syndesmosis widening in different postoperative treatment protocols.

## Aims of the studies

1. To confirm the utility of our stability-based criteria in choosing between non-operative and operative treatment of ankle fractures, and to determine how many ankle fractures were amenable to non-operative treatment.
2. To assess the roles of the exploration and anatomical repair of the AITFL in the outcome of patients with SER ankle fractures.
3. To establish the sensitivities, specificities, and interobserver reliabilities of the hook and intraoperative stress tests for diagnosing syndesmosis instability in SER ankle fractures.
4. To determine whether transfixation of unstable syndesmosis is necessary in SER ankle fractures.

## Patients

*Study 1:* A retrospective study of 253 ankle fractures in skeletally mature patients ( $\geq 15$  years of age) treated at Oulu University Hospital in 2003. One hundred and sixty patients (86 women, 74 men) who lived in Oulu at the time of injury were included in the study to obtain an epidemiological profile of a population of approximately 130,000 people.

*Study 2:* A comparative retrospective study of 288 patients with Lauge-Hansen SE4 ankle fractures. From 1993–1994 (Group 1) and in 2003 (Group 2), 471 ankle fractures in skeletally mature patients were treated operatively at Oulu University Hospital; of these patients, 288 with Lauge-Hansen SE4 ankle fractures were eligible for this study. In Group 1 ( $n=165$ ), the AITFL was explored and the ruptured ligament sutured or the avulsion fracture fixed at the original insertion. If the AITFL was intact, it was just explored. In Group 2 ( $n=123$ ), a similar operative method was used, but the AITFL was not explored.

*Studies 3 and 4:* Prospective randomized studies of patients with Lauge-Hansen SE4 ankle fractures. Eligible patients were skeletally mature ( $\geq 16$  years old) with unilateral SE4 ankle fractures treated within one week after injury in Oulu University Hospital between July 19, 2007 and June 10, 2009. Exclusion criteria were bilateral ankle fractures, pathologic fractures, concomitant tibial shaft fractures, previous significant injury, fracture of either ankle, significant peripheral neuropathy, soft tissue infection in the region on either injured ankle, or inability to complete the study protocol. One hundred sixty-six patients were screened, and 26 were excluded (18 via the exclusion criteria, eight due to operation room congestion), leaving 140 patients (71 females, 69 males; mean age 47 years, SD 16.0 years, range 16–84 years) with SE4 type ankle fractures.

# Methods

## Classifications, measurements, and assessment of clinical outcome

Fractures were classified according to the Weber and Lauge-Hansen systems. TTCS, TFCS, and congruence of the tibiotalar joint were measured and analyzed postoperatively and at follow-up (Study 2, TTCS and congruence on tibiotalar joint). Clinical outcome was assessed with the OM system (Olerud and Molander 1984), the RAND 36-Item Health Survey (Aalto et al. 1999, Hays and Morales 2001), and the 100-mm VAS (Study 2, only OM) to measure pain and function after a minimum of one year (Study 4) or two years (Studies 1 and 2). Questionnaires were mailed, and those patients who did not return them were contacted by telephone. The same forms were completed during the telephone interview.

## Power analysis (Study 4)

Functional result assessed by Olerud-Molander score (Olerud and Molander 1984) was considered the most important outcome parameter. The sample size calculations showed that 30 patients per group would be enough to detect a clinically significant difference of 20% in Olerud-Molander ankle score between the study-groups [standard deviation (SD) 24 points, from study 1,  $\alpha=0.05$ ,  $\beta=0.2$  and estimated of 20% drop out]. Syndesmosis injury rate in SER ankle fractures is reported to be up to more than 30% (Nielsen et al. 2004, Jenkinson et al. 2005, Stark et al. 2007). Thus, it was estimated that two hundred patients with SE fractures would be needed to carry out the study, and it was estimated to take about two years to recruit enough patients to the trial.

## Non-operative treatment (Study 1)

The decision between operative and non-operative treatment was made by the surgeon-on-duty, based on the modified stability criteria of Michelson et al. (Figure 6). Stable fractures were treated non-operatively using a standardized protocol. Fracture patterns that were considered stable were: isolated lateral malleolar fractures (Weber A/B) without talar shift on initial radiographs, medial tenderness, or medial effusion; isolated lateral malleolar fractures with medial tenderness or hematoma, and but without talar shift on mortise radiograph and with negative stress test; isolated undisplaced medial malleolar fractures. The ankles were immobilized in a below-the-knee cast

for five weeks, with weight bearing allowed as tolerated. The patients had follow-up visits at the outpatient clinic two and five weeks after the injury, during which mortise and lateral plain radiographs were taken. At the two-week visit the wound was checked and the cast was changed. A radiograph was taken with the cast. During the five-week visit, the cast was removed and the physiotherapist provided the patient with instructions for rehabilitation.

## Operative treatment

Fracture patterns that were considered unstable were: bimalleolar fractures; trimalleolar fractures; high fibular fractures starting from above the ankle joint with medial side injury and positive stress test; lateral malleolar fracture with medial tenderness or hematoma and positive stress test; lateral malleolus fractures with any talar shift or tilt on ankle mortise or lateral radiographs; displaced medial malleolus fractures (Figure 6).

Malleolar fixation was performed using standard AO principles (Muller et al. 1991, Hahn and Colton 2007). The lateral malleolus was reduced and rigidly fixed with two 3.5-mm lag screws, with a 1/3 tubular plate, or with a lag screw and plate.

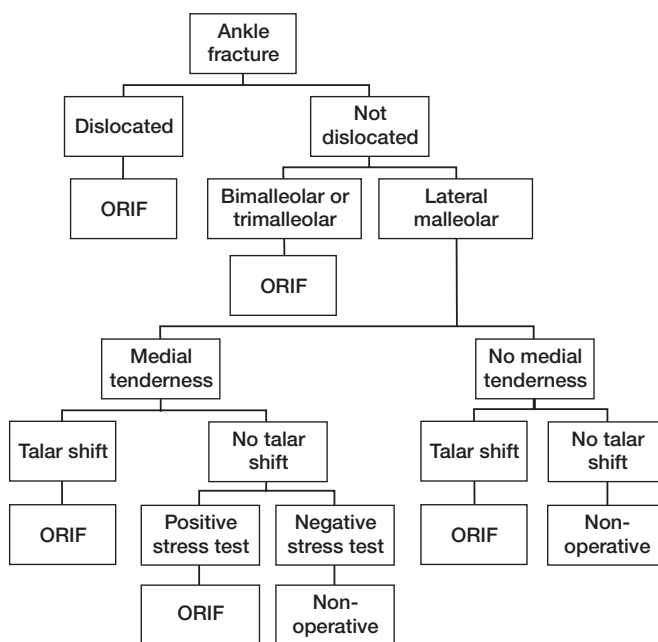


Figure 6. Decision tree for ankle fracture management (Pakarinen et al.).

Medial malleolar fractures were reduced and fixed with two 3.5-mm partially threaded cancellous screws. Posterior malleolar fractures were fixed with 3.5-mm partially threaded cancellous screws from anterior to posterior if the fragment involved over 30% of the articular surface as estimated via lateral radiograph.

### Diagnosis and treatment of syndesmosis injury

*Study 1:* Syndesmosis transfixation was performed if the intraoperative ER stress test under fluoroscopy was positive after malleolar fixation.

*Study 2:* In Group 1, the AITFL was explored and the ruptured ligament sutured using non-absorbable 2-0 (Ethibond<sup>®</sup>, Johnson & Johnson, New Brunswick, NJ, USA) sutures. If the ligament was avulsed, it was fixed in the original insertion using 3.5-mm screws and a washer; the AITFL was explored only if intact. In Group 2, a similar operative method was used, but the AITFL was not explored. Syndesmosis transfixation was carried out if the ER stress test under fluoroscopy was positive after malleolar fixation.

*Study 3:* After malleolar fixation the stability of the distal tibiofibular joint was examined by clinical syndesmosis tests; one surgeon left the operating theater and the other surgeon performed the hook test and the ER stress test under fluoroscopy. The roles were then reversed, and the second surgeon carried out the same tests. In the hook test, the tibia was stabilized with one hand and the lateral malleolus grabbed with a bone hook, followed by application of lateral force. The hook test was considered positive if there was more than 2 mm of lateral fibula movement under direct vision. In the ER stress test, the tibia was stabilized with one hand and ER force was applied to the foot, followed by assessment of the TTCS using fluoroscopy. The images were printed and the surgeon measured the radiographic parameters with 1-mm accuracy using a caliper. The ER stress test was considered positive if the medial TTCS was 5 mm or more under stress. After the clinical test, the 7.5-Nm ER test was performed as a reference. The treatment of syndesmosis injuries is described below (Study 4).

*Study 4:* After bony fixation, the 7.5-Nm standardized ER stress test for both ankles was carried out under fluoroscopy (Figures 7–9) with an F-tool-like fork as described (Jenkinson et al. 2005), with the torque value verified in cadaver studies (Xenos et al. 1995, Wuest 1997). The F-tool was applied to the medial aspect of the forefoot and the lateral aspect of the hind foot, and the proximal tibia was stabilized with one hand by the other physician. The angle was held at 90 degrees between the tibial shaft and foot. A standardized ER 7.5-Nm force was applied to the level of the ankle mortise. The operating surgeon evaluated the TTCS and TFCS in both limbs intraoperatively using fluoroscopy (Figures 8 and 9). TFCS was measured at the level of the epiphyseal scar approximately 1 cm proximal

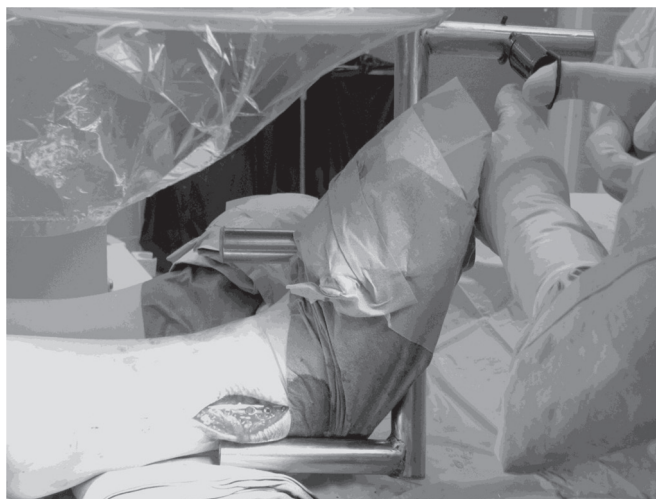

Figure 7. Intraoperative 7.5-Nm ER stress test.

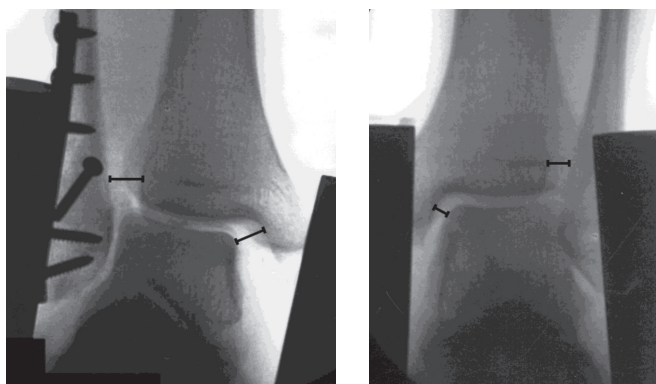


Figure 8. 7.5-Nm ER stress test of an injured ankle.

Figure 9. 7.5-Nm ER stress test of a contralateral ankle.

to the tibial plafond (Jenkinson et al. 2005, Elgafy et al. 2010), and the TTCS was measured as the distance between the lateral border of the medial malleolus and the medial border of the talus at the level of the talar dome (Joy et al. 1974, Jenkinson et al. 2005). A positive stress examination was defined as a difference of more than 2 mm side-to-side in the TTCS or TFCS on mortise radiographs (Figures 8 and 9). The fluoroscopic measurements were normalized for magnification using the dimensions of the small fragment fixation (head of a 3.5-mm screw, Synthes GmbH, Oberdorf, Switzerland) and the arm of the F-tool as references.

If the stress test was positive, the patient was randomized to syndesmotic transfixation with 3.5-mm tricortical screw (Thompson and Gesink 2000, Nousiainen et al. 2008, Wikeroj et al. 2010) or to no syndesmotic fixation. The syndesmotic screw was placed with the ankle held at a 90-degree angle between the tibial shaft and the foot. The fibula was held at its anatomical position by hand or by reduction clamp with no extra compression.

## Postoperative treatment

The ankles were immobilized in a below-the-knee cast for four weeks (Studies 3 and 4) or six weeks (Studies 1 and 2). Weight bearing was allowed as tolerated. The patients had a follow-up visit at the outpatient clinic two, and four (Studies 3 and 4), six (Studies 1 and 2), or 12 weeks (Studies 3 and 4) after the injury. At the two-week visit, the wound was checked, sutures were removed, and the cast was changed. At the four- (Studies 3 and 4) or six-week (Studies 1 and 2) visits, the cast was removed, the ankle was examined, mortise and lateral plain radiographs were taken without the cast, and the physiotherapist provided rehabilitation instructions for the patient. During the 12-week visit (Studies 3 and 4), the ankle was examined, and mortise and lateral plain radiographs were taken. Research physiotherapists measured the range of motion of the injured ankles and provided rehabilitation instructions.

## Statistical methods

Summary measurements are expressed as mean and SD unless otherwise stated. Continuous variables were analyzed by Student's *t*-test or the Mann-Whitney *U*-test in simple between-group comparisons. Categorical variables were compared using Pearson's  $\chi^2$  test or Fisher's exact test. Differences between means with 95% CIs were calculated. In Study 1, a linear regression model was created using the OM score as a dependent variable. In the final model the continuous variable age was centered at 40 years (age minus 40), which allowed interpretation of the constant term as an overall mean. Statistically significant variables were used in the final linear

regression model. Linearity and constancy of variances were evaluated graphically by means of residual versus predictor plots. Residual variances were evaluated to ensure non-violation of the homoscedasticity assumption for class variables. Two-tailed *p*-values are presented, with *p* < 0.05 considered statistically significant.

In Study 3, kappa statistics and percentage agreement (the percentage of assessors who agreed with one another) were used as statistical methods. Although percentage agreement involves the possibility that some agreement will occur purely by chance, it provides an overview of agreement between two assessors. Interpretation of kappa values was carried out according to the guidelines proposed by Fleiss (Fleiss 1981) and by Landis and Koch (Landis and Koch 1977). According to Fleiss (Fleiss 1981), kappa values less than 0.40 indicate poor reliability, 0.40 to 0.75 fair to good reliability, and 0.76 to 1.0 excellent reliability. According to Landis and Koch (Landis and Koch 1977), kappa values of 0.00 to 0.20 represent slight agreement, 0.21 to 0.40 fair agreement, 0.41 to 0.60 moderate agreement, and 0.61 to 0.80 substantial agreement. Kappa values above 0.80 are considered to indicate nearly perfect agreement.

In Study 4, randomization was performed using a computer-generated randomization list that was created by one of the authors (Pasi Ohtonen) independent of the actual treatment process. Randomization was carried out with randomly changing block sizes of four and six. Numbered, sealed envelopes were created by a research secretary to allocate each patient to the fixation or control group according to the list.

All analyses were performed using the statistical program SPSS version 16.0 (SPSS Inc., Chicago, IL, USA).

## Results

### Study 1

The crude incidence of ankle fractures was 154/100,000, with more women (54%) who were significantly older ( $p < 0.05$ ,  $t$ -test) than the men. Young men (under the age of 24 years) had more than twice as many fractures as women of the same age. The highest age-related incidence in women as well as the highest total incidence occurred between the ages of 45 to 64 years. The overall incidence decreased after 65 years of age, although age-related incidence started to increase in women after 75 years of age (Figure 10). By Lauge-Hansen classification the most common fracture type was SE4 (43%), and by the Weber classification the B-type fracture occurred most commonly (75%). Anatomically the most common fracture type was isolated fibular fracture (59%; Table 1).

Eighty-five (53%) fractures were treated operatively. Sixty-six (75%) isolated Weber type A or B lateral malleolar fractures were treated non-operatively, and 51 (94%) of the bimalleolar

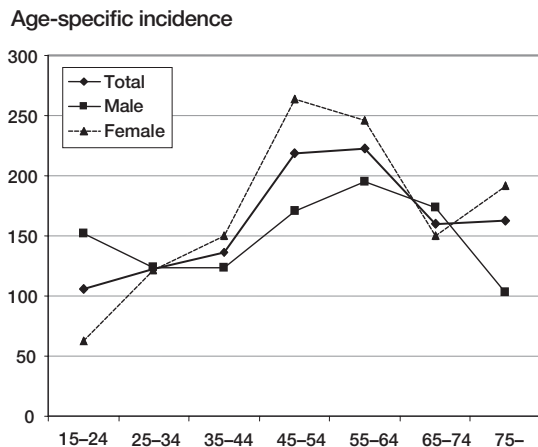


Figure 10. Incidence rate per 100,000 people stratified by age group (Study 1).

and trimalleolar fractures were treated operatively. Six out of ten isolated medial malleolar fractures were treated operatively (Table 1). Non-operatively treated patients reported less pain and better OM (good or excellent 89% vs. 71%) and VAS functional scores (Table 2). Weber classification was not prognostic regarding physical function or pain. Non-operatively treated patients experienced more displacement of the distal fibula after treatment (0 mm 30% vs. 69%; 0–2 mm 65% vs. 25%,  $p < 0.001$ ). Independent factors associated with worse

Table 1. Fracture classification and treatment (Study 1)

Classification		Treatment		All
		Conservative	Operative	
n (%)		75 (47)	85 (53)	160
AO	A	17	0	17
	B	52	68	120
	C	2	10	12
	unclassified	4	7	11
Lauge-Hansen	PA1	2	3	5
	PA2	0	1	1
	PA3	0	3	3
	PE1	1	0	1
	PE3	0	5	5
	PE4	0	6	6
	SA1	17	0	17
	SA2	2	1	3
	SE2	47	0	47
	SE3	1	0	1
Anatomy	SE4	3	65	68
	unclassified	2	1	3
	fibula	68	27	95
	fibula + med. mall.	1	19	20
	fibula + post. mall.	1	13	14
	trimalleolar	1	19	20
	med. mall.	4	6	10
	post. mall.	0	1	1

med. mall. = medial malleolus,  
post. mall. = posterior malleolus

Table 2. Treatment and self-reported disability (Study 1)

	Conservative mean (SD)	Operative mean (SD)	Mean difference	95% CI for the difference	p-value
OM score	87.8 (20.5)	75.1 (26.4)	12.7	4.6 to 20.9	0.001
VAS pain	11.0 (18.4)	24.0 (29.2)	-13.0	-21.5 to -4.5	0.019
VAS function	11.6 (17.2)	23.1 (30.0)	-11.4	-20.0 to -2.9	0.023
RAND-36 physical function	80.9 (25.4)	74.2 (28.3)	6.7	-4.0 to 17.5	0.22

Table 3. Linear regression model of OM scores (Study 1)

Variable entered	Regression coefficient		p-value
	B	95% CI for B	
Constant	88.3	81.4 to 95.2	<0.001
Male sex	9.9	2.3 to 17.5	0.011
Age (centered; age-40)	-0.34	-0.60 to -0.08	0.011
Operative treatment	-14.8	-22.4 to -7.3	<0.001
Co-morbidity	-12.1	-23.4 to -0.73	0.037

R<sup>2</sup> = 0.26.

Table 4. Outcome data (Study 2)

	Group 1	Group 2	p-value
OM score, mean (SD)	77 (25)	73 (26)	0.25
OM class, n (%)			0.52
Excellent	51 (40)	29 (33)	
Good	43 (34)	29 (33)	
Fair	22 (17)	22 (25)	
Poor	11 (9)	8 (9)	
TTCP >4 mm, n (%)	6 (4)	4 (3)	0.33
Talar tilt, n (%)	15 (9)	8 (7)	0.51
Re-osteosynthesis, n (%)	3 (2)	5 (4)	0.29
Secondary intervention needed for postoperative infection, n (%)	3 (2)	2 (2)	>0.9

outcome according to the linear regression model were female gender, older age, unstable fracture type, and co-morbidity (Table 3). No non-operatively treated patients required operative fracture fixation during follow-up.

## Study 2

No difference was detected between the two groups regarding age at the time of injury, sex, fracture type, or the type of operative treatment except AITFL exploration and repair; in Group 1, 53% of ankle fractures had a repaired AITFL, while in Group 2, no patient had a sutured AITFL or fixed avulsion. No significant difference was found between the two treatment protocols in terms of postoperative TTCS, talar tilt, or OM score after minimum follow-up (Table 4). Additionally, no between-group differences were identified for rate of postoperative infection, inadequate reduction, or secondary displacement requiring re-osteosynthesis or late reoperations.

## Study 3

The hook test had a sensitivity of 0.25 (95% CI 0.12–0.45), a specificity of 0.98 (95% CI 0.94–1.0), a positive predictive value of 0.75 (95% CI 0.41–0.93), and a negative predictive value of 0.86 (95% CI 0.79–0.91). The ER stress test had a

Table 5. Cross-tabulation of results from the hook and stress tests using the standardized 7.5-Nm ER stress test as reference (Study 3)

		7.5 Nm	
		Positive (n=24)	Negative (n=116)
SC1	Hook test	Positive: 6	Negative: 2
	Stress test	Positive: 18	Negative: 111
SC2	Hook test	Positive: 14	Negative: 5
	Stress test	Positive: 10	Negative: 109
SC3	Both tests	Positive: 4	Negative: 1
		Positive: 20	Negative: 112
		Positive: 13	Negative: 3
		Positive: 11	Negative: 110
		Positive: 14	Negative: 6
		Positive: 10	Negative: 108

Scenario 1 (SC1) = At least one surgeon had a positive finding  
 Scenario 2 (SC2) = Both surgeons agreed on a positive finding  
 Scenario 3 (SC3) = Combination of the hook test and clinical stress test

Table 6. Sensitivity, specificity, and positive and negative predictive values of the hook test and stress test using the standardized 7.5-Nm ER stress test as reference

		Sensitivity	Specificity	Positive predictive value	Negative predictive value
SC1	Hook test	0.25	0.98	0.75	0.86
	Stress test	0.58	0.96	0.74	0.92
SC2	Hook test	0.17	0.99	0.80	0.85
	Stress test	0.54	0.97	0.81	0.91
SC3	Both tests	0.58	0.95	0.70	0.92

SC1–SC3: See Table 5

sensitivity of 0.58 (95% CI 0.39–0.76), a specificity of 0.96 (95% CI 0.90–0.98), a positive predictive value of 0.74 (95% CI 0.51–0.88), and a negative predictive value of 0.92 (95% CI 0.85–0.95; Tables 5 and 6).

When both surgeons agreed on a positive unstable distal tibiofibular joint, the sensitivity values for the hook test and stress test were 0.17 (95% CI 0.07–0.36) and 0.54 (95% CI 0.35–0.72), respectively. The specificity values were 0.99 (95% CI 0.95–1.0) and 0.97 (95% CI 0.93–0.99), the positive predictive values were 0.80 (95% CI 0.38–0.96) and 0.81 (95% CI 0.57–0.93), and the negative predictive values were 0.85 (95% CI 0.78–0.90) and 0.91 (95% CI 0.85–0.95), respectively (Tables 5 and 6). When the hook test and clinical stress test were combined, the sensitivity and the specificity were at the same level: 0.58 (95% CI 0.39–0.76) and 0.95 (95% CI 0.89–0.98), respectively. Both tests had excellent interobserver reliability, with agreement of 99% for the hook test and 98% for the stress test (Table 7).

**Table 7. Cross-tabulation of the interobserver reliability of the hook test and stress test**

Surgeon 1	Surgeon 2		Agreement (%)	Kappa (95% CI)
	Negative	Positive		
Hook test				
Negative	128	2	99	0.83 (0.77–0.87)
Positive	0	5		
Stress test				
Negative	118	2	98	0.89 (0.85–0.92)
Positive	1	14		

#### Study 4

This study was terminated prior to completion due to an unexpectedly low incidence of syndesmotic injuries, and our interim analysis detected no differences between randomized groups. Only 24 of the 140 patients (17%) had positive

standardized 7.5-Nm ER stress tests after malleolar fixation. Twenty patients had delta ligament rupture or avulsion on the medial side, and four had a medial malleolar fracture. Two of the medial malleolar fractures were fragmentary and two were fractures of an anterior colliculus. The stress view was positive three times on TTCS, seven on TFCS, and 14 times on both TTCS and TFCS. Thirteen patients were randomized to the syndesmotic transfixation group with a screw, and 11 to a group with no syndesmotic fixation. No difference was found between the groups except for syndesmotic fixation. There were also no significant differences between the two groups with regard to OM functional score, VAS scale measuring pain and function, or RAND 36-Item Health Survey assessing pain or physical function at one-year follow up (Table 8). There were no between-group differences (syndesmotic screw vs. no fixation) with regard to TTCS (mean 3.5 mm vs. 3.2 mm, respectively;  $p < 0.34$ ), TFCS (mean 5.4 mm vs. 5.5 mm, respectively;  $p < 0.41$ ), or talar tilt (one patient in both groups,  $p > 0.9$ ).

**Table 8. Syndesmotic fixation and self-reported disability at one year. Values are presented as mean, standard deviation (SD), and 95% confidence interval (95% CI) (Study 4)**

	Screw	No fixation	Difference between means	95% CI for the difference	p-value
OM score	79.6 (15.5)	83.6 (13.1)	4.0	–8.2 to 16.3	0.50
VAS pain	25.5 (25.4)	11.3 (12.5)	–14.2	–31.2 to 3.3	0.38
VAS function	22.6 (24.6)	14.9 (15.0)	–7.8	–25.5 to 9.9	0.37
Rand-36 physical function	0.9 (0.2)	1.0 (0.2)	0.1	–0.1 to 0.3	0.23
Rand-36 pain	0.9 (0.4)	1.1 (0.2)	0.2	–0.1 to 0.5	0.32

The values of the Rand-36 are ratios of the study group compared age- (10 years interval) and sex-adjusted general Finnish population

## Discussion

Our results indicate that a simple stability-based fracture classification is useful in choosing between non-operative and operative treatment of ankle fractures; approximately half of the ankle fractures can be treated non-operatively with success. Operative treatment is indicated only for fractures with unstable ankle mortise, which is the case in all bi- and trimalleolar fractures and nearly all high fibular fractures. The clinical relevance of syndesmotic disruption and repair in Lauge-Hansen SE ankle fractures has not been well understood and it is unclear whether transfixation of the distal tibiofibular joint is necessary to achieve a good outcome for this fracture pattern. Our observations suggest that relevant syndesmosis injuries are rare in ankle fractures due to an SER mechanism of injury. Syndesmosis was unstable in 17% of SER ankle fractures, which is clearly less than the previously reported incidence of more than 30% (Nielsen et al. 2004, Jenkinson et al. 2005, Stark et al. 2007) but close to the 20% reported elsewhere (Weening and Bhandari 2005). The clinical relevance of these injuries is still unclear. According to our research, syndesmotic transfixation with a screw in SER ankle fracture in the presence of an unstable distal tibiofibular joint had no influence on functional outcome or pain after one year compared with no fixation.

We measured an incidence of ankle fractures of 154/100,000, in agreement with previous studies (Bengner et al. 1986, Daly et al. 1987, Kannus et al. 1996, Court-Brown et al. 1998, Jensen et al. 1998, van Staa et al. 2001). The overall incidence in women was higher than reported in previous studies, but a dramatic increase in the incidence of ankle fractures in elderly women had been reported previously (Bengner et al. 1986, Kannus et al. 1996). In our study the most common age for ankle fracture was between 55 and 64 years, in agreement with a previous report (Buhr and Cooke 1959). At early ages men were more than twice as likely to sustain a fracture than women, again as reported previously (Court-Brown et al. 1998, Jensen et al. 1998). The highest age-related incidence in women occurred between 45 and 64 years, earlier than in previous studies (Bengner et al. 1986, Court-Brown et al. 1998, Greenfield and Eastell 2001). The overall incidence decreased after 65 years of age, although the age-related incidence increased in women after age 75, as reported previously (Court-Brown et al. 1998).

Lauge-Hansen (Weber B) SER ankle fractures are the most common of all indirect fibular fractures treated by orthopedic surgeons, with as many as 85% of these lateral malleolar fractures stable and without medial injury (Burwell and Charnley 1965). In our series, 75% of the lateral malleolus fractures

were stable and were treated non-operatively with success, an observation in agreement with previous work (Burwell and Charnley 1965). Although there may be an injury of the deep deltoid ligament even without signs of medial injury (Egol et al. 2004), we found that when no signs of medial injury (effusion, pain, or hematoma) were present, no later displacement of the ankle mortise occurred after non-operative treatment, although no stress tests were carried out despite a previous recommendation (Michelson et al. 2007). We conclude that a stress test may not be necessary when there are no clinical signs of deltoid ligament injury. ER stress examination should, however, be carried out in cases of isolated lateral malleolar fracture with medial tenderness or hematoma and no talar shift on mortise radiograph.

Fibular fractures beginning above the ankle joint are considered unstable because they are either pronation-abduction or pronation-ER injuries (Lauge-Hansen 1950); the injury starts from the medial site and, consequently, medial injury is always present. There may be some rare cases in which there is no medial injury (Gardner et al. 2006c) and the ankle mortise is stable, as seen in two cases in our series, but we think that operative treatment is nearly always indicated for high fibular fractures caused by rotational ankle injury. In this injury type, the distal tibiofibular ligaments, interosseal ligament, and the interosseal membrane are injured to the level of the fibular fracture (Lauge-Hansen 1950). In ankle fractures due to an SER rotation mechanism of injury, the fibular fracture starts at the level of the upper ankle joint close to the AITFL, and this is probably why the anterior syndesmosis ligaments may be intact or injured in this fracture pattern.

AITFL repair may offer some mechanical advantages in treating SE-type ankle fractures (Babis et al. 2000, Kabukcuoglu et al. 2000, Gardner et al. 2006, Nelson 2006), but our results suggest that AITFL exploration and repair may not offer any benefit against syndesmosis widening or in favor of a better functional outcome. The change between these two treatment protocols for unstable Weber B-type ankle fractures did not significantly affect patient outcome in terms of OM functional score. The intraoperative ER stress of an isolated AITFL injury may show a 10–12 mm tibiofibular diastase (Cedell 1967), but the AITFL contributes one-third of the stability of distal tibiofibular syndesmosis (Ogilvie-Harris et al. 1994), and sectioning of the AITFL does not by itself cause instability of the talus. Our observations also suggest that soft tissue injury patterns do not always follow Lauge-Hansen's original cadaver observations (Lauge-Hansen 1950, Cedell 1967, Michelson et al. 1997, Gardner et al. 2006, Haraguchi

and Armiger 2009, Kwon et al. 2010) because only 53% of the patients in Group 1 possessed an AITFL injury.

We found that interobserver agreement and specificity were excellent for the hook test and the clinical stress test; however, sensitivity was poor for the hook test and fair for the clinical stress test when a standardized 7.5-Nm ER stress test was used as the reference. If both surgeons agreed on a positive finding of unstable syndesmosis, the sensitivity was even worse, although a combination of the hook test and the clinical stress test led to sensitivity as good as the clinical stress test alone. Poor sensitivity indicates that both tests are deficient at identifying an unstable syndesmosis injury after malleolar fixation, which may lead to late instability, pain, and arthrosis (Leeds and Ehrlich 1984, Chissell and Jones 1995, Tornetta 2000). The excellent specificity of these clinical tests, however, prevents unnecessary syndesmotic transfixation that may often lead to malreduction (Gardner et al. 2006b). Clinical studies also support accuracy of syndesmotic reduction as a critical factor for good clinical results (Leeds and Ehrlich 1984, Chissell and Jones 1995, Weening and Bhandari 2005). These tests may have poor sensitivity for several reasons. During application of the hook test, it is difficult to determine precisely how much and which direction of force should be applied to the fibula, and how much displacement is required to detect instability (Candal-Couto et al. 2004). The same difficulty likely applies to the clinical stress test; the operating surgeon may protect the bony fixation and not stress the ankle with sufficient force. Our experience is that a 7.5-Nm ER force at the level of the ankle mortise is considerably greater than the force of the average clinical stress test, which may explain the poor to fair sensitivity of the clinical test with this standardized test as the reference.

Our determination of the excellent reliability of these tests is mostly the result of the great number of normal syndesmoses and small number of unstable syndesmoses. Thus, our results must be interpreted cautiously. These clinical tests were examined only with SER-type ankle fractures in which syndesmosis injuries are considered to occur infrequently. Also, the severity of a syndesmosis injury can be totally different than with pronation-ER (Weber C) ankle fractures. Direct conclusions about the reliability of these tests in injuries other than those of the SER type cannot be made with the current data.

The low incidence of syndesmotic injuries may be due to methodology differences from previous studies (Takao et al. 2003, Jenkinson et al. 2005, Weening and Bhandari 2005). The maximum increase in the syndesmosis width that is compatible with satisfactory function is reported to be 1–2 mm (Leeds and Ehrlich 1984, Lindsjo 1985b, Chissell and Jones 1995). We defined the stress examination as positive if there was a >2 mm side-to-side difference in the TTCS or TFCS compared with the contralateral uninjured limb because we felt that the 1-mm side-to-side difference used previously (Jenkinson et al. 2005) may be unreliable. Interestingly, the rate of syndesmotic injuries in their study (Jenkinson et al. 2005) was twice that of

our study, which may be attributable to our use of the >2-mm side-to-side difference as a positive finding.

Inability of the medial side injury seems to be related to syndesmosis widening in the ER test. Our observations also confirm earlier reports suggesting that an unstable medial side after malleolar fixation is the most important factor leading to unstable syndesmosis in SER ankle fractures (Tornetta 2000, Jenkinson et al. 2005). Medial injury may be an avulsion fracture or a combination of a ligament injury and a fracture with disruption of the deep portion of the deltoid ligament (Tornetta 2000). In this study, 20 patients had deltoid ligament rupture or avulsion on the medial side, and four patients had a medial malleolar fracture; two medial malleolar fractures were fragmentary and could not be fixed rigidly, and two were fractures of the anterior colliculus. Consequently, at least 22/24 patients probably had an unstable medial side after bony fixation, an incidence in accordance with a previous study (Jenkinson et al. 2005) in which 9/14 patients had complete deltoid ligament disruptions, and five had a medial malleolar fracture. Four of the five medial malleolar fractures were isolated to the anterior colliculus; thus, 13/14 patients had a probable unstable medial side after bony fixation. The deep deltoid ligament is the primary stabilizing structure of the ankle (Harper 1983, Michelson 1995). If the ligament is attached in a large medial malleolus fracture fragment, it can be fixed rigidly with screws, preventing ER of the talus and syndesmosis widening (Boden et al. 1989).

Postoperative treatment with four weeks of immobilization and weight bearing allowed as tolerated was quite an audacious strategy for treatment of syndesmotic injuries. Our observations demonstrate, however, that the duration of immobilization is probably not an important factor in the healing of syndesmotic injuries in SER ankle fractures.

## Methodological issues

Study 1 benefitted from several strengths. The crude incidence and age- and sex-specific incidences were nearly the same as those reported by previous studies (Buhr and Cooke 1959, Bengner et al. 1986, Daly et al. 1987, Kannus et al. 1996, Court-Brown et al. 1998, Jensen et al. 1998, Greenfield and Eastell 2001, van Staa et al. 2001) and it is unlikely that the results were affected by a selection bias. This is the first study in which stability-based classification has been tested in a clinical study in an unselected consecutive series of adult patients living in a defined area. We found that a stability-based classification system was relatively simple to use in everyday clinical practice. However, Studies 1 and 2 were limited by their retrospective design and the relatively high number of patients who were lost to follow-up. It should be noted, however, that the University Hospital of Oulu is the only hospital in the area in which ankle fractures are treated and their sequelae addressed, and thus we think that the results

of these studies are not severely biased. We maintained up-to-date contact addresses because the hospital's electronic database is connected to the Finnish Population Register Center, with automatic address updating. It is also unlikely that the patients who were lost to follow-up would have experienced significantly worse functional results than the other patients. We assume that it is unlikely that these patients would have received operative treatment in another institution, because they would have needed financial support from the University Hospital of Oulu and we would have received information in such cases. We are also well aware of the problems associated with the historic control group in Study 2, although the screws and plates were basically similar surgical techniques and assessment has improved since 1990.

The strengths of Studies 3 and 4 include the prospective randomized designs, the large number of patients, and the use of a reproducible, previously published method. The clinical tests we used are familiar and represent the most commonly used intraoperative tests for detecting unstable syndesmo-

sis (Monga et al. 2008). Study 3 suffered from some limitations, including the relatively small number of patients with unstable syndesmosis injury. Confidence intervals were quite wide, especially for sensitivity measures. We were required to terminate Study 4 prior to completion due to the low rate of syndesmosis injuries, leaving us with the possibility of type II error. A post hoc power analysis using the measured parameters indicated that we required 199 patients per randomized group to obtain a statistically significant difference in the OM score between the groups. The difference, however, would not be clinically significant. A large multicenter study is needed to enroll enough patients with unstable syndesmoses to complete the study, but the clinical relevance of such a study would be minor. Other limitations are the small number of patients with unstable syndesmosis injury, the use of subjective scoring only, and no clinical examination or radiographs one year after injury. Early post-traumatic osteoarthritis may not be determined with instruments we used, and with short-term follow-up.

## Conclusion

Stability-based fracture classification is a simple and useful tool for selecting a treatment method for ankle fractures; approximately one-half of ankle fractures can be treated non-operatively with success. Interobserver agreement is excellent for both the hook test and the clinical stress test, but the sensitivity of these tests is insufficient for detecting unstable syndesmosis injury in SER ankle fractures when using a standardized 7.5-Nm external rotation stress test as a reference. Relevant syndesmotic injuries are rare in SER ankle fractures. Compared with no fixation, exploration and repair of the AITFL or syndesmotic transfixation with a screw in SER ankle fractures has no influence on functional outcome or pain after minimum one year of follow-up.

## References

- Aalto A-M, Aro A, Teperi J. RAND 36 terveyteen liittyvän elämänlaadun mittarina (RAND 36 as a measure of quality of life). Gummerus Kirjapaino Oy, Saarijärvi 1999.
- Ahl T, Dalen N, Lundberg A, Bylund C. Early mobilization of operated on ankle fractures. Prospective, controlled study of 40 bimalleolar cases. *Acta Orthop Scand* 1993; 64(1): 95–99.
- Ahl T, Dalen N, Selvik G. Mobilization after operation of ankle fractures. Good results of early motion and weight bearing. *Acta Orthop Scand* 1988; 59(3): 302–306.
- Ahl T, Dalen N, Selvik G. Ankle fractures. A clinical and roentgenographic stereophotogrammetric study. *Clin Orthop Relat Res* 1989;(245): 246–255.
- Ali M S, McLaren C A, Rouholamin E, O'Connor B T. Ankle fractures in the elderly: nonoperative or operative treatment. *J Orthop Trauma* 1987; 1(4): 275–280.
- Amendola A. Controversies in diagnosis and management of syndesmosis injuries of the ankle. *Foot Ankle* 1992; 13(1): 44–50.
- Babis G C, Papagelopoulos P J, Tsarouchas J, Zoubos A B, Korres D S, Niki-foridis P. Operative treatment for Maisonneuve fracture of the proximal fibula. *Orthopedics* 2000; 23(7): 687–690.
- Bachmann L M, Kolb E, Koller M T, Steurer J, ter R G. Accuracy of Ottawa ankle rules to exclude fractures of the ankle and mid-foot: systematic review. *BMJ* 2003; 326(7386): 417–419.
- Bauer M, Bengner U, Johnell O, Redlund-Johnell I. Supination-eversion fractures of the ankle joint: changes in incidence over 30 years. *Foot Ankle* 1987a; 8(1): 26–28.
- Bauer M, Bergstrom B, Hemborg A, Sandegard J. Malleolar fractures: non-operative versus operative treatment. A controlled study. *Clin Orthop Relat Res* 1985a;(199): 17–27.
- Bauer M, Johnell O, Redlund-Johnell I, Johnsson K. Ankle fractures. *Foot Ankle* 1987b; 8(1): 23–25.
- Bauer M, Jonsson K, Nilsson B. Thirty-year follow-up of ankle fractures. *Acta Orthop Scand* 1985b; 56(2): 103–106.
- Bava E, Charlton T, Thordarson D. Ankle fracture syndesmosis fixation and management: the current practice of orthopedic surgeons. *Am J Orthop (Belle Mead NJ)* 2010; 39(5): 242–246.
- Beauchamp C G, Clay N R, Thexton P W. Displaced ankle fractures in patients over 50 years of age. *J Bone Joint Surg Br* 1983; 65(3): 329–332.
- Bengner U, Johnell O, Redlund-Johnell I. Epidemiology of ankle fracture 1950 and 1980. Increasing incidence in elderly women. *Acta Orthop Scand* 1986; 57(1): 35–37.
- Beumer A. Chronic instability of the anterior syndesmosis of the ankle. *Acta Orthop Suppl* 2007; 78(327): 4–36.
- Beumer A, Campo M M, Niesing R, Day J, Kleinrensink G J, Swierstra B A. Screw fixation of the syndesmosis: a cadaver model comparing stainless steel and titanium screws and three and four cortical fixation. *Injury* 2005; 36(1): 60–64.
- Beumer A, Valstar E R, Garling E H, van Leeuwen W J, Sikma W, Niesing R, Ranstam J, Swierstra B A. External rotation stress imaging in syndesmosis injuries of the ankle: comparison of lateral radiography and radiostereometry in a cadaveric model. *Acta Orthop Scand* 2003; 74(2): 201–205.
- Beumer A, van Hemert W L, Niesing R, Entius C A, Ginai A Z, Mulder P G, Swierstra B A. Radiographic measurement of the distal tibiofibular syndesmosis has limited use. *Clin Orthop Relat Res* 2004;(423): 227–234.
- Boden S D, Labropoulos P A, McCowin P, Lestini W F, Hurwitz S R. Mechanical considerations for the syndesmosis screw. A cadaver study. *J Bone Joint Surg Am* 1989; 71(10): 1548–1555.
- Boytim M J, Fischer D A, Neumann L. Syndesmotic ankle sprains. *Am J Sports Med* 1991; 19(3): 294–298.
- Brage M E, Rockett M, Vraney R, Anderson R, Toledano A. Ankle fracture classification: a comparison of reliability of three X-ray views versus two. *Foot Ankle Int* 1998; 19(8): 555–562.
- Brand D A, Frazier W H, Kohlhepp W C, Shea K M, Hoefler A M, Ecker M D, Kornguth P J, Pais M J, Light T R. A protocol for selecting patients with injured extremities who need x-rays. *N Engl J Med* 1982; 306(6): 333–339.
- Brandser E A, Berbaum K S, Dorfman D D, Braksiek R J, el-Khoury G Y, Saltzman C L, Marsh J L, Clark W A. Contribution of individual projections alone and in combination for radiographic detection of ankle fractures. *Am J Roentgenol* 2000; 174(6): 1691–1697.
- Brooks S C, Potter B T, Rainey J B. Inversion injuries of the ankle: clinical assessment and radiographic review. *BMJ (Clin Res Ed)* 1981; 282(6264): 607–608.
- Broos P L, Bisschop A P. Operative treatment of ankle fractures in adults: correlation between types of fracture and final results. *Injury* 1991; 22(5): 403–406.
- Brown O L, Dirschl D R, Obremesky W T. Incidence of hardware-related pain and its effect on functional outcomes after open reduction and internal fixation of ankle fractures. *J Orthop Trauma* 2001; 15(4): 271–274.
- Brown T D, Hurlbut P T, Hale J E, Gibbons T A, Caldwell N J, Marsh J L, Nepola J V. Effects of imposed hindfoot constraint on ankle contact mechanics for displaced lateral malleolar fractures. *J Orthop Trauma* 1994; 8(6): 511–519.
- Buckwalter J A, Einhorn T A, Marsh J L. In: Rockwood and Green's Fractures in Adults. (Eds. Bucholz RW, Heckman JD). Lippincott Williams & Wilkins, Philadelphia, 2001; 245–271.
- Buhr A J, Cooke A M. Fracture patterns. *Lancet* 1959; 1(7072): 531–536.
- Burwell H N, Charnley A D. The treatment of displaced fractures at the ankle by rigid internal fixation and early joint movement. *J Bone Joint Surg Br* 1965; 47(4): 634–660.
- Calhoun J H, Li F, Ledbetter B R, Viegas S F. A comprehensive study of pressure distribution in the ankle joint with inversion and eversion. *Foot Ankle Int* 1994; 15(3): 125–133.
- Candal-Couto J J, Burrow D, Bromage S, Briggs P J. Instability of the tibiofibular syndesmosis: have we been pulling in the wrong direction? *Injury* 2004; 35(8): 814–818.
- Cedell C A. Outward rotation-supination injuries of the ankle. *Clin Orthop Relat Res* 1965; 42: 97–100.
- Cedell C A. Supination-outward rotation injuries of the ankle. A clinical and roentgenological study with special reference to the operative treatment. *Acta Orthop Scand* 1967; Suppl.
- Cheung Y, Perrich K D, Gui J, Koval K J, Goodwin D W. MRI of isolated distal fibular fractures with widened medial clear space on stressed radiographs: which ligaments are interrupted? *AJR Am J Roentgenol* 2009; 192(1): W7–12.
- Chissell H R, Jones J. The influence of a diastasis screw on the outcome of Weber type-C ankle fractures. *J Bone Joint Surg Br* 1995; 77(3): 435–438.
- Cimino W, Ichtertz D, Slabaugh P. Early mobilization of ankle fractures after open reduction and internal fixation. *Clin Orthop Relat Res* 1991;(267): 152–156.
- Clarke H J, Michelson J D, Cox Q G, Jinnah R H. Tibio-talar stability in bimalleolar ankle fractures: a dynamic in vitro contact area study. *Foot Ankle* 1991; 11(4): 222–227.
- Close J R. Some applications of the functional anatomy of the ankle joint. *J Bone Joint Surg Am* 1956; 38-A(4): 761–781.

- Cockshott W P, Jenkin J K, Pui M. Limiting the use of routine radiography for acute ankle injuries. *Can Med Assoc J* 1983; 129(2): 129–131.
- Cottom J M, Hyer C F, Philbin T M, Berlet G C. Transosseous fixation of the distal tibiofibular syndesmosis: comparison of an interosseous suture and endobutton to traditional screw fixation in 50 cases. *J Foot Ankle Surg* 2009; 48(6): 620–630.
- Cotton FJ. The ankle. In: *Dislocations and Joint-Fractures*. WB Saunders, Philadelphia, 1910; 535–589.
- Court-Brown CM, McBirnie J, Wilson G. Adult ankle fractures--an increasing problem? *Acta Orthop Scand* 1998; 69(1): 43–47.
- Craig W L, III, Dirschl D R. Effects of binary decision making on the classification of fractures of the ankle. *J Orthop Trauma* 1998; 12(4): 280–283.
- Daly P J, Fitzgerald R H, Jr., Melton L J, Ilstrup D M. Epidemiology of ankle fractures in Rochester, Minnesota. *Acta Orthop Scand* 1987; 58(5): 539–544.
- Dunlop M G, Beattie T F, White G K, Raab G M, Doull R I. Guidelines for selective radiological assessment of inversion ankle injuries. *BMJ (Clin Res Ed)* 1986; 293(6547): 603–605.
- Earll M, Wayne J, Brodrick C, Vokshoor A, Adelaar R. Contribution of the deltoid ligament to ankle joint contact characteristics: a cadaver study. *Foot Ankle Int* 1996; 17(6): 317–324.
- Ebraheim N A, Mekhail A O, Gargasz S S. Ankle fractures involving the fibula proximal to the distal tibiofibular syndesmosis. *Foot Ankle Int* 1997; 18(8): 513–521.
- Edwards G S, Jr., DeLee J C. Ankle diastasis without fracture. *Foot Ankle* 1984; 4(6): 305–312.
- Egol K A, Amirtharajah M, Tejwani N C, Capla E L, Koval K J. Ankle stress test for predicting the need for surgical fixation of isolated fibular fractures. *J Bone Joint Surg Am* 2004; 86-A(11): 2393–2398.
- Elgafy H, Semaan H B, Blessinger B, Wassef A, Ebraheim N A. Computed tomography of normal distal tibiofibular syndesmosis. *Skeletal Radiol* 2010; 39(6): 559–564.
- Eventov I, Salama R, Goodwin D R, Weissman S L. An evaluation of surgical and conservative treatment of fractures of the ankle in 200 patients. *J Trauma* 1978; 18(4): 271–274.
- Finsen V, Saetermo R, Kibsgaard L, Farran K, Engebretsen L, Bolz K D, Benum P. Early postoperative weight-bearing and muscle activity in patients who have a fracture of the ankle. *J Bone Joint Surg Am* 1989; 71(1): 23–27.
- Fleiss J L. *Statistical methods for rates and proportions*. 2nd ed. New York: John Wiley & Sons; 1981:217–8.
- Gardner M J, Brodsky A, Briggs S M, Nielson J H, Lorich D G. Fixation of posterior malleolar fractures provides greater syndesmotic stability. *Clin Orthop Relat Res* 2006a; 447: 165–171.
- Gardner M J, Demetrakopoulos D, Briggs S M, Helfet D L, Lorich D G. Malreduction of the tibiofibular syndesmosis in ankle fractures. *Foot Ankle Int* 2006b; 27(10): 788–792.
- Gardner M J, Demetrakopoulos D, Briggs S M, Helfet D L, Lorich D G. The ability of the Lauge-Hansen classification to predict ligament injury and mechanism in ankle fractures: an MRI study. *J Orthop Trauma* 2006c; 20(4): 267–272.
- Georgiadis G M, White D B. Modified tension band wiring of medial malleolar ankle fractures. *Foot Ankle Int* 1995; 16(2): 64–68.
- Gill J B, Risko T, Raducan V, Grimes J S, Schutt R C, Jr. Comparison of manual and gravity stress radiographs for the evaluation of supination-external rotation fibular fractures. *J Bone Joint Surg Am* 2007; 89(5): 994–999.
- Goergen T G, Danzig L A, Resnick D, Owen C A. Roentgenographic evaluation of the tibiotalar joint. *J Bone Joint Surg Am* 1977; 59(7): 874–877.
- Greenfield D M, Eastell R. Risk factors for ankle fracture. *Osteoporos Int* 2001; 12(2): 97–103.
- Hahn D M, Colton C L. Malleoli. In: *AO Principles of Fracture Management*. Vol. 2. (Eds. Rüedi T P, Buckley R E, Moran C G). AO Publishing, Davos, 2007; 871–897.
- Haraguchi N, Armiger R S. A new interpretation of the mechanism of ankle fracture. *J Bone Joint Surg Am* 2009; 91(4): 821–829.
- Harper M C. An anatomic study of the short oblique fracture of the distal fibula and ankle stability. *Foot Ankle* 1983; 4(1): 23–29.
- Harper M C. The short oblique fracture of the distal fibula without medial injury: an assessment of displacement. *Foot Ankle Int* 1995; 16(4): 181–186.
- Harper M C, Keller T S. A radiographic evaluation of the tibiofibular syndesmosis. *Foot Ankle* 1989; 10(3): 156–160.
- Hays R D, Morales L S. The RAND-36 measure of health-related quality of life. *Ann Med* 2001; 33(5): 350–357.
- Hedstrom M, Ahl T, Dalen N. Early postoperative ankle exercise. A study of postoperative lateral malleolar fractures. *Clin Orthop Relat Res* 1994;(300): 193–196.
- Hopkinson W J, St P P, Ryan J B, Wheeler J H. Syndesmosis sprains of the ankle. *Foot Ankle* 1990; 10(6): 325–330.
- Hovis W D, Kaiser B W, Watson J T, Bucholz R W. Treatment of syndesmotic disruptions of the ankle with bioabsorbable screw fixation. *J Bone Joint Surg Am* 2002; 84-A(1): 26–31.
- Hughes J. The medial malleolus in ankle fractures. *Orthop Clin North Am* 1980; 11(3): 649–660.
- Hughes J L, Weber H, Willenegger H, Kuner E H. Evaluation of ankle fractures: non-operative and operative treatment. *Clin Orthop Relat Res* 1979;(138): 111–119.
- Jaskulka R A, Ittner G, Schedl R. Fractures of the posterior tibial margin: their role in the prognosis of malleolar fractures. *J Trauma* 1989; 29(11): 1565–1570.
- Jenkinson R J, Sanders D W, MacLeod M D, Domonkos A, Lydestadt J. Intraoperative diagnosis of syndesmosis injuries in external rotation ankle fractures. *J Orthop Trauma* 2005; 19(9): 604–609.
- Jensen S L, Andresen B K, Mencke S, Nielsen P T. Epidemiology of ankle fractures. A prospective population-based study of 212 cases in Aalborg, Denmark. *Acta Orthop Scand* 1998; 69(1): 48–50.
- Joy G, Patzakis M J, Harvey J P, Jr. Precise evaluation of the reduction of severe ankle fractures. *J Bone Joint Surg Am* 1974; 56(5): 979–993.
- Kabukcuoglu Y, Kucukkaya M, Eren T, Gorgec M, Kuzgun U. The ANK device: a new approach in the treatment of the fractures of the lateral malleolus associated with the rupture of the syndesmosis. *Foot Ankle Int* 2000; 21(9): 753–758.
- Kannus P, Palvanen M, Niemi S, Parkkari J, Jarvinen M. Increasing number and incidence of low-trauma ankle fractures in elderly people: Finnish statistics during 1970–2000 and projections for the future. *Bone* 2002; 31(3): 430–433.
- Kannus P, Parkkari J, Niemi S, Palvanen M. Epidemiology of osteoporotic ankle fractures in elderly persons in Finland. *Ann Intern Med* 1996; 125(12): 975–978.
- Kim S K, Oh J K. One or two lag screws for fixation of Danis-Weber type B fractures of the ankle. *J Trauma* 1999; 46(6): 1039–1044.
- Koval K J, Egol K A, Cheung Y, Goodwin D W, Spratt K F. Does a positive ankle stress test indicate the need for operative treatment after lateral malleolus fracture? A preliminary report. *J Orthop Trauma* 2007; 21(7): 449–455.
- Koval K J, Petraco D M, Kummer F J, Bharam S. A new technique for complex fibula fracture fixation in the elderly: a clinical and biomechanical evaluation. *J Orthop Trauma* 1997; 11(1): 28–33.
- Kristensen K D, Hansen T. Closed treatment of ankle fractures. Stage II supination-eversion fractures followed for 20 years. *Acta Orthop Scand* 1985; 56(2): 107–109.
- Kwon J Y, Chacko A T, Kadzielski J J, Appleton P T, Rodriguez E K. A novel methodology for the study of injury mechanism: ankle fracture analysis using injury videos posted on YouTube.com. *J Orthop Trauma* 2010; 24(8): 477–482.
- Lambert K L. The weight-bearing function of the fibula. A strain gauge study. *J Bone Joint Surg Am* 1971; 53(3): 507–513.

- Landis JR, Koch GG. The measurement of observer agreement for categorical data. *Biometrics*. 1977;33:159–74.
- Lash N, Horne G, Fielden J, Devane P. Ankle fractures: functional and life-style outcomes at 2 years. *ANZ J Surg* 2002; 72(10): 724–730.
- Lauge-Hansen N. Fractures of the ankle. II. Combined experimental-surgical and experimental-roentgenologic investigations. *Arch Surg* 1950; 60(5): 957–985.
- Leeds H C, Ehrlich M G. Instability of the distal tibiofibular syndesmosis after bimalleolar and trimalleolar ankle fractures. *J Bone Joint Surg Am* 1984; 66(4): 490–503.
- Lehto M, Tunturi T. Improvement 2–9 years after ankle fracture. *Acta Orthop Scand* 1990; 61(1): 80.
- Lindsjo U. Classification of ankle fractures: the Lauge-Hansen or AO system? *Clin Orthop Relat Res* 1985a;(199): 12–16.
- Lindsjo U. Operative treatment of ankle fracture-dislocations. A follow-up study of 306/321 consecutive cases. *Clin Orthop Relat Res* 1985b;(199): 28–38.
- Lloyd S. Selective radiographic assessment of acute ankle injuries in the emergency department: barriers to implementation. *CMAJ* 1986; 135(9): 973–974.
- Lundberg A. Kinematics of the ankle and foot. In vivo roentgen stereophotogrammetry. *Acta Orthop Scand Suppl* 1989; 233: 1–24.
- Magid D, Michelson J D, Ney D R, Fishman E K. Adult ankle fractures: comparison of plain films and interactive two- and three-dimensional CT scans. *AJR Am J Roentgenol* 1990; 154(5): 1017–1023.
- Makwana N K, Bhowal B, Harper W M, Hui A W. Conservative versus operative treatment for displaced ankle fractures in patients over 55 years of age. A prospective, randomised study. *J Bone Joint Surg Br* 2001; 83(4): 525–529.
- Marsh JL, Saltzman CL. Ankle fractures. In: *Rockwood and Green's Fractures in Adults*. (Eds. Buchholz RW, Heckman JD). Lippincott Williams & Wilkins, Philadelphia, 2001; 2001–2090.
- McBryde A, Chiasson B, Wilhelm A, Donovan F, Ray T, Bacilla P. Syndesmosis screw placement: a biomechanical analysis. *Foot Ankle Int* 1997; 18(5): 262–266.
- Michelson J, Solocoff D, Waldman B, Kendall K, Ahn U. Ankle fractures. The Lauge-Hansen classification revisited. *Clin Orthop Relat Res* 1997;(345): 198–205.
- Michelson J D. Fractures about the ankle. *J Bone Joint Surg Am* 1995; 77(1): 142–152.
- Michelson J D, Hamel A J, Buczek F L, Sharkey N A. Kinematic behavior of the ankle following malleolar fracture repair in a high-fidelity cadaver model. *J Bone Joint Surg Am* 2002; 84-A(11): 2029–2038.
- Michelson J D, Magid D, McHale K. Clinical utility of a stability-based ankle fracture classification system. *J Orthop Trauma* 2007; 21(5): 307–315.
- Michelson J D, Magid D, Ney D R, Fishman E K. Examination of the pathologic anatomy of ankle fractures. *J Trauma* 1992; 32(1): 65–70.
- Michelson J D, Varner K E, Checcone M. Diagnosing deltoid injury in ankle fractures: the gravity stress view. *Clin Orthop Relat Res* 2001;(387): 178–182.
- Miller R S, Weinhold P S, Dahners L E. Comparison of tricortical screw fixation versus a modified suture construct for fixation of ankle syndesmosis injury: a biomechanical study. *J Orthop Trauma* 1999; 13(1): 39–42.
- Milz P, Milz S, Steinborn M, Mittlmeier T, Putz R, Reiser M. Lateral ankle ligaments and tibiofibular syndesmosis. 13-MHz high-frequency sonography and MRI compared in 20 patients. *Acta Orthop Scand* 1998; 69(1): 51–55.
- Monga P, Kumar A, Simons A, Panikker V. Management of distal tibio-fibular syndesmosis injuries: a snapshot of current practice. *Acta Orthop Belg* 2008; 74(3): 365–369.
- Moore J A, Jr., Shank J R, Morgan S J, Smith W R. Syndesmosis fixation: a comparison of three and four cortices of screw fixation without hardware removal. *Foot Ankle Int* 2006; 27(8): 567–572.
- Muller M, Allgower M, Schneider R, Willenegger H. *Manual of Internal Fixation. Techniques Recommended by the AO Group*. Springer, New York 1979.
- Muller M, Allgower M, Schneider R, Willenegger H. In: *Manual of Internal Fixation. Techniques Recommended by the AO Group*. Springer, New York 1991.
- Nelson O A. Examination and repair of the AITFL in transmalleolar fractures. *J Orthop Trauma* 2006; 20(9): 637–643.
- Nielsen J O, Dons-Jensen H, Sorensen H T. Lauge-Hansen classification of malleolar fractures. An assessment of the reproducibility in 118 cases. *Acta Orthop Scand* 1990; 61(5): 385–387.
- Nielson J H, Sallis J G, Potter H G, Helfet D L, Lorich D G. Correlation of interosseous membrane tears to the level of the fibular fracture. *J Orthop Trauma* 2004; 18(2): 68–74.
- Nousiainen M T, McConnell A J, Zdero R, McKee M D, Bhandari M, Schemitsch E H. The influence of the number of cortices of screw purchase and ankle position in Weber C ankle fracture fixation. *J Orthop Trauma* 2008; 22(7): 473–478.
- Ogilvie-Harris D J, Reed S C. Disruption of the ankle syndesmosis: diagnosis and treatment by arthroscopic surgery. *Arthroscopy* 1994; 10(5): 561–568.
- Ogilvie-Harris D J, Reed S C, Hedman T P. Disruption of the ankle syndesmosis: biomechanical study of the ligamentous restraints. *Arthroscopy* 1994; 10(5): 558–560.
- Olerud C. The effect of the syndesmosis screw on the extension capacity of the ankle joint. *Arch Orthop Trauma Surg* 1985; 104(5): 299–302.
- Olerud C, Molander H. A scoring scale for symptom evaluation after ankle fracture. *Arch Orthop Trauma Surg* 1984; 103(3): 190–194.
- Ostrum R F. Posterior plating of displaced Weber B fibula fractures. *J Orthop Trauma* 1996; 10(3): 199–203.
- Ostrum R F, Litsky A S. Tension band fixation of medial malleolus fractures. *J Orthop Trauma* 1992; 6(4): 464–468.
- Pankovich A M. Fractures of the fibula at the distal tibiofibular syndesmosis. *Clin Orthop Relat Res* 1979;(143): 138–147.
- Pankovich A M, Shivaram M S. Anatomical basis of variability in injuries of the medial malleolus and the deltoid ligament. II. Clinical studies. *Acta Orthop Scand* 1979; 50(2): 225–236.
- Peter R E, Harrington R M, Henley M B, Tencer A F. Biomechanical effects of internal fixation of the distal tibiofibular syndesmosis joint: comparison of two fixation techniques. *J Orthop Trauma* 1994; 8(3): 215–219.
- Pettrone F A, Gail M, Pee D, Fitzpatrick T, Van Herpe L B. Quantitative criteria for prediction of the results after displaced fracture of the ankle. *J Bone Joint Surg Am* 1983; 65(5): 667–677.
- Phillips W A, Schwartz H S, Keller C S, Woodward H R, Rudd W S, Spiegel P G, Laros G S. A prospective, randomized study of the management of severe ankle fractures. *J Bone Joint Surg Am* 1985; 67(1): 67–78.
- Procter P, Paul J P. Ankle joint biomechanics. *J Biomech* 1982; 15(9): 627–634.
- Purvis G D. Displaced, unstable ankle fractures: classification, incidence, and management of a consecutive series. *Clin Orthop Relat Res* 1982;(165): 91–98.
- Raasch W G, Larkin J J, Draganich L F. Assessment of the posterior malleolus as a restraint to posterior subluxation of the ankle. *J Bone Joint Surg Am* 1992; 74(8): 1201–1206.
- Ramsey P L, Hamilton W. Changes in tibiotalar area of contact caused by lateral talar shift. *J Bone Joint Surg Am* 1976; 58(3): 356–357.
- Rasmussen O. Stability of the ankle joint. Analysis of the function and traumatology of the ankle ligaments. *Acta Orthop Scand Suppl* 1985; 211: 1–75.
- Rasmussen O, Kromann-Andersen C, Boe S. Deltoid ligament. Functional analysis of the medial collateral ligamentous apparatus of the ankle joint. *Acta Orthop Scand* 1983; 54(1): 36–44.
- Rasmussen S, Madsen P V, Bennicke K. Observer variation in the Lauge-Hansen classification of ankle fractures. Precision improved by instruction. *Acta Orthop Scand* 1993; 64(6): 693–694.
- Rowley D I, Norris S H, Duckworth T. A prospective trial comparing operative and manipulative treatment of ankle fractures. *J Bone Joint Surg Br* 1986; 68(4): 610–613.
- Ryd L, Bengtsson S. Isolated fracture of the lateral malleolus requires no treatment. 49 prospective cases of supination-eversion type II ankle fractures. *Acta Orthop Scand* 1992; 63(4): 443–446.
- Sammarco G J, Burstein A H, Frankel V H. Biomechanics of the ankle: a kinematic study. *Orthop Clin North Am* 1973; 4(1): 75–96.
- Sasse M, Nigg B M, Stefanyshyn D J. Tibiotalar motion--effect of fibular displacement and deltoid ligament transection: in vitro study. *Foot Ankle Int* 1999; 20(11): 733–737.
- Schaffer J J, Manoli A. The antiglide plate for distal fibular fixation. A biomechanical comparison with fixation with a lateral plate. *J Bone Joint Surg Am* 1987; 69(4): 596–604.
- Scheidt K B, Stiehl J B, Skrade D A, Barnhardt T. Posterior malleolar ankle fractures: an in vitro biomechanical analysis of stability in the loaded and unloaded states. *J Orthop Trauma* 1992; 6(1): 96–101.

- Scalfani S J. Ligamentous injury of the lower tibiofibular syndesmosis: radiographic evidence. *Radiology* 1985; 156(1): 21–27.
- Skie M C, Ebraheim N A, Woldenberg L, Randall K. Fracture of the anterior colliculus. *J Trauma* 1995; 38(4): 642–647.
- Soin S P, Knight T A, Dinah A F, Mears S C, Swierstra B A, Belkoff S M. Suture-button versus screw fixation in a syndesmosis rupture model: a biomechanical comparison. *Foot Ankle Int* 2009; 30(4): 346–352.
- Stark E, Tornetta P, III, Creevy W R. Syndesmotic instability in Weber B ankle fractures: a clinical evaluation. *J Orthop Trauma* 2007; 21(9): 643–646.
- Stiell I G, Greenberg G H, McKnight R D, Wells G A. Ottawa ankle rules for radiography of acute injuries. *N Z Med J* 1995; 108(996): 111.
- Stoffel K, Wysocki D, Baddour E, Nicholls R, Yates P. Comparison of two intraoperative assessment methods for injuries to the ankle syndesmosis. A cadaveric study. *J Bone Joint Surg Am* 2009; 91(11): 2646–2652.
- Sujitkumar P, Hadfield J M, Yates D W. Sprain or fracture? An analysis of 2000 ankle injuries. *Arch Emerg Med* 1986; 3(2): 101–106.
- Takao M, Ochi M, Naito K, Iwata A, Kawasaki K, Tobita M, Miyamoto W, Oae K. Arthroscopic diagnosis of tibiofibular syndesmosis disruption. *Arthroscopy* 2001; 17(8): 836–843.
- Takao M, Ochi M, Oae K, Naito K, Uchio Y. Diagnosis of a tear of the tibiofibular syndesmosis. The role of arthroscopy of the ankle. *J Bone Joint Surg Br* 2003; 85(3): 324–329.
- Teitz C C, Harrington R M. A biochemical analysis of the squeeze test for sprains of the syndesmotic ligaments of the ankle. *Foot Ankle Int* 1998; 19(7): 489–492.
- Thompson M C, Gesink D S. Biomechanical comparison of syndesmosis fixation with 3.5- and 4.5-millimeter stainless steel screws. *Foot Ankle Int* 2000; 21(9): 736–741.
- Thomsen N O, Overgaard S, Olsen L H, Hansen H, Nielsen S T. Observer variation in the radiographic classification of ankle fractures. *J Bone Joint Surg Br* 1991; 73(4): 676–678.
- Thordarson D B, Samuelson M, Shepherd L E, Merkle P F, Lee J. Bioabsorbable versus stainless steel screw fixation of the syndesmosis in pronation-lateral rotation ankle fractures: a prospective randomized trial. *Foot Ankle Int* 2001; 22(4): 335–338.
- Tornetta P, III. Competence of the deltoid ligament in bimalleolar ankle fractures after medial malleolar fixation. *J Bone Joint Surg Am* 2000; 82(6): 843–848.
- Tornetta P, III, Creevy W. Lag screw only fixation of the lateral malleolus. *J Orthop Trauma* 2001; 15(2): 119–121.
- Tornetta P, III, Spoo J E, Reynolds F A, Lee C. Overtightening of the ankle syndesmosis: is it really possible? *J Bone Joint Surg Am* 2001; 83-A(4): 489–492.
- Treadwell J R, Fallat L M. The antiglide plate for the Danis-Weber type-B fibular fracture: a review of 71 cases. *J Foot Ankle Surg* 1993; 32(6): 573–579.
- Tunturi T, Kempainen K, Patiala H, Suokas M, Tamminen O, Rokkanen P. Importance of anatomical reduction for subjective recovery after ankle fracture. *Acta Orthop Scand* 1983; 54(4): 641–647.
- van den Bekerom M P, Haverkamp D, Kerkhoffs G M, van Dijk C N. Syndesmotic stabilization in pronation external rotation ankle fractures. *Clin Orthop Relat Res* 2010; 468(4): 991–995.
- van Laarhoven C J, Meeuwis J D, van d W. Postoperative treatment of internally fixed ankle fractures: a prospective randomised study. *J Bone Joint Surg Br* 1996; 78(3): 395–399.
- van Staa T P, Dennison E M, Leufkens H G, Cooper C. Epidemiology of fractures in England and Wales. *Bone* 2001; 29(6): 517–522.
- Vangness C T, Jr., Carter V, Hunt T, Kerr R, Newton E. Radiographic diagnosis of ankle fractures: are three views necessary? *Foot Ankle Int* 1994; 15(4): 172–174.
- Vogl T J, Hochmuth K, Diebold T, Lubrich J, Hofmann R, Stockle U, Sollner O, Bisson S, Sudkamp N, Mauerer J, Haas N, Felix R. Magnetic resonance imaging in the diagnosis of acute injured distal tibiofibular syndesmosis. *Invest Radiol* 1997; 32(7): 401–409.
- Weber M, Burmeister H, Flueckiger G, Krause F G. The use of weightbearing radiographs to assess the stability of supination-external rotation fractures of the ankle. *Arch Orthop Trauma Surg* 2010; 130(5): 693–698.
- Weening B, Bhandari M. Predictors of functional outcome following trans-syndesmotic screw fixation of ankle fractures. *J Orthop Trauma* 2005; 19(2): 102–108.
- Wikeroy A K, Hoiness P R, Andreassen G S, Hellund J C, Madsen J E. No difference in functional and radiographic results 8.4 years after quadricortical compared with tricortical syndesmosis fixation in ankle fractures. *J Orthop Trauma* 2010; 24(1): 17–23.
- Winkler B, Weber B G, Simpson L A. The dorsal antiglide plate in the treatment of Danis-Weber type-B fractures of the distal fibula. *Clin Orthop Relat Res* 1990;(259): 204–209.
- Wiss D. In: *Master Techniques in Orthopaedic Surgery. Fractures*. Lippincott Williams & Wilkins, Philadelphia, 2006; 2: 551–567.
- Wuest T K. Injuries to the Distal Lower Extremity Syndesmosis. *J Am Acad Orthop Surg* 1997; 5(3): 172–181.
- Xenos J S, Hopkinson W J, Mulligan M E, Olson E J, Popovic N A. The tibiofibular syndesmosis. Evaluation of the ligamentous structures, methods of fixation, and radiographic assessment. *Bone Joint Surg Am* 1995; 77(6): 847–856.
- Yablon I G, Heller F G, Shouse L. The key role of the lateral malleolus in displaced fractures of the ankle. *J Bone Joint Surg Am* 1977; 59(2): 169–173.
- Yamaguchi K, Martin C H, Boden S D, Labropoulos P A. Operative treatment of syndesmotic disruptions without use of a syndesmotic screw: a prospective clinical study. *Foot Ankle Int* 1994; 15(8): 407–414.
- Yde J, Kristensen K D. Ankle fractures. Supination-eversion fractures stage II. Primary and late results of operative and non-operative treatment. *Acta Orthop Scand* 1980a; 51(4): 695–702.
- Yde J, Kristensen K D. Ankle fractures: supination-eversion fractures of stage IV. Primary and late results of operative and non-operative treatment. *Acta Orthop Scand* 1980b; 51(6): 981–990.
- Zeegers A V, Van Raay J J, van der Werken C. Ankle fractures treated with a stabilizing shoe. *Acta Orthop Scand* 1989; 60(5): 597–599.



