

10-year results following impaction bone grafting of major bone defects in 29 rotational and hinged knee revision arthroplasties

A follow-up of a previous report

Verena Hilgen¹, Mustafa Citak¹, Eik Vettorazzi², Carl Haasper¹, Kimberly Day¹, Michael Amling³, Thorsten Gehrke¹, and Matthias Gebauer^{1,3}

¹Department of Orthopaedic Surgery, Helios-ENDO-Klinik Hamburg; Departments of ²Medical Biometry and Epidemiology and ³Osteology and Biomechanics, University Medical Center Hamburg-Eppendorf, Hamburg, Germany.

Correspondence: matthias.gebauer@helios-kliniken.de

Submitted 13-03-01. Accepted 13-05-06

Background and purpose — Substantial bone loss in revision total knee arthroplasty (TKA) is a challenging problem. We studied whether impaction bone grafting provides long-term restoration of bone stock in the treatment of major bone defects in revision surgery of rotational and hinged knee arthroplasties (LINK Endo-Model).

Patients and methods — Between 1996 and 2006, 29 knees in 29 patients underwent revision procedures of rotational and hinged knee arthroplasties using impaction bone grafting (IBG) to reconstruct major bone defects. At the latest follow-up, the clinical examination included the Knee Society score (KSS), standardized radiographs, and a questionnaire for the WOMAC score.

Results — After a mean follow-up of 10 (6–13) years, 14 knees with 19 IBG reconstructions (5 total, 9 partial revisions) had failed. 12 knees were treated with re-revision surgery mean 5 (1–12) years after the first revision, due to mechanical failure and aseptic loosening of the components. In all these failed cases, the surgeon observed a lack of incorporation with bone graft resorption in the femur or tibia during the re-revision procedure. In all 15 knees that were not re-revised, with 21 reconstructions (6 total, 9 partial revisions), an improvement in the combined KSS score (knee score + function score) of 60 points ($p < 0.001$) was found at the latest follow-up. In 12 of these knees, a clear incorporation with no visible radiolucent lines around the component and no sign of substantial graft resorption was noted, while unclear radiographic graft incorporation was seen in 3 knees.

Interpretation — Our results clearly indicate that IBG alone is not a methodologically sound technique in the revision of rotational and hinged knee arthroplasties.

Substantial bone loss in revision total knee arthroplasty (TKA) is a challenging clinical problem. As implants fail, host bone is lost as a result of a combination of stress-shielding, osteolysis, instability, implant failure, and/or infection. This problem may be augmented by bone loss during removal of the failed implant. Options for reconstruction include metal augments, cement with screws, autografts, allografts, and tumor prostheses (Backstein et al. 2006, Radnay et al. 2006, Engh et al. 2007). Impaction bone grafting (IBG) is another treatment option. This technique was originally used in revision hip arthroplasty (Gie et al. 1993, Slooff et al. 1993, Toms et al. 2004, Schreurs et al. 2009). It has later been modified for use in revision knee arthroplasty. A number of authors have reported successful outcome with this technique in revision knee arthroplasty (Bradley 2000, Benjamin et al. 2001, Lonner et al. 2002, Lotke et al. 2006). However, these studies had a small number of patients and had limited follow-up times of 3 to 7 years. We have reported encouraging 2- to 9-year outcome in 30 patients revised with IBG (Steens et al. 2008).

We now report the 6- to 13-year results in 29 of these 30 patients who underwent revision arthroplasty of the knee between 1996 and 2006.

Patients and methods

Between 1996 and 2006, we performed 920 revisions of rotational or hinged knee arthroplasties (LINK Endo-Model) at our institution. In about 240 of these cases, extensive bone loss was noticed during revision. The majority of reconstructions were performed with various techniques such as bone

Patients enrolled, implants revised, radiological findings at follow-up. In the revised cases time to follow-up equals time to failure

Case no	Number of previous operations	Revised implant ^a	Localization of IBG	Device implanted during IBG ^a	Radiologic finding at follow-up ^b	Follow-up years	Failure mode
1	2	Rotational	Femur	Rotational	–	6	Loosening both
2	3	Hinge	Femur	Rotational	–	8	Loosening femur
3	3	Hinge	Femur	Hinge	–	1	Loosening both
4	2	Rotational	Femur	Hinge	–	5	Loosening both
5	–	Rotational	Tibia	Hinge	–	6	Loosening both
6	2	Hinge	Tibia	Hinge	–	1	PJI
7	3	Hinge	Tibia	Hinge	–	1	Loosening tibia
8	3	Hinge	Tibia	Hinge	–	7	Loosening both
9	3	Hinge	Tibia	Hinge	–	1	PJI
10	2	Hinge	Femur + Tibia	Rotational	–	3	Loosening both
11	3	Hinge	Femur + Tibia	Hinge	–	1	Loosening both
12	4	Hinge	Femur + Tibia	Hinge	–	1	Loosening both
13	3	Hinge	Femur + Tibia	Hinge	–	12	Loosening both
14	3	Hinge	Femur + Tibia	Hinge	–	3	Loosening femur
15	2	Rotational	Femur	Rotational	Evident incorporation	9	–
16	2	Rotational	Femur	Rotational	Unclear incorporation	11	–
17	2	Rotational	Femur	Rotational	Evident incorporation	9	–
18	2	Rotational	Tibia	Rotational	Unclear incorporation	9	–
19	2	Hinge	Tibia	Hinge	Evident incorporation	7	–
20	2	Hinge	Tibia	Hinge	Evident incorporation	9	–
21	3	Hinge	Tibia	Hinge	Evident incorporation	13	–
22	3	Hinge	Tibia	Hinge	Evident incorporation	12	–
23	3	Hinge	Tibia	Hinge	Evident incorporation	12	–
24	3	Hinge	Femur + Tibia	Hinge	Evident incorporation	12	–
25	2	Hinge	Femur + Tibia	Rotational	Evident incorporation	11	–
26	–	Hinge	Femur + Tibia	Rotational	Evident incorporation	10	–
27	–	Rotational	Femur + Tibia	Rotational	Unclear incorporation	8	–
28	3	Rotational	Femur + Tibia	Rotational	Evident incorporation	6	–
29	3	Rotational	Femur + Tibia	Hinge	Evident incorporation	12	–

^a All Endo-Model prostheses

^b According to de Waal Malefijt et al. (1995)

cement alone or combined with structural allografts, metal meshes, hydroxyapatite (HAp), or an allograft-bone/hydroxyapatite mixture. This study dealt with the subset of 29 knees in 29 patients (11 total, 18 partial revisions) in which IBG alone was used to reconstruct major bone defects. The average age of the patients was 64 (43–81 years) at the index operation. A rotational knee was revised in 10 patients and a hinged knee prosthesis in the remaining 19 patients (LINK Endo-Model). In 25 patients, at least 2 major revisions had been performed before the index revision (Table). The indication for the primary knee arthroplasty was idiopathic osteoarthritis (OA) in 25 patients, posttraumatic osteoarthritis in 2 patients, and rheumatoid arthritis (RA) in 2.

All knees were revised for aseptic loosening of the components. In all cases, a periprosthetic joint infection was excluded by preoperative aspiration and culture of synovial fluid.

The ENDO classification was used to quantify the grade of the bone defect with regard to the type of knee prosthesis (Heinert and Engelbrecht 1988). 6 knees had type-1 defects, 10 type-2, and 1 type-3 defects in the femur; 8 knees had type-1 defects and 15 had type-2 defects in the tibia. We also classified defects according to the Anderson Orthopaedic Research

Institute (AORI) classification system (Engh et al. 1999). The defects would correspond to 35 type-2 defects and 4 type-3 defects (2 femur; 2 tibia).

Surgical technique

In all patients, a single shot of antibiotic with a cephalosporin was given preoperatively. All revisions were performed through a midvastus or subvastus approach. A complete synovectomy and removal of all granulation tissue was performed. The loosened components were removed along with all cement. The defects and the sclerotic base were curetted and reamed. Impaction bone grafting (IBG) was performed according to the method developed by Ullmark und Hovelius (1996), as described previously (Steens et al. 2008). We used femoral head allografts (mean 2 in each patient) from our bone bank in all cases. The allografts were all heat-treated by thermoinfection with the sd-2 lobator system (Telos GmbH, Marburg, Germany). After thermoinfection, the allografts were stored at –80°C until transplantation. The allograft reconstructions were placed on the femoral side in 6 cases, on the tibial side in 12 cases, and on both sides in 11 cases. No metal meshes or structural allografts were used. The revision

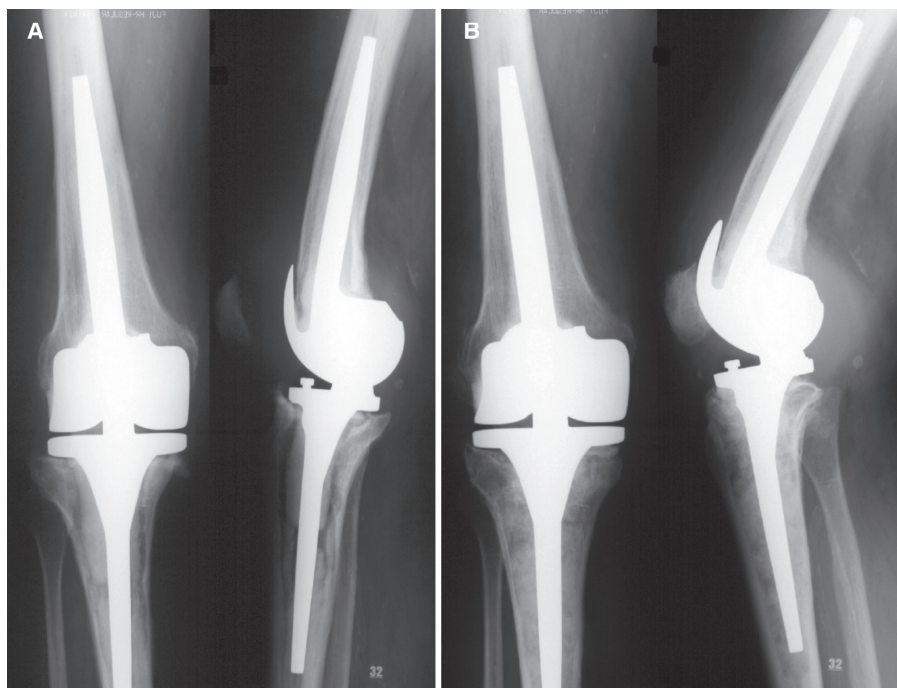


Figure 1. Patient no. 17. Clear radiographic graft incorporation at 9 years following exchange of the tibial component and IBG. A. Preoperatively. B. At follow-up.

implants were cemented with refobacin bone cement (Biomet, Germany). In 18 cases, a hinged prosthesis was implanted and in 11 cases a rotational prosthesis was implanted (LINK Endo-Model). Postoperatively, weight bearing was limited to 20 kg for 10 weeks. Thromboprophylaxis was by use of low-molecular-weight heparin.

Outcome measures

The clinical follow-up in the 15 patients with a reconstruction that survived was accomplished by standardized radiographs and by clinical examination using the Knee Society score (KSS) and WOMAC score (Bellamy et al. 1988). 4 patients had their follow-up evaluation by telephone interview, as they could not appear in person. The knees were rated as excellent (85–100 points), good (70–84 points), fair (60–69 points), and poor (0–60 points).

Pain, stiffness, and physical function are the 3 subscales of the WOMAC score. Using a visual analog scale (VAS) ranging from 0 to 10 for each item, the responses for 24 items were analyzed. A minimum of 0 points and a maximum of 240 points can be achieved. The WOMAC total score was determined by summing the subscales and the total number of points. In addition, WOMAC score was calculated according to the formula: WOMAC score = sum of points for items \times 100/240.

Standing anteroposterior (AP) and lateral views of the affected knee were performed (Figure 1). Bone graft incorporation was evaluated according to the criteria established by de Waal Malefijt et al. (1995).

Statistics

Data are given as mean (SD). The Kaplan-Meier method was used to estimate implant survivorship with 95% confidence interval (CI) using removal or revision of the implant as the end-point. Statistical analyses were carried out using IBM SPSS Statistics 19.

Results

Failed impaction bone grafting cases

At the latest follow-up, 14 knees with 19 reconstructions had failed (Figure 2). 12 of these 14 knees had been treated with re-revision surgery after a mean time of 5 (1–12) years after the index operation, due to mechanical failure and aseptic loosening of the components. A deep infection with *Staphylococcus aureus* led to revision surgery in 2 cases after 1 month. In all failed cases, the surgeon found a lack of incorporation with bone graft resorption in the femur or tibia during the re-revision procedure. In 4 of the failed cases, the patients had had 2 previous revision arthroplasties after the primary implantation. We did not find any correlation between defect type or implant type and survival rate of the reconstructions.

At the latest follow-up, 14 knees with 19 reconstructions had failed (Figure 2). 12 of these 14 knees had been treated with re-revision surgery after a mean time of 5 (1–12) years after the index operation, due to mechanical failure and aseptic loosening of the components. A deep infection with *Staphylococcus aureus* led to revision surgery in 2 cases after 1 month. In all failed cases, the surgeon found a lack of incorporation with bone graft resorption in the femur or tibia during the re-revision procedure. In 4 of the failed cases, the patients had had 2 previous revision arthroplasties after the primary implantation. We did not find any correlation between defect type or implant type and survival rate of the reconstructions.

Impaction bone grafting cases that survived

In all 15 survived knees with 21 reconstructions (6 total, 9 partial revisions), the knee score had increased from 57 (32–79) points preoperatively to 86 (53–99) points at the follow-up. The function score had increased from 49 (15–80 points) preoperatively to 81 (30–100) points at the follow-up. The mean improvement in the combined KSS score (knee score + function score) was 60 points ($p < 0.001$). 2 knees were preoperatively rated good, 3 knees were rated fair, and 10 knees were rated poor. At the latest follow-up evaluation, 10 knees were rated excellent, 3 knees were rated good, and 2 knees were rated poor. Interestingly, the 2 patients that were rated as poor at the follow-up had an improvement of 20 points in each category. The WOMAC score improved from a preoperative average score of 70 (26–98) to 38 (10–91) at the latest follow-up examination ($p < 0.001$).

3 of the unrevised knees had unclear radiographic graft incorporation with a vague border of the graft without signs of loosening, while the clinical evaluation with KSS and WOMAC score showed an improvement. The remaining 12 knees showed clear incorporation with no visible radiolucent lines around the component and no signs of significant graft resorption (Figure 3).

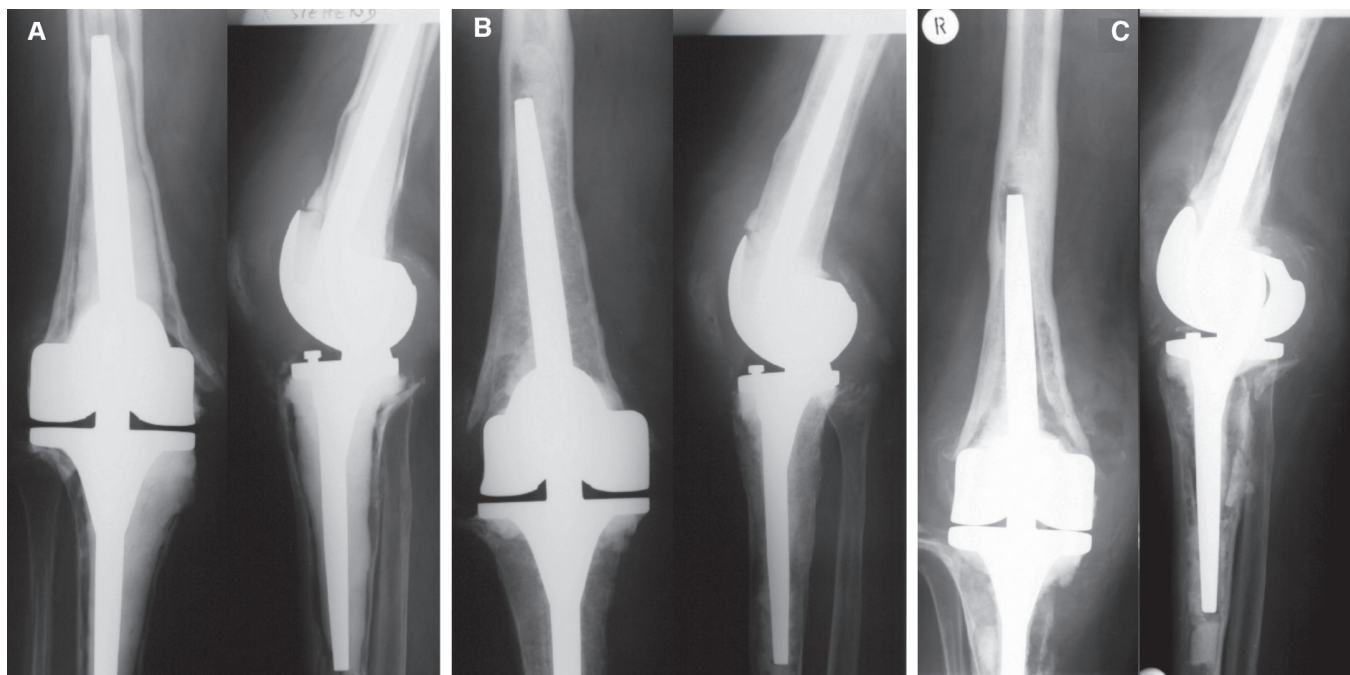


Figure 2. Patient no. 12. Aseptic loosening of a hinged knee 1 year after revision arthroplasty with IBG of both components. A. Preoperatively. B. Postoperatively. C. Loosening at 1 year.

Cumulative implant survival

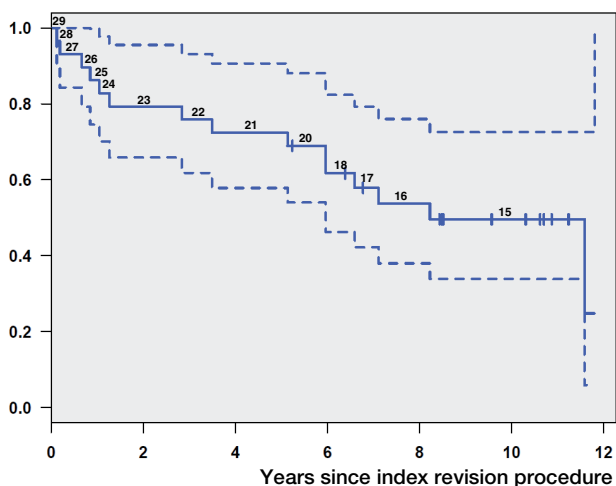


Figure 3. Kaplan-Meier survivorship with 95% CI. The endpoint used was any part of the prosthesis removed or revised for any reason. For each time point, the number of knees that survived is given.

Discussion

This is the first study to evaluate the 10-year outcome following IBG in revision TKA. We found a survival rate of only 50%, which is low compared to that in the available literature (Lotke et al. 2006, Steens et al. 2008). A previous study from our institution on these patients found a 5-year prosthesis survival of 76% (Steens et al. 2008). Lotke et al. (2006) found

no mechanical failures in 48 cemented revision TKAs with IBG after an average of 4 years. In addition, all their cases showed incorporation and remodeling of the bone graft. We only found a clear radiographic incorporation of the bone graft in four-fifths of our cases, which was lower than in the studies by Steens et al. (2008) and Lotke et al. (2006). However, these studies had shorter follow-up times. The infection rate in our study was 3/29, which is comparable to that in previously reported studies using other techniques in revision TKA, with reported infection rates ranging from 5% to 16% (Stockley et al. 1992, Jämsen et al. 2009).

The high failure rate in the present study, especially regarding aseptic loosening, may be related to the extent of bone loss caused by the previous revisions. There is certainly a need for a technique that achieves an adequate initial metaphyseal and diaphyseal stability followed by graft incorporation.

VH and MC performed the follow-up examinations. EV helped with statistics. CH, and TG assisted with the preparation of figures and tables. KD and MA proofread the manuscript. MG wrote the manuscript.

No competing interests declared.

Backstein D, Safir O, Gross A. Management of bone loss: structural grafts in revision total knee arthroplasty. *Clin Orthop* 2006; (446): 104-12.

- Bellamy N, Buchanan W W, Goldsmith C H, Campbell J, Stitt L W. Validation study of WOMAC: a health status instrument for measuring clinically important patient relevant outcomes to antirheumatic drug therapy in patients with osteoarthritis of the hip or knee. *J Rheumatol* 1988; 15 (12): 1833-40.
- Benjamin J, Engh G, Parsley B, Donaldson T, Coon T. Morselized bone grafting of defects in revision total knee arthroplasty. *Clin Orthop* 2001; (392): 62-7.
- Bradley G W. Revision total knee arthroplasty by impaction bone grafting. *Clin Orthop* 2000; (371): 113-8.
- de Waal Malefijt M, Relat Res C, van Kampen A, Slooff T, Relat Res J. Bone grafting in cemented knee replacement. 45 primary and secondary cases followed for 2-5 years. *Acta Orthop Scand* 1995; 66 (4): 325-8.
- Engh G A, Ammeen D J. Bone loss with revision total knee arthroplasty: defect classification and alternatives for reconstruction. *Instr Course Lect* 1999; 48: 167-75.
- Engh G A, Ammeen D J. Use of structural allograft in revision total knee arthroplasty in knees with severe tibial bone loss. *J Bone Joint Surg (Am)* 2007; 89 (12): 2640-7.
- Gie G A, Linder L, Ling R S, Simon J P, Slooff T J, Timperley A J. Impacted cancellous allografts and cement for revision total hip arthroplasty. *J Bone Joint Surg (Br)* 1993; 75 (1): 14-21.
- Heinert K, Engelbrecht E. Long-term comparison of the "St. Georg" knee endoprosthesis system. 10-year survival rates of 2,236 gliding and hingeendoprosthesis. *Chirurg* 1988; 59 (11): 755-62.
- Jämsen E, Huotari K, Huhtala H, Nevalainen J, Konttinen Y T. Low rate of infected knee replacement in a nationwide series-is it an understatement? *Acta Orthop* 2009; 80 (2): 205-12.
- Lonner J H, Lotke P A, Kim J, Nelson C. Impaction grafting and wire mesh for uncontained defects in revision knee arthroplasty. *Clin Orthop* 2002; (404): 145-51.
- Lotke P A, Carolan G F, Puri N. Impaction grafting for bone defects in revision total knee arthroplasty. *Clin Orthop* 2006; (446): 99-103.
- Radnay C S, Scuderi G R. Management of bone loss: augments, cones, offset stems. *Clin Orthop* 2006; (446): 83-92.
- Schreurs B W, Luttjeboer J, Thien T M, de Waal Malefijt M C, Buma P, Veth R P, Slooff T J. Acetabular revision with impacted morselized cancellous bone graft and a cemented cup in patients with rheumatoid arthritis. A concise follow-up, at eight to nineteen years, of a previous report. *J Bone Joint Surg (Am)* 2009; 91 (3): 646-51.
- Slooff T J, Schimmel J W, Buma P. Cemented fixation with bone grafts. *Orthop Clin North Am* 1993; 24 (4): 667-77.
- Steens W, Loehr J F, Wodtke J, Katzer A. Morselized bone grafting in revision arthroplasty of the knee: a retrospective analysis of 34 reconstructions after 2-9 years. *Acta Orthop* 2008; 79 (5): 683-8.
- Stockley I, Mc Auley J P, Gross A E. Allograft reconstruction in total knee arthroplasty. *J Bone Joint Surg (Br)* 1992; 74: 393-7.
- Toms A D, Barker R L, Jones R S, Kuiper J H. Impaction bone-grafting in revision joint replacement surgery. *J Bone Joint Surg (Am)* 2004; 86 (9): 2050-60.
- Ullmark G, Hovelius L. Impacted morselized allograft and cement for revision total knee arthroplasty: A primary report of 3 cases. *Acta Orthop Scand* 1996; 67 (1): 10-2.