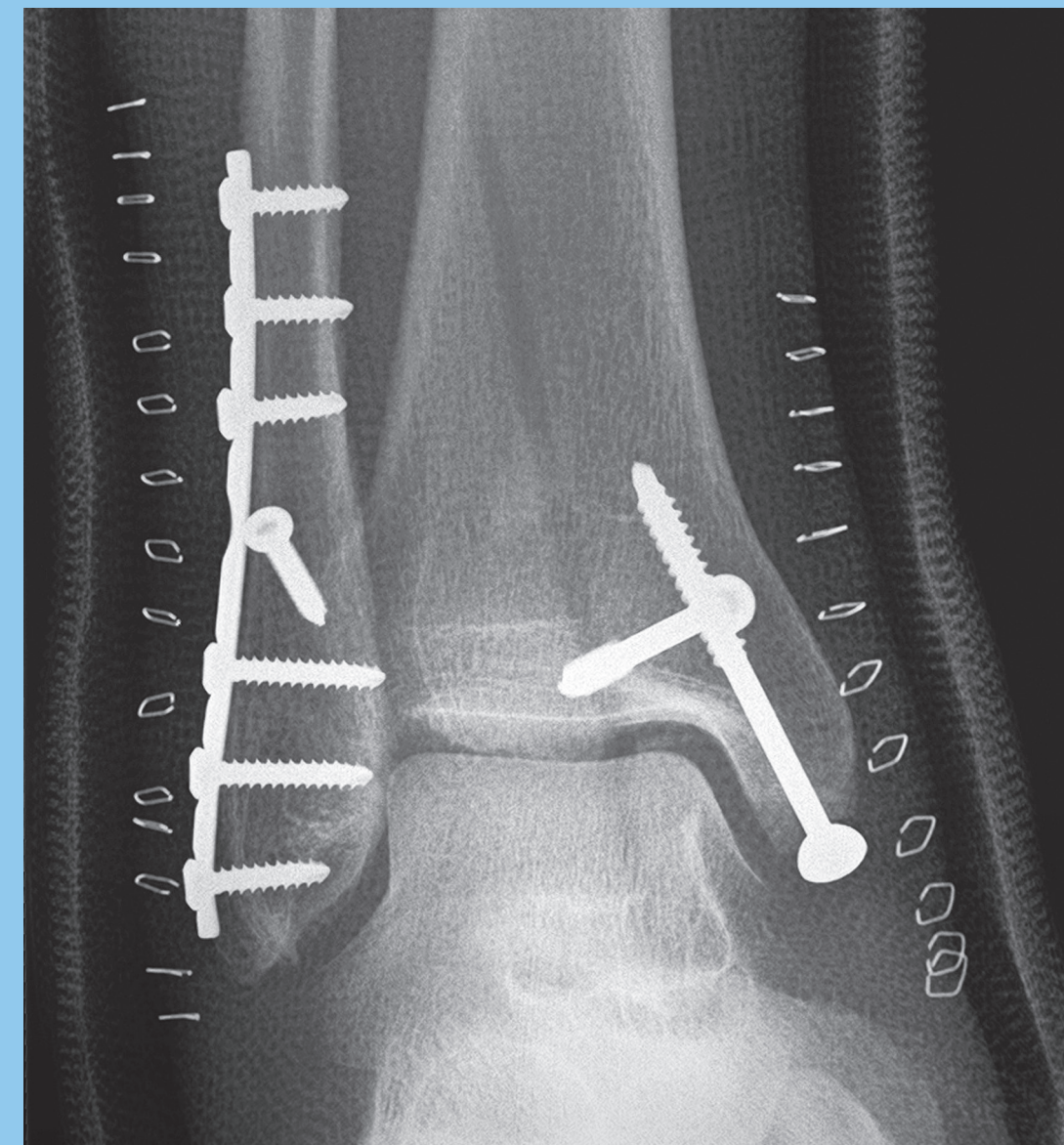


# *Acta Orthopaedica*

## **Complications in ankle fracture surgery**

**Mikko Ovaska**



From the Department of Orthopaedic Surgery and Traumatology,  
Helsinki Bone and Joint Research Group  
Helsinki University Central Hospital  
University of Helsinki,  
Helsinki, Finland

# **Complications in ankle fracture surgery**

**Mikko Ovaska**

**Doctoral Thesis**

ACTA ORTHOPAEDICA SUPPLEMENTUM NO. 358, VOL. 86, 2015

---

**informa**  
healthcare

## Contact address

---

Mikko Ovaska, MD, PhD  
Department of Orthopaedic Surgery and Traumatology  
Helsinki University Central Hospital  
00260 Helsinki, Finland  
E-mail: mikko.ovaska@hus.fi

### *Supervised by*

Tatu Mäkinen, Adjunct Professor, FEBOT  
Division of Orthopaedic Surgery  
Mount Sinai Hospital and University of Toronto  
Toronto, Ontario, Canada

Rami Madanat, MD, PhD, FEBOT  
Harris Orthopaedic Laboratory  
Department of Orthopaedic Surgery  
Massachusetts General Hospital and Harvard Medical School  
Boston, Massachusetts, USA

### *Reviewed by*

Jukka Ristiniemi, Adjunct Professor  
Department of Orthopaedic Surgery and Traumatology  
Oulu University Hospital  
Oulu, Finland

Jari Salo, Professor  
Department of Orthopaedics, Traumatology and Hand Surgery  
Kuopio University Hospital  
Kuopio, Finland

### *Opponent*

Heikki Kröger, Professor  
Department of Orthopaedics, Traumatology and Hand Surgery  
Kuopio University Hospital  
Kuopio, Finland

This Supplementum is based on a Doctoral Thesis, which was defended in October 2014.

Copyright © Informa Healthcare Ltd 2015. ISSN 1745–3674. Printed in England – all rights reserved  
DOI 10.3109/17453674.2014.1002273

Printed in England by Henry Ling  
2015

# Contents

ACKNOWLEDGEMENTS, 2	
LIST OF ORIGINAL PUBLICATIONS, 2	
ABBREVIATIONS, 2	
INTRODUCTION, 3	
REVIEW OF THE LITERATURE, 4	
Epidemiology of ankle fractures, 4	
Operative treatment of ankle fractures, 4	
<i>Classification of ankle fractures, 4</i>	
<i>Fixation methods, 4</i>	
<i>Locked plating systems, 4</i>	
<i>Syndesmosis, 5</i>	
<i>Posterior malleolus, 5</i>	
<i>Vertical fracture of the medial malleolus, 5</i>	
<i>Postoperative immobilization and weight bearing, 6</i>	
<i>Outcome of ankle fracture surgery, 6</i>	
Complications in ankle fracture surgery, 6	
<i>Wound complications and surgical site infection (SSI), 6</i>	
<i>Malreduction, loss of reduction, and post-traumatic osteoarthritis, 7</i>	
<i>Other complications, 8</i>	
<i>Patients at higher risk for postoperative complications, 9</i>	
Hardware related infection, 9	
<i>General principles, 10</i>	
<i>Exposed hardware and biofilm, 10</i>	
<i>Removal or retention of infected hardware? 10</i>	
Salvage of exposed hardware, 10	
<i>Flap reconstruction for soft-tissue defects in the ankle, 10</i>	
<i>Timing of flap coverage, 11</i>	
<i>Negative pressure wound therapy (NPWT), 11</i>	
<i>Flap coverage in the salvage of infected hardware, 11</i>	
AIMS OF THE STUDY, 12	
PATIENTS AND METHODS, 13	
Identification of the study population, 13	
Treatment protocol during the study period, 13	
Identification of deep postoperative infection, 13	
Indications for surgical debridement following deep infection, 13	
Study design, 13	
Radiological evaluation, 13	
Definition of treatment failure and flap-related complication, 13	
Outcome measurements, 13	
Statistical analyses, 14	
RESULTS, 17	
Incidence of early reoperation following ankle fracture surgery, 17	
Indications for early reoperation, 17	
Results of early reoperation, 18	
Incidence of deep SSI following ankle fracture operations, 18	
Most common causative pathogens, 18	
Risk factors for deep SSI, 18	
Flap reconstruction for hardware exposure following deep ankle infection, 18	
The outcome of patients with flap reconstruction, 19	
Incidence of treatment failure following deep SSI, 20	
Risk factors for treatment failure following deep SSI, 20	
DISCUSSION, 21	
The most important complications, 21	
Recognition of “red flags”, 22	
Ankle fracture surgery – where do we go wrong? 22	
Soft-tissue reconstruction for infected ankle fractures, 23	
Hardware removal, 23	
The outcome of patients with an infected ankle fracture, 23	
Multidisciplinary musculoskeletal infection team, 24	
Limitations and strengths of the study, 24	
Future aspects, 24	
CONCLUSIONS, 26	
REFERENCES, 27	

## Acknowledgements

This work was financially supported by The Research Foundation for Orthopaedics and Traumatology in Finland, The Emil Aaltonen Foundation, The Orion-Farmos Research Foundation, The Duodecim Foundation, and Helsinki University Central Hospital (EVO-grant).

## Abbreviations

<b>95% CI</b>	95% confidence interval
<b>ASA</b>	American society of anaesthesiology score
<b>ATFL</b>	anterior tibiofibular ligament
<b>BMI</b>	body mass index (kg/m <sup>2</sup> )
<b>CI</b>	confidence interval
<b>C-RP</b>	C-reactive protein
<b>CT</b>	computed tomography
<b>HRQoL</b>	health related quality of life
<b>ICD</b>	international classification of diseases
<b>KL</b>	Kellgren-Lawrence
<b>MCS</b>	medial clear space
<b>NPWT</b>	negative pressure wound therapy
<b>NRS</b>	numeric rating scale
<b>OMA</b>	Olerud Molander ankle score
<b>OA</b>	osteoarthritis
<b>OR</b>	odds ratio
<b>ORIF</b>	open reduction and internal fixation
<b>PTFL</b>	posterior tibiofibular ligament
<b>SPN</b>	superficial peroneal nerve
<b>SSI</b>	surgical site infection
<b>TFCS</b>	tibiofibular clear space
<b>TFO</b>	tibiofibular overlap

## List of original publications

This thesis is based on the following original publications, which are referred to in the text by their respective Roman numerals I–IV.

- I Ovaska M T, Mäkinen T J, Madanat R, Huotari K, Vahlberg T, Hirvensalo E, Lindahl J. Risk factors for deep surgical site infection following operative treatment of ankle fractures. *J Bone Joint Surg Am* 2013; 95: 348-53.
- II Ovaska M T, Mäkinen T J, Madanat R, Vahlberg T, Hirvensalo E, Lindahl J. Predictors of poor outcomes following deep infection after internal fixation of ankle fractures. *Injury* 2013; 44: 1002-6.
- III Ovaska MT, Mäkinen TJ, Madanat R, Kiljunen V, Lindahl J. A comprehensive analysis of patients with malreduced ankle fractures undergoing re-operation. *Int Orthop* 2014; 38: 83-8.
- IV Ovaska MT, Madanat R, Tukiainen E, Pulliainen L, Sintonen H, Mäkinen TJ. Flap reconstruction for soft-tissue defects with exposed hardware following deep infection after internal fixation of ankle fractures. *Injury* 2014; Accepted for publication.

## Introduction

Ankle fractures, varying in severity from stable lateral malleolus fractures to open fracture dislocations with comminution, are among the most common fractures requiring surgical treatment. It was recently shown, that the incidence of more complex fracture patterns is increasing (Thur et al. 2012). The overall aim of surgical treatment of an ankle fracture is to restore the anatomical congruity of the ankle mortise. However, for many reasons, anatomic fracture reduction may not be achieved (Horisberber et al. 2009, Luebbecke et al. 2012). Failure to reproduce the anatomic relationship of the distal tibia and fibula leads to altered loading of the tibiotalar joint (Ramsay and Hamilton 1976, Thordarson et al. 1997, Harris and Fallat 2004, Lloyd et al. 2006) and subsequent post-traumatic arthritis (Lindsjö 1981, Pettrone et al. 1983, Leeds et al. 1984, Lindsjö 1985, Beris et al. 1997, Rukavina 1998) with poor functional outcomes (Joy et al. 1974, Pettrone et al. 1983, Mont et al. 1992, Weening et al. 2005, Wikerøy et al. 2009, Sagi et al. 2012).

Surgical site infection (SSI) is one of the most common complications following ankle fracture surgery (Shephers et al. 2011). These infections are associated with significant morbidity (Sooahoo et al. 2009), and often lead to increased resource utilization (Whitehouse et al. 2002, de Lissovoy et al. 2009). The management of an infected ankle fracture with

exposed hardware is one of the great challenges faced by the orthopaedic surgeon, and identification of risk factors for SSI is crucial for developing strategies to prevent potentially disastrous complications.

The primary goals of successful treatment of an infected ankle fracture are anatomic fracture consolidation, a healed soft tissue envelope, and prevention of a chronic infection (Trampuz and Zimmerli 2006). Traditionally, fracture management has included debridement of all necrotic tissue and removal of the infected hardware (Thordasson et al. 2000, Ng and Barnes 2009). However, removal of the infected hardware prior to fracture union may result in permanent disability (Calvert et al. 2006). Recently, the strategy of wound closure without hardware removal using techniques of soft-tissue reconstruction has been emphasized (Calvert et al. 2006, Cavadas and Landin 2007, Cyrochristos et al. 2009, Viol et al. 2009, Tan et al. 2010, Vaienti et al. 2012a, Vaienti et al. 2012b).

This doctoral thesis was initiated to investigate complications following ankle fracture surgery. The first two studies focused on deep postoperative infection, the third study targeted the reasons for early reoperation following ankle fracture surgery, and the fourth study investigated the outcome of patients requiring flap reconstruction for hardware exposure following deep ankle fracture infection.

## Review of the literature

### Epidemiology of ankle fractures

Ankle fractures represent approximately 10% of all fractures and are among the most frequently encountered surgically treated fractures (Schepers et al. 2013, Somersalo et al. 2014). The incidence of a rotational ankle fracture is 71–187/100000/ year (Jensen et al. 1998, Pakarinen et al. 2011a, Thur et al. 2012), and the most common mechanism of injury is a same level fall (Jensen et al. 1998, Thur et al. 2012). The mean age of patients obtaining an ankle fracture is 45 years for men and 58 years for women (Thur et al. 2012).

As the population continues to age, the number of elderly patients sustaining rotational ankle fractures continues to rise (Kannus et al. 2002, Kannus et al. 2008, Olsen et al. 2013). Recent studies have shown an increase in more complicated bi- and trimalleolar ankle fractures in women over 60 years of age (Thur et al. 2012). As the incidence of ankle fractures in elderly people with comorbidities is rapidly increasing, a cumulative rise in the number of complications related to ankle fracture surgery may be expected.

### Operative treatment of ankle fractures

Prior to the 1960's, when it became popular, ankle fractures were operated only when repeated attempts of closed reduction failed. In the 1960's, operative treatment of ankle fractures involved only the medial malleolus. However, the results were far from satisfactory, and starting from the 1970's, the greatest emphasis was put on the anatomic reduction and rigid fixation of the lateral malleolus (DeSouza et al. 1985). Year 2014, operative treatment of ankle fractures is based on the stability of the ankle joint (Michelson et al. 2007, Gougoulis et al. 2010, Pakarinen et al. 2011a, Pakarinen 2012).

### Classification of ankle fractures

Traditionally, ankle fractures have been classified with AO-Danis-Weber (Muller et al. 1979) or Lauge-Hansen classification systems (Lauge-Hansen 1950). However, neither of these systems can really aid in decision-making whether to operate or not (Gardner et al. 2006, Haraguchi and Armiger 2009). It has been shown that stable ankle fractures can be treated conservatively with excellent results (Yde and Kristensen 1980, Ryd and Bengtsson 1992, Bauer et al. 1985, Kristensen and Hansen 1985, Bauer et al. 1987, Michelson 1995, Michelson et al. 2007, van den Bekerom et al. 2009, Pakarinen 2012), and recently a classification system based on ankle fracture stability was reported (Michelson et al. 2007). The authors

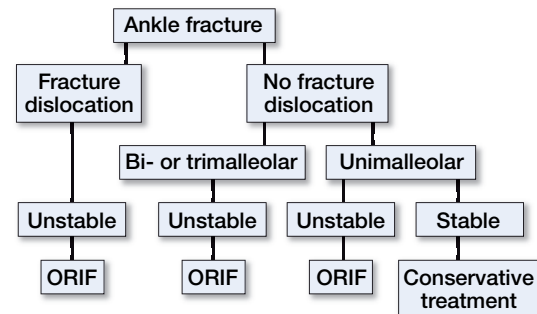


Figure 1. The treatment of ankle fractures based on stability criteria. Modified from the original picture by Michelson et al. Clinical utility of a stability-based ankle fracture classification system. *J Orthop Trauma* 2007; 21: 307-15.

noted that a stability based classification system could be prognostic as well as guide in decision-making (Michelson et al. 2007). These findings were further emphasized in a recent doctoral thesis (Pakarinen 2012). Unimalleolar fractures are usually stable, and can often be treated nonoperatively (Pakarinen et al. 2011a, Pakarinen 2012). However, bi- and trimalleolar fractures are unstable injuries, and are normally treated by operative means (Michelson et al. 2007, Pakarinen 2012) (Figure 1).

### Fixation methods

Ankle fracture dislocations need to be reduced immediately. If they cannot be reduced by closed means, early surgical intervention must be carried out (Schepers et al. 2013). Operative treatment options for an ankle fracture are open reduction and internal fixation (ORIF) or external fixation. External fixator is often used as a temporary fixation, but can exceptionally be used as a definitive treatment modality or in combination with ORIF in complicated fractures requiring additional stability. Operative treatment of ankle fractures is based on AO-principles (Ruedi et al. 2007), and the choice of fixation depends on the size of the fragments, on the comminution present, and on the stability required for a stable fixation (Hak et al. 2011). Posterior plating may sometimes provide additional stability in posterior malleolar fractures (Hak et al. 2011). Syndesmotic instability must always be evaluated intraoperatively and treated accordingly (van den Bekerom 2011).

### Locked plating systems

Locked plating systems improve fixation in osteoporotic bone, and can be useful in treating patients with poor bone quality or

in patients with complex fractures (Hak et al. 2011, Bariteau et al. 2014). In ankle fracture surgery, angular stable implants have been emphasized especially in geriatric patients (Strauss and Egol 2007, Lynde et al. 2012, Olsen et al. 2013), in obese patients (Chaudhry and Egol 2011), and in patients with diabetes (Wukich and Kline 2008). The advantages of locking plates include preservation of the periosteal blood supply, and better resistance to bending and torsional forces compared to conventional plating (Wagner 2003).

### Syndesmosis

Syndesmosis is a ligamentous complex that stabilizes the distal articulation between the fibula and tibia. The four main ligaments that contribute to the syndesmoti complex are the anterior tibiofibular ligament (ATFL), the posterior tibiofibular ligament (PTFL), the transverse ligament, and the interosseous ligament (Hermans et al. 2010). The PTFL is the strongest part of the syndesmosis, and together with the associated transverse ligament it provides 42% of the overall syndesmoti resistance strength (Ogilvie-Harris et al. 1994).

It has been shown that the level of the fibular fracture does not necessarily correlate with the presence of syndesmoti instability (Ebraheim et al. 2003, Nielson et al. 2004). Therefore, the decision to stabilize the distal tibiofibular syndesmosis should always be based on intraoperative dynamic stress testing following malleolar fracture fixation (van den Bekerom et al. 2007, van den Bekerom 2011, Pakarinen et al. 2011b). The intraoperative testing can be done with the Cotton test (lateral fibular translation test), external rotation stress test, or with sagittal plane stress test (Candal-Couto et al. 2004, Jenkinson et al. 2005, Stoffel et al. 2009, van den Bekerom 2011, Hak et al. 2011, Pakarinen et al. 2011b). The sensitivity of any of these tests alone is insufficient to adequately detect instability of the syndesmosis (Pakarinen et al. 2011b), thus a combination of various tests should probably be used (van den Bekerom 2011).

The ultimate goal of ankle fracture treatment is to maintain the normal relationship between the ankle mortise and the syndesmosis until healing has occurred (Hak et al. 2011), and anatomic reduction of the syndesmosis is critical for optimizing patient outcome (Weening et al. 2005, Wikerøy et al. 2009, Sagi et al. 2012, Van Heest and Lafferty 2014). However, recent studies with computed tomography (CT) have revealed, that the rate of syndesmoti malreduction is higher than previously thought (Gardner et al. 2006, Vasarhelyi et al. 2006, Mukhopadhyay et al. 2011, Franke et al. 2012, Davidovitch et al. 2013). There is substantial anatomic variability in the tibiofibular incisure (Elgafy et al. 2010, Mukhopadhyay et al. 2011, Lepojärvi et al. 2013), and the risk for syndesmoti malreduction is especially high in patients with flatter tibiofibular articulations (Elgafy et al. 2010). In these patients, the vector of the reduction clamp is critical for appropriately positioning the fibula within the tibiofibular incisure during syndesmoti reduction (Phisitkul et al. 2012).

Recent studies have shown, that syndesmoti transfixation may not be necessary in type B ankle fractures with intraoperatively confirmed syndesmoti disruption (Pakarinen et al. 2011c, Kortekangas et al. 2014). Since a malpositioned syndesmoti screw is an important risk factor leading to syndesmoti malreduction in the tibiofibular incisure (Vasarhelyi et al. 2006, Nimick et al. 2013), unnecessary syndesmoti screws should not be used.

### Posterior malleolus

A posterior malleolus fracture is present in 14% to 44% of patients with an ankle fracture (Hak et al. 2011). It has been shown that ankle fractures with posterior malleolus involvement have worse clinical outcomes (Hak et al. 2011, Irwin et al. 2013, Hong et al. 2014). Less than 1% of posterior malleolar fractures occur as isolated injuries, and most of them are associated with ligamentous injuries or fractures of the other malleoli (Nugent and Gale 1990, Irwin et al. 2013). Studies with CT have revealed, that fracture lines in posterior malleolar fragments are highly variable (Haraguchi et al. 2006, Yao et al. 2013), and greatly underestimated with plain radiographs (Büchler et al. 2009).

In the literature there is no consensus which fragment size should be internally fixed (van den Bekerom et al. 2009). Criteria based on fracture characteristics include fragments greater than 25% of the joint surface area, or fractures with greater than 2mm articular incongruity (Hak et al. 2011). However, larger posterolateral fragments, transverse-type fractures, and fragments that do not reduce with fibular reduction, should be reduced and fixed (Hak et al. 2011). Residual posterior subluxation of the talus after reduction of the medial and lateral malleoli is an absolute indication for posterior malleolus fixation (Miller et al. 2010).

Recent studies suggest, that regardless of the size, fixation of the posterior malleolus reduces persistent fragment displacement, increases syndesmoti stability, and improves clinical outcome (Gardner et al. 2006, Miller et al. 2010, Irwin et al. 2013). With an increased interest for posterior malleolar fixation, the use of a posterolateral surgical approach has recently been emphasized for simultaneous posterior malleolar fragment and fibular fracture fixation (Little et al. 2013).

### Vertical fracture of the medial malleolus

The vertical fracture of the medial malleolus occurs in 5% of all ankle fractures (McConnell and Tornetta III 2001). The first structure injured is either the tibiofibular ligament or the fibula. A fibular fracture appears on radiographs as a low transverse fracture line below the level of syndesmosis. However, the lateral-sided injury can be purely ligamentous. As the severity of the adduction moment increases, the talus displaces towards the medial malleolus, and a vertical fracture line is created extending from the medial axilla of the joint into the metaphyseal cortex of the tibia. Usually the medial tibial plafond will sustain an impaction injury, which is not

always recognized on plain radiographs. A failure to adequately assess the articular impaction will lead to inadequate reduction and poor outcome. Most vertical fractures of the medial malleolus require surgical fixation with buttress plating or screws inserted perpendicular to the fracture line (Hak et al. 2011).

### **Postoperative immobilization and weight bearing**

Long-term functional outcome following cast immobilization or early postoperative mobilization is similar (Lehtonen et al. 2003, Thomas et al. 2009). However, early mobilization has been associated with an increased risk for wound complications (Lehtonen et al. 2003, Vioreanu et al. 2007, Thomas et al. 2009). Based on the current literature, a patient with higher risk for postoperative infection should probably be treated with a cast following ankle fracture surgery (Thomas et al. 2009, Lin et al. 2012, Keene et al. 2014).

Studies on postoperative weight bearing are scarce, but it has been shown that patients with early weight bearing return to work earlier than patients with no weight bearing (Simanski et al. 2006, Kubiak et al. 2013, Black et al. 2014). According to biomechanical studies, axial loading stabilizes the ankle joint and prevents translational talar movement as well as external talar rotation (Sasse et al. 1999). Therefore, early weight bearing should be encouraged following operative stabilization of ankle fractures (Starkweather et al. 2012, Kubiak et al. 2013, Black et al. 2014). However, in obese and diabetic patients a longer period of non- or partial weight bearing is recommended, as premature weight bearing is the greatest contributing factor to a loss of reduction in this patient population (Bibbo et al. 2001, Wukich and Kline 2008, Rizvi et al. 2010, Chaudhry and Egol 2011).

### **Outcome of ankle fracture surgery**

Patients have significant improvement in function from six months to one year following ankle fracture surgery (Egol et al. 2006). However, at one year many patients continue to have symptoms or functional limitations (Ponzer et al. 1999, Obremskey et al. 2002, Nilsson et al. 2007, Hong et al. 2014), and only 27% of patients with bi- or trimalleolar fractures are able to practice sporting activities at pre-injury level without difficulties (Hong et al. 2013). Older age, female sex, greater ASA class, diabetes, obesity, presence of an open fracture or fracture dislocation, a trimalleolar fracture, type C fracture, syndesmotic injury, and longer cast immobilization are predictive of worse functional recovery (De Souza et al. 1985, Ebraheim et al. 1997, Egol et al. 2006, Soohoo et al. 2009, Egol et al. 2010, Tejwani et al. 2010, Lübbecke et al. 2012, Van Schie-Van der Weert 2012, Dodson et al. 2013). The development of infectious wound complications has a direct negative effect on the overall functional outcome (Hoiness et al. 2001, Schepers et al. 2013, Korim et al. 2014).

### **Complications in ankle fracture surgery**

Surgical treatment of ankle fractures may be accompanied by several complications. The overall complication rate following ORIF of ankle fractures varies considerably in the literature ranging from 1% to 40% (Ebraheim et al. 1997, Leyes et al. 2003, Soohoo et al. 2009). A large population-based study noted that open injuries, diabetes, and peripheral vascular disease were strong risk factors predicting a complicated short-term postoperative course (Soohoo et al. 2009).

Complications in ankle fracture surgery may be classified as perioperative, early postoperative, and late postoperative (Leyes et al. 2003). The most frequently encountered problems are postoperative wound complications, of which deep infection may have the most devastating consequences (Schepers et al. 2013). Hirvensalo et al. analyzed 273 compensated patient injuries resolved in Patient Insurance Centre between 2002 and 2007 due to complications following ankle fracture treatment in Finland (Hirvensalo et al. 2009). They reported that 35% of the compensated injuries were due to a technical error during the surgical procedure. In the rest of the cases, the reason for a compensation was inadequate diagnostics in 23%, wrong treatment modality in 15%, and deep infection in 13%. The mean additional in-hospital stay was seven days, but in patients with deep infection it prolonged to an average of one month. The mean duration of sick leave was two months, but in patients with deep infection it was more than a year (Hirvensalo et al. 2009).

### **Wound complications and surgical site infection (SSI)**

Wound complications include wound edge necrosis, wound dehiscence, superficial infection, and deep infection (Schepers et al. 2013). In orthopaedic surgery, the key features to susceptibility to wound complications are the personality of the injury, patient-related aspects, and surgery-related aspects (Table I).

SSI is the most common complication following ankle fracture surgery. The incidence of SSI following operative treatment of ankle fractures varies considerably in the literature, ranging from 1.4% to 5.5% (Soohoo et al. 2009, Wukich et al. 2010, Schepers et al. 2011), and infection rates as high as 19% have been reported in diabetic patients (Jones et al. 2005). Additionally, the recurrence of a postoperative ankle fracture infection is not uncommon (Zalavras et al. 2009). Postoperative infections extend total hospital stay and may increase healthcare costs by more than 300% (Whitehouse et al. 2002, DeLissovoy et al. 2009), and the development of SSI may lead to potentially devastating consequences such as permanent disability, amputation, or even death (Soohoo et al. 2009). However, there is only limited data on risk factors for deep SSI specifically associated with operative treatment of ankle fractures.

Table I. The key features to susceptibility to wound complications in orthopaedic surgery

Risk factor	Reference
<i>Personality of the injury</i>	
Severity of the fracture	Høiness and Strømsøe 2000, Høiness et al. 2001, Dodson et al. 2013
Soft tissue violation or contamination	Carragee et al. 1991, Høiness et al. 2003, Gonzalez and Weinzweig 2005
Open fracture	Gustilo et al. 1990, Soohoo et al. 2009, Pollak et al. 2010, Miller et al. 2012
<i>Patient related aspects</i>	
Age	Koval 2007, Soohoo et al. 2009, Lynde et al. 2012
Diabetes	Jones et al. 2005, Costigan et al. 2007, Chaudhary et al. 2008,
Obesity	Chaudhary and Egol 2011
Peripheral vascular disease	Soohoo et al. 2009
Peripheral neuropathy	Miller et al. 2012, Dodson et al. 2013
Malnutrition	Moucha et al. 2011
Alcohol abuse	Tønnesen et al. 1991, Høiness et al. 2003
Smoking	Nåsell et al. 2011
Non-compliance	Miller et al. 2012
<i>Surgery related aspects</i>	
Number of previous operations	Bachoura et al. 2011, Kessler et al. 2012
Suboptimal control of glucose level	Flecher et al. 2007, Richards et al. 2012
Timing of surgery	Miller et al. 2012, Schepers et al. 2013
Improper timing of antibiotic prophylaxis	Jaeger et al. 2006, Olsen et al. 2008
Type of implant used	Richards 2006, Schepers et al. 2011
Use of a drain	Bachoura et al. 2011
Use of non-occlusive dressings	Bosco III et al. 2010
Postoperative immobilization	Lehtonen et al. 2003, Thomas et al. 2009

### Definition of SSI

The literature has been inconsistent in defining postoperative infection. Some authors defined postoperative infection as the presence of purulent fluid (Lesavoy et al. 1989), while others required positive wound cultures for the diagnosis (Hochberg et al. 1998). One study gave a more strict definition of deep infection, requiring clinical signs of infection with positive bacterial cultures together with intraoperative findings of infection spreading into the hardware (Johnson et al. 1986). Around the ankle, there is no real fascia on top of the deeper structures, thus the traditional classification into superficial, deep, or organ specific infections is not suitable. Consequently, SSIs following ankle fracture operations should be classified into superficial or deep infections (Schepers et al. 2011). Superficial infections are minor complications treatable with local wound care and oral antibiotics. On the contrary, deep infections are major complications invading deeper structures and hardware (Viol et al. 2009).

### Diagnosis of SSI

The classical signs and symptoms of an infection are increasing pain, swelling, redness, and bad smelling pus in the wound. A sudden elevation of C-reactive protein (C-RP) value can lead to suspect postoperative infection. Bacterial cultures must always be obtained, and the cultures have to be positive to set the diagnosis of an infection. In orthopaedic surgery, the most common causative bacteria for postoperative infection are *Staphylococcus aureus* and *Staphylococcus epidermidis* (Schoifet and Morrey 1990, Calvert et al. 2006, Cyrochristos et al. 2009, Zalavras et al. 2009).

### Malreduction, loss of reduction and post-traumatic osteoarthritis

The overall aim of surgical treatment of ankle fractures is to restore the anatomical congruity of the ankle mortise. Failure to reproduce the anatomic relationship of the distal tibia and fibula leads to altered loading of the tibiotalar joint (Ramsay and Hamilton 1976, Thordarson et al. 1997, Harris and Fallat 2004, Lloyd et al. 2006, Thordarsson 2012) with subsequent post-traumatic arthritis (Lindsjö 1981, Pettrone et al. 1983, Leeds et al. 1984, Lindsjö 1985, Beris et al. 1997, Rukavina 1998, Thordarsson 2012) and poor functional outcomes (Joy et al. 1974, Pettrone et al. 1983, Mont et al. 1992, Kennedy et al. 2000, Weening et al. 2005, Wikerøy et al. 2009, Sagi et al. 2012). The more structures showing residual displacement, the poorer the outcome (Pettrone et al. 1983).

### Postoperative malreduction

For many reasons, anatomic reduction may not be achieved. Fracture comminution, poor bone quality, and technical errors may predispose a patient to residual displacement following ankle fracture surgery (Horisberger et al. 2009, Lübbecke et al. 2012). Recent studies with CT scan have revealed that proper reduction of a syndesmotic injury is especially demanding (Gardner et al. 2006, Vasarhelyi et al. 2006, Miller et al. 2009, Mukhopadhyay et al. 2011, Franke et al. 2012, Sagi et al. 2012, Davidovitch et al. 2013). In a large population based study with 57,183 patients, the rate of revision ORIF following ankle fracture surgery was 0.8% within the first three postoperative months (Soohoo et al. 2009). Although there is a large body of literature about ankle fractures, no studies have

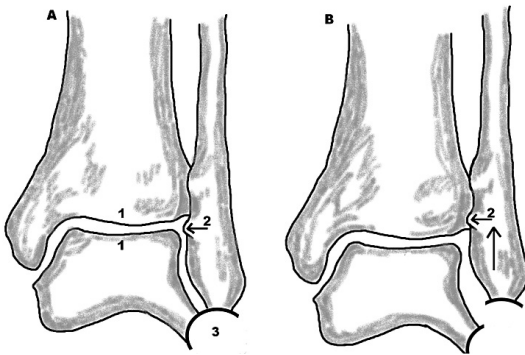


Figure 2. The criteria for normal fibular length as seen on the mortise view: 1) Equal joint space; 2) Intact Shenton line of the ankle; 3) Unbroken curve between the lateral part of the talus and the peroneal groove of the fibular. Modified from the original picture by Thordarson DB. Patients with a crooked radiograph after ankle fracture: what to do? *Foot Ankle Int* 2012; 33: 355-8.

examined the true frequency of the most common types of postoperative malreduction necessitating early reoperation.

#### *Loss of reduction and malunion*

The complexity of the fracture, unsatisfactory reduction, or loss of the achieved reduction may lead to ankle fracture malunion (Giannini et al. 2010). The alteration in articular congruency leads to chronic pain, functional impairment, deterioration of the articular cartilage, and finally post-traumatic osteoarthritis (Giannini et al. 2010). Most patients with a malunited fracture complain about pain, swelling or stiffness of the ankle joint, as well as difficulty in walking or in physical activities (van Wensen et al. 2011). Fibular shortening and fibular malrotation are the most common types of malunion following ankle fracture surgery (van Wensen et al. 2011, Thordarson 2012). Unfortunately, they are also the most difficult to reconstruct (Henderson and Lau 2006).

Plain radiographic findings on ankle fracture malunion include asymmetry of the medial and lateral clear space, talar tilt or talar shift, talar subluxation anteriorly or posteriorly, and shortening of the fibula. In fibular malunions, the radiographic diagnosis of fibular shortening can be achieved with a mortise view. The criteria for normal fibular length are shown in Figure 2.

Fibular malrotation is difficult to visualize on plain radiographs, and when rotational malalignment is suspected, a CT scan with 3D-reconstruction should be considered (van Wensen et al. 2011).

#### *Post-traumatic osteoarthritis*

Primary or idiopathic osteoarthritis (OA) is the most common joint disease. However, primary OA occurs much less frequently in the ankle (Salzman et al. 2005). Whereas primary OA is the most common indication for total hip and total knee replacement, post-traumatic OA is the most common indi-

cation for ankle arthrodesis (Salzman et al. 2005); 78% of patients with end-stage ankle OA are post-traumatic (Valderrabano et al. 2009). The severity of the initial fracture, articular cartilage damage, talocrural joint instability, and fracture malunion are the determinants of post-traumatic OA (Lindsjö 1981, DeSouza et al. 1985, Wyss and Zollinger 1991, Valderrabano et al. 2009, Soohoo et al. 2009, Stufkens et al. 2010).

Traumatic ankle injuries that may result in OA include fractures of the malleoli, tibial plafond, talus, as well as ligamentous injuries of the ankle (Valderrabano et al. 2009). However, 37% of post-traumatic ankle OA patients present with a past rotational ankle fracture (Salzman et al. 2005). A prospective study showed that the true prevalence of post-traumatic OA following malleolar ankle fractures is 14% (Lindsjö 1985), and tibiotalar varus is the predominant malalignment (Valderrabano et al. 2009).

In a large database study with 57,183 patients following ankle fracture surgery, the rate of ankle fusion or replacement for end-stage OA was 1% (Soohoo et al. 2009). Significant predictors for fusion or replacement were the presence of a trimalleolar fracture or an associated open injury. Another study reported that the most important factor predicting ankle arthrodesis is fibular malunion (Wyss and Zollinger 1991).

#### *Other complications*

##### *Nonunion*

The true incidence of nonunion following operative treatment of malleolar ankle fractures is not known. However, in conservatively treated stable lateral malleolar fractures the reported incidence of nonunion is 2% (Donken et al. 2011). Excess motion at the fracture site due to poor reduction or fixation, and loss of blood supply due to periosteal stripping contribute to the formation of nonunion. Other factors such as infection, obesity, tobacco use, diabetes, alcohol abuse, and advanced age also contribute to the development of this complication (Rodriguez-Merchan and Forriol 2004, Khurana et al. 2013). Nonunion should be considered and treated accordingly in all ankle fracture patients with persistent pain six months after the initial fracture (Walsh and DiGiovanni 2004, McGonagle et al. 2010).

##### *Neurologic complications*

Neurologic complications of ankle fracture surgery are infrequently described, but account for significant morbidity. Most commonly, neuroma due to transection of the superficial peroneal nerve (SPN) has been reported (Redfern et al. 2003, Halm and Schepers 2012). SPN is at risk during the lateral approach to the fibula, and injury to this nerve can frequently be identified as a cause of chronic ankle pain (Redfern et al. 2003). The risk of nerve injury is increased for the Blair and Botta type B pattern of the intermediate cutaneous dorsal nerve branch, crossing the distal fibula from posterior to anterior at 5 to 7cm proximal from the malleolar tip (Halm and Schepers 2012). Symptomatic injuries to SPN have been

reported in 15% of patients following lateral approach to the fibula (Redfern et al. 2003). With a posterolateral approach, the sural nerve can potentially be damaged, causing a painful neuroma or numbness along the lateral border of foot (Talbot et al. 2005, Jowett et al. 2010). Chronic pain overlying hardware in another possible complication, and 23% of patients desire hardware removal due to persistent lateral pain (Brown et al. 2001). However, many patients continue to have some degree of pain despite hardware removal (Brown et al. 2001, Kim et al. 2013).

### ***Thromboembolic complications***

Clinically detectable thromboembolic events following operative treatment of ankle fractures are uncommon, and do not appear to be influenced by the use of thromboprophylaxis (Pelet et al. 2012, Selby et al. 2014). The reported incidence of thromboembolic events in patients with ankle fracture is 3%, involving pulmonary embolism in 0.3% (Soohoo et al. 2011, Pelet et al. 2012). Patients with certain risk factors (older age, obesity, history of smoking, prolonged use of a tourniquet, non-weight bearing, immobilization, history of a previous thromboembolic event, pregnancy, hormonal replacement therapy, paralysis, neoplasia) appear to be at higher risk for thromboembolic events (Soohoo et al. 2011, Kadous et al. 2012, Pelet et al. 2012), and prophylaxis should be considered for these patients (Testroote et al. 2008, Kadous et al. 2012, Yi et al. 2014).

### ***Patients at higher risk for postoperative complications***

#### ***Diabetic patients***

A recent report projected that between 2009 and 2034, in the US the number of people with diabetes will increase from 24 to 44 million (Huang et al. 2009). The rise in prevalence has been characterized as a worldwide epidemic, particularly in the developing nations (Chan et al. 2009). Patients with diabetes have higher complication rates for both open and closed management of ankle fractures (McCormack and Leith 1998, Wukich and Kline 2008, Hak et al. 2011). Wound complication rates as high as 32% and 64% have been reported in diabetic patients following ORIF of closed (Flynn et al. 2000, Jones et al. 2005, Wukich et al. 2011) and open (Blotter et al. 1999, White et al. 2003) ankle fractures, respectively. However, there is good evidence that operative management of an unstable ankle fracture in a diabetic patient is more likely to result in a stable and functional lower extremity compared to nonoperative treatment (Bibbo et al. 2001, Wukich and Kline 2008). Conservative treatment with a cast in patients with diabetic neuropathy and impaired sensation may be disastrous (Connolly and Csencsitz 1998).

A study of 57,183 surgically treated ankle fracture patients reported, that diabetes is a strong predictor of short-term complications (Soohoo et al. 2009). Another study showed, that diabetic patients have an increased mortality rate, more post-

operative complications, longer in-hospital stay, and elevated costs compared to non-diabetic patients (Ganesh et al. 2005). Additionally, diabetic patients with neuro- or vasculopathy have a 6-fold risk of overall complications following ankle fracture surgery compared to patients with uncomplicated diabetes (Jones et al. 2005, Wukich and Kline 2008, Wukich et al. 2010, Wukich et al. 2011).

#### ***Obese patients***

Given the high prevalence of type II diabetes in obese patients, one must pay particular attention to the risks and benefits of surgery in this patient population (Chaudhry and Egol 2011). Nonoperative management may seem like an attractive option in the light of the morbidity associated with surgery, but with higher rates of loss of reduction, great difficulty in tolerating casting, and inability to comply with weight bearing restrictions, operative treatment plays a major role (Guss and Bhattacharyya 2006, Chaudhry and Egol 2011). Supplemental fixation in form of stronger locking plates, additional plates or external fixation, and longer periods of non-weight bearing can counteract the tendency towards a failure, as premature weight bearing is most likely the greatest contributing factor to the higher rates of loss of reduction (Chaudhry and Egol 2011). There is a strong association between obesity and loss of reduction after operative treatment of the syndesmotic injuries (Mendelsohn et al. 2013).

#### ***Elderly patients***

Geriatric patients provide unique challenges in fracture management due to their bone quality and medical comorbidities (Little et al. 2013). SSI is a strong predictor of mortality in elderly patients (Lee et al. 2006), and controversies remain regarding the risks and benefits of operative treatment in geriatric patients (Koval et al. 2007, Strauss and Egol 2007, Hak et al. 2011, Shivarathre et al. 2011, Lynde et al. 2012, Little et al. 2013, McKean et al. 2013, Olsen et al. 2013, Zaghoul et al. 2014). The risks of surgical treatment should be carefully evaluated in all elderly patients (Kettunen and Kröger 2005). Smoking and polypharmacy have shown to be independent risk factors for ankle fractures in elderly women (Valtola et al. 2002). Interestingly, osteoporosis is not a risk factor, nor does prior ankle fracture predict subsequent major osteoporotic fractures (Hasselman et al. 2003, Hak et al. 2011, Pritchard et al. 2012, Olsen et al. 2013). However, osteoporosis is a risk factor for loss of reduction (Kettunen and Kröger 2005, Strauss et al. 2007, McKean et al. 2013, Olsen et al. 2013), thus locking plates may be necessary in elderly patients to enhance angular stability (Kettunen and Kröger 2005, McKean et al. 2013). Taken together, in elderly patients osteopenia and osteoporosis pose a challenge to achieve stable fixation. However, if stable fixation is achieved, these patients are likely to experience results similar to those without poor bone quality (Strauss et al. 2007, Lynde et al. 2012, Little et al. 2013, Olsen et al. 2013).

## Hardware related infection

Infection is an omnipresent risk of every surgical procedure. Fractured bones have a diminished capacity to resist infection due to endosteal and periosteal blood vessel damage (Liu et al. 2012). The presence of hardware near the wound poses an additional risk for infection, because implants are avascular and not protected by the host's immune system (Calvert et al. 2006). Due to the diminished circulation of the overlying skin and subcutaneous location of the distal tibia and fibula, wound dehiscence around the ankle generally results in immediate contamination of the underlying bone and hardware (Thordarson et al. 2000).

### General principles

The treatment of a patient with infected hardware is one of the great challenges faced by the orthopaedic and reconstructive surgeon. These infections are best managed with a team approach, and standard of care mandates that a plastic, vascular, and orthopaedic trauma surgeon together with an infectious diseases specialist be an integral part of the multidisciplinary team (Thordarson et al. 2000, Naique et al. 2006, Culliford et al. 2007, Liu et al. 2012).

The management of hardware related infection is based on the type of fracture fixation, the degree of bony healing, and the physiological status as well as comorbidities of the patient (Darouiche 2004). The primary goals of successful treatment are anatomic fracture consolidation, a healed soft tissue envelope, and prevention of a chronic infection (Trampuz and Zimmerli 2006). Traditionally, the management has included debridement of all necrotic tissue, a prolonged course of intravenous antibiotics, and likely removal of all infected hardware (Thordarson et al. 2000, Calvert et al. 2006, Viol et al. 2009, Ng and Barnes 2009, Tan et al. 2010).

### Exposed hardware and biofilm

Various studies have reported a correlation between the duration of infection and the rate of successful hardware salvage (Viol et al. 2009). Gristina et al. showed that bacteria adhere to the implant, and by forming a biofilm acquire additional pathogenic potential (Gristina et al. 1991). In the biofilm the bacteria enter into a slow or stationary phase, which make the bacteria more resistant to most antimicrobial agents. Once the biofilm has established, the immune system and antibiotics cannot eradicate bacteria until the implant is removed (Darouiche 2004, Trampuz and Zimmerli 2006). Because of biofilm production, prompt treatment of early infections is preferable to treating late infections, where biofilm already exists protecting the bacteria within it (Darouiche 2004).

### Removal or retention of infected hardware?

Fractures pose a dilemma when infection occurs in the acute postoperative period as a vast majority of fractures will not have achieved osseous union at this point. Studies have shown

that removal of hardware prior to fracture union may result in loss of reduction or even permanent disability (Thordarson et al. 2000, Calvert et al. 2006, Cyrochristos et al. 2009). In these complex cases one must consider, whether the stability and fracture consolidation are optimized through hardware retention, or whether the infected hardware should be removed to give the patient the best chance to clear the infectious process (Calvert et al. 2006, Berkes et al. 2010).

There is surprisingly scant literature to help to guide the decision regarding retention or removal of infected hardware in the early postoperative period following internal fracture fixation (Trebse et al. 2005, Rightmire et al. 2008, Zalavras et al. 2009, Berkes et al. 2010). The few published studies have reported fracture consolidation rates of 70% with retention of infected hardware (Rightmire et al. 2008, Berkes et al. 2010). However, the recurrence of infection is not uncommon (Ueng and Shih 1992, Cavadas and Landin 2006, Zalavras et al. 2009).

Studies have shown that if infection is treated early, implant could probably be retained provided that the skeletal reconstruction is anatomically correct, there is no necrotic bone, and hardware continues to provide good fixation (Schoifet et al. 1990, Thordarson et al. 2000, DeFranzo et al. 2001, Cavadas and Landin 2006, Hultman et al. 2006, Viol et al. 2009). In this setting, the infection is probably not eradicated but rather controlled, yet permitting the fracture to consolidate (Zalavras et al. 2009). However, the optimal treatment of an infected ankle fracture remains a subject for debate.

## Salvage of exposed hardware

The presence of a soft-tissue defect or signs of infection at areas of exposed hardware necessitates early aggressive therapy (Viol et al. 2009). Since removal of infected hardware prior to fracture union may result in disastrous complications (Calvert et al. 2006), wound closure without hardware removal using techniques of soft-tissue reconstruction has been proposed. (Calvert et al. 2006, Cavadas and Landin 2006, Cyrochristos et al. 2009, Viol et al. 2009, Tan et al. 2010, Vaienti 2012a, Vaienti 2012b).

The presence of hardware exposure ultimately necessitates soft-tissue reconstruction, because inconsistent results have been achieved with secondary wound closure or skin grafting (Viol et al. 2009). Soft-tissue management of lower extremity wounds includes local fasciocutaneous flaps, local muscle flaps, and microvascular free flap transfers (Thordarson et al. 2000, Culliford et al. 2007, Vaienti 2012b). The location of the defect plays a role in the choice between a local or a free muscle flap (Viol et al. 2009). Free muscle flaps are especially appropriate because they provide well-vascularized tissue to the injured zone increasing the rate of salvage (Gopal et al. 2000, Pollak et al. 2000, Thordarson et al. 2000, Calvert et al. 2006, Viol et al. 2009, Zahorka 2009).

The following parameters have been identified as impor-

tant for the potential salvage of the exposed hardware with soft-tissue coverage: 1) a proper patient selection; 2) hardware location; 3) duration of exposure; 4) presence and duration of infection; and; 5) presence of hardware loosening (Gonzalez et al. 2002, Gonzalez and Weinzweig 2005, Cavadas and Landin 2007, Cyrochristos et al. 2009, Viol et al. 2009, Liu et al. 2012, Vaienti et al. 2012a).

### **Flap reconstruction for soft-tissue defects in the ankle**

Soft-tissue defects around ankle are demanding to treat due to a fragile subcutaneous vascular network, thin soft-tissue coverage, and limited elasticity of the local skin (Kneser et al. 2011, Vaienti et al. 2012a). When planning a flap reconstruction for wounds around ankle, the patient's vascular status must be carefully determined with palpation of pulses, doppler ultrasound, and sometimes even with angiography (Levin 2001). Partial-thickness wound defects can sometimes be managed with conservative measures or with skin grafting. However, when hardware exposure already exists, early aggressive soft-tissue reconstruction should be carried out.

The classic reconstructive armamentarium suggests the use of well-vascularized microvascular free flap transfers for the coverage of wounds in the distal leg (Hallock 2000, Thordason et al. 2000, Cyrochristos et al. 2009, Viol et al. 2009). However, free flap transfers are technically demanding procedures, and the actual contour of the ankle allowing normal shoe wear, is difficult to normalize with bulky free flaps (Levin 2001). Reintroduction of local fasciocutaneous and muscle flaps has added a simpler option for the coverage of defects around ankle (Hallock 2000, Culliford et al. 2007, Vaienti et al. 2012b). The decision between a local or a distal flap depends on the presence of infection, depth of the defect, vascular supply, and damage to other areas of the ankle precluding the use of local flaps.

After Masquelet's detailed description of the surgical technique on a distally based sural flap, it became the workhorse in the reconstruction of the distal lower leg (Masquelet et al. 1992, Vaienti et al. 2012b). The use of a distally based peroneus brevis flap was reported a decade later by Eren et al. (Eren et al. 2001). Elevation of the distally based peroneus flap does not require elaborate microsurgical skills (Yang et al. 2005, Bach et al. 2007, Kneser et al. 2011), and successful results for soft-tissue reconstruction of the ankle have been reported with this flap (Koski et al. 2005, Yang et al. 2005, Bach et al. 2007, Lorenzetti et al. 2010, Kneser et al. 2011). Distally based peroneus brevis flap has been recommended as a first-line procedure for small- to medium-sized defects in malleolar region, since patients managed with sural flaps have higher complication rates (Kneser et al. 2011). A distally based sural flap could be used for extended skin defects, especially when a larger arc of rotation is required (Akhtar and Hameed 2006, Rios-Luna et al. 2007, Xu and Lai-Jin 2008, Kneser et al. 2011). Recently, local propeller flaps have been introduced as another possible tool for soft-tissue reconstruction around

the ankle (Jakubietz et al. 2007, Jakubietz et al. 2012).

### **Timing of flap coverage**

In his landmark paper presented in 1986, Godina concluded that microsurgical reconstruction of lower extremity injuries should be performed within the first 72 hours after injury, since flap reconstruction undertaken after three days led to higher failure rates (Godina 1986). Thereafter, several studies have reported superior outcomes with definitive early soft-tissue coverage (Hertel et al. 1999, Gopal et al. 2000, Hallock 2000, Bhattacharyya et al. 2008, Liu et al. 2012). With hardware exposure, the most important prognostic factors for successful outcome seem to be the duration the exposure and the presence of a pre-flap infection; Presence of hardware exposure predisposes to higher rates of wound infection, and patients with negative cultures have better outcome after flap reconstruction (Viol et al. 2009, Liu et al. 2012).

### **Negative pressure wound therapy (NPWT)**

The concept of immediate fixation and early soft-tissue coverage for open fractures has been referred to as "Fix and flap" (Gopal et al. 2000), and negative pressure wound therapy (NPWT) has a major impact in this area. NPWT is a recent development in the treatment of complex wounds, which employs a subatmospheric pressure of 125mmHg in either continuous or intermittent mode (Stannard et al. 2009). NPWT acts by promoting angiogenesis to the injured tissue (Argenta et al. 2006, Mouës et al. 2011). It also reduces the extent and complexity of the wound, allowing simpler soft tissue procedures for wound closure in the "reconstructive ladder" (Kanakaris et al. 2007, Stannard et al. 2009, Stannard et al. 2010). Additionally, NPWT increases the take rate of skin grafts, and allows quicker graft incorporation, especially in patients with wound healing problems (Kanakaris et al. 2007, Stannard et al. 2010, Mouës et al. 2011). Although bacterial clearance has been advocated with NPWT (Stannard et al. 2009), this mechanism of action has not been proven in basic science (Birke-Sorensen et al. 2011, Mouës et al. 2011). Therefore, NPWT provides effective temporary wound coverage, but it does not allow delay in soft-tissue coverage without a concomitant increase in the infection rate (Bhattacharyya et al. 2008, Hou et al. 2011, Liu et al. 2012). NPWT does not work without a thorough debridement of all non-viable bone and soft-tissue, and should not be applied onto secreting infected wounds (DeFranzo et al. 2001).

### **Flap coverage in the salvage of infected hardware**

Lower extremity flap reconstruction is associated with high complication rates (Benacquista et al. 1996, Culliford et al. 2007). One of the key factors to reconstructive success with infected soft-tissue defects is the adherence to rigid criteria to define wound readiness for the coverage (Gonzalez et al. 2002). Important factors are the duration exposure, the duration of infection, and eradication of the infective pathogen (Gonzalez et al. 2002, Gonzalez and Winzweig 2005,

Cavadas and Landin 2007, Viol et al. 2009, Liu et al. 2012, Vaienti et al. 2012a). There is a strong correlation between the pre-flap bacterial cultures and the outcome (Vaienti et al. 2012a, Liu et al. 2012), and flap failure rates as high as 23% have been reported in patients with pre-flap infection (Gonzalez et al. 2002, Gonzalez and Winzweig 2005). Microvascular free flaps have been recommended for the coverage of infected hardware exposure of the distal leg, since the use of a well-vascularized tissue has shown to increase the rate of

salvage (Hallock 2000, Thordason et al. 2000, Calvert et al. 2006, Cyrochristos et al. 2009, Viol et al. 2009, Zahorka et al. 2009). Although lower extremity flap reconstruction is associated with higher complication and failure rates than those to any other part of the body, the alternative to flap reconstruction may sometimes be much worse, a primary lower-leg amputation (Benacquista et al. 1996, Culliford et al. 2007). In the literature, there are no studies specifically examining patients requiring flap reconstruction following deep postoperative ankle fracture infection.

---

## Aims of the study

The present study had the following aims:

1. To identify the most important patient- and surgery-related risk factors for deep SSI following operative treatment of ankle fractures.
2. To recognize the main factors predisposing to a treatment failure of an infected ankle fracture.
3. To determine the most common technical errors resulting in early reoperation following ankle fracture surgery.
4. To assess the outcome of patients treated with flap reconstruction following deep infection with exposed hardware after internal fixation of an ankle fracture.

## Patients and methods

### Identification of the study population

Approval from our institutional review board (I-IV) and local ethics committee (IV) was obtained prior to the beginning of the study. All patients who had undergone an ankle fracture operation at a level-I trauma center from January 2002 through December 2011 were identified by querying the hospital surgical procedure database for diagnoses coded with ICD-10 for fibular fracture (S82.4), medial malleolar fracture (S82.5), lateral malleolar fracture (S82.6), bi- or trimalleolar fracture (S82.8), and procedure codes for internal or external fixation of ankle fractures. Eligible operations were restricted to those performed primarily at our institution in patients 18 years of age or older, and all patients had to be definitively treated with open reduction and internal fixation (ORIF). We identified 5,123 consecutive ankle fracture operations in 5,071 patients. The number of treating surgeons was 151, including residents and specialists.

### Treatment protocol during the study period

A standardized operative and postoperative protocol was used at our institution during the study period. ORIF was performed based on AO-principles and a tourniquet was applied depending on personal preferences of the treating surgeon. The wound was closed in three layers (peroneal fascia, subcutaneous layer, skin). Fluoroscopic images were obtained in the operating room before wound closure. Postoperatively, a cast was applied to all patients. Radiographs (AP, mortise, and lateral view) were obtained before weight bearing was allowed. Sutures or staples were removed at two weeks, after which the patients were allowed to begin active ankle range of motion exercises. Full weight bearing was allowed at four weeks, and the cast was removed at six weeks.

### Identification of deep postoperative infection

Postoperative infections were classified as deep when all three of the following criteria were met at the same time: clinical signs of a SSI (redness, swelling, drainage, or dehiscence), positive bacterial cultures taken from the wound, and osteosynthesis material visible or palpable in the wound. Local wound irrigation was performed, and empiric antibiotic treatment was initiated in all patients. If needed, antibiotic treatment was later modified according to the antimicrobial sensitivity tests.

Table 2. Summary of the included studies

Study	Design	Cohort of patients	Included patients
I	Age- and sex-matched case-control study	1,915	131 + 131 <sup>a</sup>
II	Case-control study	1,915	97
III	Chart review	5,071	79 + 79 <sup>a</sup>
IV	Prospective cohort study	3,030	56

<sup>a</sup> age-and sex-matched control patients

### Indications for surgical debridement following deep infection

The indications for performing surgical debridement following deep infection were necrotic tissue in the wound, continuous wound drainage, sepsis, widely exposed osteosynthesis material, or wounds requiring soft-tissue coverage. Local wound care or NPWT was applied in cases where wound bed conditioning was required. In Study IV, decisions regarding the required flap or the timing of flap reconstruction were based on local conditions of the infected wound. Doppler ultrasound examination was routinely used for planning of reconstructive surgical procedures.

### Study design

The summary of the included studies is presented in Table 2.

Study I was an age-and sex-matched case-control study. For this study, we identified 1,923 consecutive ankle fracture operations in 1915 patients between January 2006 through December 2009. The number of treating surgeons was 93. The medical and microbiological records of all 1915 patients were reviewed for recorded signs and symptoms for SSI, and 131 of 1,915 patients (6.8%) fulfilled the aforementioned criteria for deep infection. For these 131 patients, an age- and sex-matched control group was randomly selected from the same cohort of patients without a subsequent SSI. Potential patient- and surgery-related risk factors for deep SSI were reviewed for all included patients. There were no differences between the groups regarding the basic fracture characteristics (Table 3).

A total number of 345 complications were observed in these 1915 patients (Unpublished data). The 131 deep infections constituted 38% of the observed complications, but other important factors were a technical error during the surgical

Table 3. Fracture characteristics of the age- and sex-matched groups (I)

Characteristic	Patients with infection (%)	Control patients (%)	p-value
High-energy injury	17 (13)	13 (10)	0.4
Fracture type			0.2
unimalleolar	25 (19)	35 (27)	
bimalleolar	45 (34)	46 (35)	
trimalleolar	61 (47)	50 (38)	
Weber-classification <sup>a</sup>			0.6
B	104 (79)	99 (79)	
C	27 (21)	27 (21)	

<sup>a</sup> 5 patients with an isolated medial malleolus fracture in the control group

Table 4. Fracture characteristics of the reoperated patients and controls (III)

Characteristic	Patients with reoperation n (%)	Control patients n (%)	p-value
Fracture dislocation	42 (53)	27 (34)	0.01
Open fracture	6 (8)	1 (1)	0.06
Fracture type			0.001
unimalleolar	12 (15)	32 (41)	
bimalleolar	22 (28)	18 (23)	
trimalleolar	45 (57)	29 (37)	
Weber-classification			0.2
A	2 (3)	2 (3)	
B	42 (55)	52 (69)	
C	32 (42)	21 (28)	
Posterior malleolar fracture	58 (73)	41 (52)	0.005
Associated medial malleolar fracture	55 (70)	35 (44)	0.001
Chaput-Tillaux fragment	4 (5)	1 (1)	0.2
Use of syndesmotic screw	41 (52)	32 (41)	0.2
Syndesmotic reduction technique			1
clamp	33/41 (80)	26/32 (81)	
direct visualization	8/41 (20)	6/32 (19)	

procedure (19%) and a loss of reduction (16%) (Unpublished data).

Study II was a retrospective case-control study including all patients from January 2006 through December 2009 with a deep postoperative ankle fracture infection requiring at least one surgical debridement in the operating theatre. Superficial infections, deep infections that could be managed with local wound care and antibiotics alone, and infections that occurred after scheduled hardware removal were excluded from the study. 97 patients constituted the study population (Figure 3). The end point of the study was the failure or success of the treatment, and potential factors for treatment failure were reviewed for all included patients. The mean follow-up time was 22 months (range 2–57 months). One patient died due to a cardiac arrest at two months shortly after a second debridement. In the remaining 96 patients, the minimum follow-up time was six months.

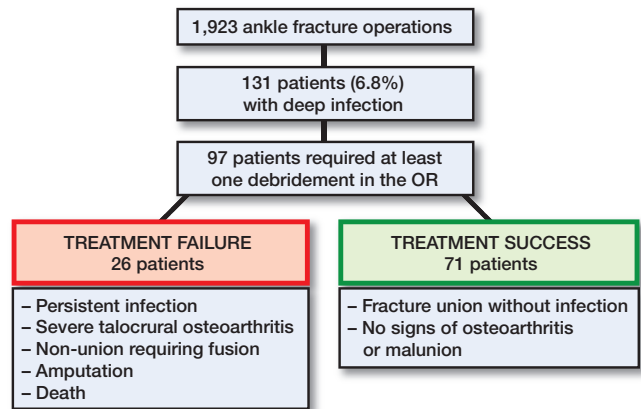


Figure 3. Flow diagram of the patients (II).

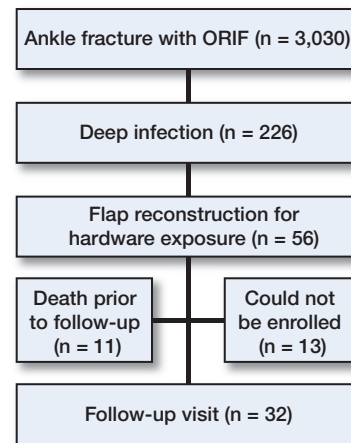


Figure 4. Flow diagram of the patients (IV).

Study III was a chart review of all ankle fractures that were surgically treated from January 2002 through December 2011. From a total of 5,123 ankle fracture operations in 5,071 patients, we identified 79 patients (1.6%) who were reoperated due to a fracture malreduction observed in postoperative radiographs. As controls, from the same cohort we randomly selected 79 age- and sex-matched patients who did not undergo reoperation (Table 4).

Study IV was a prospective cohort study including all patients from January 2006 through December 2011 with a deep postoperative ankle fracture infection requiring flap reconstruction for hardware exposure. Out of 3041 consecutive ankle fracture operations performed in 3030 patients, we identified 56 (1.8%) patients requiring flap reconstruction for infected hardware exposure (Figure 4): 32 of the 56 included patients could be examined at a follow-up visit. The mean follow-up time was 52 months (range 1–97 months). One patient died due to pneumonia one month postoperatively, and in the remaining 55 patients the minimum follow-up time was 12 months.

Medical, operative, microbiological, and radiological records were reviewed for all included patients (I–IV). The demographic data and possible co-morbidities of the patients, primary injury mechanism (low- or high-energy injury), fracture type, as well as the presence of an open fracture or fracture dislocation at the time of the injury was collected. The causative pathogens for deep infection were recorded, and infections were classified as mono- or multibacterial based on the initial bacterial cultures. The levels of C-RP (mg/L) and blood leukocyte count ( $E^9/L$ ) prior to debridement were evaluated at infection onset (I), prior to debridement (II), and at the time of flap reconstruction (IV). Fracture consolidation and hardware removal or retention were assessed from the radiographs and operative records at the time of the debridement (II), and at the time of flap reconstruction (IV).

In addition to the previously mentioned characteristics, in Study I, delay from fracture to admission, soft tissue condition (Tscherne grade 0–4 in closed fractures, and Gustilo grade I–III in open fractures), delay from admission to surgery, duration of surgery, use of a tourniquet, surgeon experience, sub-optimal timing of antibiotic prophylaxis (administered >60 minutes before the incision or after the incision, or < 5 minutes before inflation or after inflation of the tourniquet), wound closure method (staples or interrupted monofilament sutures), application of a cast in the operating room, and postoperative wound necrosis or blistering as well as non-compliance (defined as not adhering to the postoperative weight bearing regimen) were recorded. In Study II, delay from index surgery to infection onset was analyzed, and infections were divided into early ( $\leq 42$  days after surgery) or late ( $> 42$  days after surgery). The number of additional surgical procedures was collected. In Study III, the number of patients with a posterior malleolar fracture, an associated medial malleolar fracture, or a Chaput-Tillaux fragment was recorded. The time of day of surgery, duration of surgery, and surgeon experience were collected, and the fixation method of each malleolus and syndesmotom screw application was noted. In Study IV, the time from infection onset to flap reconstruction was determined. The location of the soft-tissue defect (lateral, medial, or bilateral) and the type of flap used for soft-tissue coverage was recorded. The number of surgical debridements prior to flap coverage, and the number of subsequent operations following flap reconstruction was collected. The need for local wound care or NPWT for wound bed conditioning was analysed. Postoperative complications were recorded.

## Radiological evaluation

Postoperative radiographs were assessed for ankle joint congruency (talar shift or talar tilt) and possible fracture malreduction of each malleolus (mm) (I–IV). Additionally, fibular shortening (Thordarson 2012), medial clear space widening ( $> 4$  mm in mortise view) (Nielsen et al. 2005), tibiofibular clear

space (TFCS; the distance between the medial border of the fibula and the floor of the tibiofibular incisura on the AP view at 10 mm above the ankle joint level) (Beumer and Swierstra 2003), and syndesmotom screw positioning were analyzed (III). Attention was paid to the fibular positioning in the tibiofibular incisura at 10 mm above the joint line in the axial CT scan (III).

In Study III, the surgical errors were classified according to the anatomic site of malreduction: fibula, medial malleolus, posterior malleolus, Chaput-Tillaux fragment, and syndesmosis. Problems related to syndesmotom reduction or fixation were further divided into four categories: malpositioning of the fibula in the tibiofibular incisura with a syndesmotom screw, tibiofibular widening (TFCS  $> 6$  mm) (Pneumaticos et al. 2002), positioning of a syndesmotom screw posterior to the posterior margin of the tibia (missed), and syndesmotom transfixation in the presence of a stable syndesmosis. A syndesmotom screw was considered unnecessary if lateral and external rotation stress tests were negative after proper reduction and fixation of the fracture at the time of reoperation (van den Bekerom 2011).

The presence of external callus bridging the fracture site or absence of fracture lines was regarded as radiological union, and severe talocrural osteoarthritis was defined as KL grade III–IV (Kellgren and Lawrence 1957) (II–IV).

## Definition of treatment failure and flap-related complication

In Study II, treatment failure following ankle fracture infection was defined as persistent infection requiring suppressive antibiotic treatment, severe talocrural osteoarthritis, nonunion requiring fusion, amputation, or death related to treatment of an infected ankle fracture. In Study IV, flap take-back was defined as any flap complication requiring a return to the operating theatre. Partial flap loss was considered when debridement occurred for partial flap necrosis. Total flap loss required a complete removal of the necrotic flap with a subsequent reconstruction. A patient was considered to have a persistent infection if hardware removal was required following flap reconstruction to eradicate the causative pathogen.

## Outcome measurements

In Study IV, Olerud Molander ankle score (OMA) was used for functional outcome measurement (Olerud and Molander 1984). This score is a self-administered patient questionnaire with a result ranging from 0 (totally impaired) to 100 (completely unimpaired), and is based on nine different items: pain, stiffness, swelling, stair climbing, running, jumping, squatting, supports, and work/ activities of daily living.

The 15D was used to measure patients' health-related quality of life (Sintonen 2001). This standardized self-administered

instrument can be used both as a profile and as a single index score measure. It is a health state descriptive questionnaire that consists of the following 15 dimensions: mobility, vision, hearing, breathing, sleeping, eating, speech, excretion, usual activities, mental function, discomfort and symptoms, depression, distress, vitality, and sexual activity. The 15D scores on a 0–1 scale (0 = being death, 1 = full health) are shown to be highly reliable, sensitive and responsive to change (Sintonen 2001).

Subjective pain and general satisfaction were assessed with two single questions using numeric rating scale (NRS) (range 0–10) (Hjermstad et al. 2011). Additionally, the patients were asked whether they had recovered to their pre-injury level of activity or if they needed any walking aids. It was also recorded, if the patients were able to wear all the shoes they used to wear before the injury. Total range of motion of the ankle joint was recorded with a goniometer. Calf muscle strength was assessed with rising-on-toes test (Kaikkonen et al. 1994). In the test, the patient is asked to rise on the toes with one leg as many times as possible at a pace of 60 times per minute to measure the fatigue of the plantar flexors. The pace (1/sec) was given with a metronome. Calf muscle and ankle circumference were measured at the widest part of the muscle and 5 cm proximal to the tip of the lateral malleolus, respectively. The uninjured leg was used for comparison. The flap was photographed, and the plastic reconstructive surgeon evaluated the consistency of the flap.

## Statistical analyses

An independent biostatistician performed the statistical analysis of the data (I–III). Results of logistic regression analyses are expressed using odds ratios (OR) with their 95% confidence intervals (CI). P values of < 0.05 were considered significant. The differences between the case and control groups were tested with McNemar's test (dichotomous variables), the test of marginal homogeneity (polytomous variables), and the Wilcoxon signed-rank test (continuous variables) (I,III). In Study I, McNemar's test was also used to analyze differences between the two groups in postoperative non-compliance. In Study II, differences in categorical variables between the two groups were analysed using the chi-squared test or Fisher's exact test, and differences in continuous variables were tested with two-sample t-test or Mann-Whitney U-test. In Study IV, independent samples t-test was used to compare the mean 15D scores of the study patients and a representative sample of the age-standardized general population. Logistic regression analysis was used to determine significant risk factors for deep SSI (I) and significant risk factors for treatment failure (II). Multivariable conditional logistic regression analysis using a stepwise procedure was applied to identify the independent risk factors (I, II). Factors with p value < 0.2 in the univariate analyses were included in the multivariable model (I, II). In the final model, multicollinearity between the risk factors was not detected (I).

## Results

### Incidence of early reoperation following ankle fracture surgery

Study III showed, that 79 of 5,071 (1.6%) operatively treated ankle fracture patients were reoperated on within the first post-operative week due to malreduction observed in postoperative radiographs. The incidence of early reoperation was 1.5% and 1.6% during the time period of 2002–2006 and 2007–2011, respectively (Figure 5). The mean age of these patients was 44 years (range 18–80), and 49% of them were women.

### Indications for early reoperation

The indications for early reoperation following ankle fracture surgery were classified according to the anatomic sites of malreduction (Table 5 and Figure 6).

Of the 79 (46%) reoperated patients, 36 had a combination of at least two different malreductions, most commonly of both the fibula and syndesmosis (16 of 79 patients, 20%).

Four main types of errors were identified related to syndesmotomic reduction or fixation, with malpositioning of the

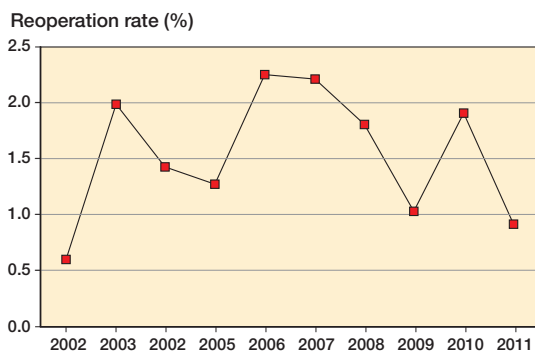


Figure 5. The incidence of early reoperation during the study period (III).

Table 5. Indications for reoperation (n = 79) (III)

Anatomic site of malreduction <sup>a</sup>	n (%)
Syndesmosis	47 (59)
Fibula	30 (38)
Medial malleolus	30 (38)
Posterior malleolus	12 (15)
Chaput-Tillaux fragment	4 (5)

<sup>a</sup> one patient may have more than one malreduction

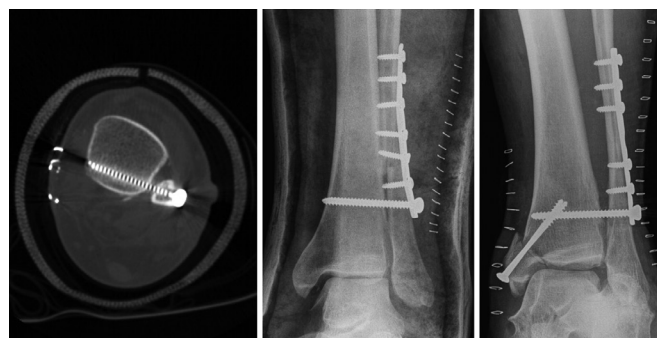

Figure 6. Three of the most common errors in reoperated patients: Left) posterior positioning of the fibula in the tibiofibular incisura, Middle) fibular shortening associated with syndesmotomic malreduction, Right) malreduction of medial malleolus (III).

fibula in the tibiofibular incisura being the most common error (Table 6).

Of the 24 patients with fibular malpositioning in the tibiofibular incisura, a CT scan was available for further analysis in 14 patients (six patients with a type B fracture and eight patients with a type C fracture). A posterior malpositioning was observed in nine (64%) of these patients. Of the 30 patients with fibular malreduction, 20 (67%) presented shortening, and in 17 of these 20 (85%) patients, fibular shortening was associated with malreduction at another anatomic site. Conversely, malreduction of the medial malleolus often presented as an isolated indication for reoperation (16 of all 30 patients with medial malleolus malreduction, 53%). In all four patients with a Chaput-Tillaux fragment, reoperation was due to a primarily missed fracture.

Table 6. Errors related to syndesmotomic reduction or fixation (n = 47) in relation to the fracture type (III)

Characteristic	Fracture type (Weber)			Total
	A	B n (%)	C n (%)	
Number of patients	2	42	32	76 <sup>a</sup>
Syndesmotomic screw	0	15 (36)	26 (81)	41
Error related to syndesmotomic reduction or fixation		0 (48)	27 (84)	47
Malpositioning of the fibula in the tibiofibular incisura		9	15	24
Tibiofibular widening		8	5	13
Posterior positioning of screw (missed)		2	4	6
Syndesmotomic transfixation in the presence of a stable syndesmosis		1	3	4

<sup>a</sup> 3 patients had no fibular fracture thus could not be classified with Weber classification

## Results of early reoperation

Correction of the malreduction was achieved in the majority of reoperated cases (84%). In 13 of the 79 patients, for whom malreduction could not be corrected, a trimalleolar fracture was the most common type (69%). None of these patients had a unimalleolar fracture. The most common persistent malreduction was related to the medial malleolus (seven of 13 patients). In 10 of the 13 patients with unsuccessful correction, post-traumatic talocrural osteoarthritis was seen in the last available follow-up radiographs.

## Incidence of deep SSI following ankle fracture operations

Study I showed, that the incidence of deep SSI following ankle fracture operations is 6.8%. The mean age of the patients with deep infection was 56 years (range 20–90), and 44% of them were men. Infection was diagnosed on average at 53 days after internal fixation of the fracture. The mean operative time for patients with deep infection was 88 minutes (range 17–382) and for controls 69 minutes (range 14–240) ( $p < 0.001$ ). Only 4% of patients with deep postoperative infection had multiple concomitant risk factors (diabetic smoker with compromised soft tissue). Patients with deep infection needed on average two additional surgical interventions (range 0–10). Altogether, 103 of 131 (79%) patients had at least one subsequent operation due to the infection. In Study III, the rate of deep infection did not significantly differ between reoperated patients and controls (6% versus 3%;  $p = 0.3$ ).

## Most common causative pathogens

In Study I, 88 of 131 (67%) deep infections were monobacterial, and the three most prevalent causative pathogens were *Staphylococcus aureus* ( $n = 43$ ), *Staphylococcus epidermidis* ( $n = 34$ ) and *Pseudomonas aeruginosa* ( $n = 3$ ). The remaining 43 infections (33%) were multibacterial, and the most frequent pathogens in these infections were *Staphylococcus epidermidis* ( $n = 23$ ), *Staphylococcus aureus* ( $n = 16$ ), and *Enterococcus faecalis* ( $n = 8$ ). At the time of infection onset, 60% of the patients with deep infection presented with elevated C-RP values ( $> 10$  mg/L). Similarly, 52% of the patients had elevated blood leukocyte count ( $> 8.2$  E<sup>9</sup>/L).

In Study II, *Staphylococcus epidermidis* was the most common causative pathogen (54%) in patients with treatment failure. Infections caused by *Staphylococcus aureus* were observed in 42% of the patients, and *Pseudomonas aeruginosa* was the causative agent in 8% of the patients. The mean levels of C-RP prior to debridement were 59 mg/L (range 5–297) and 35 mg/L (range 3–235) in patients with treatment failure and treatment success, respectively ( $p = 0.1$ ). The correspond-

Table 7. Univariate conditional logistic regression analyses for patient-related risk factors for deep SSI (I)

Factor	Patients with infection n (%)	Control patients n (%)	OR (95% CI)	p-value
Smoking	47 (36)	17 (13)	4.8 (2.2–10)	<0.001
Alcohol abuse	29 (22)	12 (9)	3.8 (1.6–9.4)	0.003
Diabetes	20 (15)	9 (7)	2.2 (1.0–4.9)	0.047
Fracture dislocation	71 (54)	49 (37)	2.0 (1.2–3.5)	0.007
Tscherne grade $\geq 1$	38 (32)	19 (15)	2.6 (1.3–5.3)	0.006

ing mean levels of blood leukocyte count were 8.6 E<sup>9</sup>/L (range 3–14) and 7.7 E<sup>9</sup>/L (range 3–19) ( $p = 0.1$ ).

In Study IV, *Staphylococcus aureus* was the most common causative pathogen (53%) for deep monobacterial infection, and infections caused by *Staphylococcus epidermidis* were observed in 32% of the patients. A multibacterial infection was observed in 18 of 56 (32%) patients. The mean time from infection onset to flap reconstruction was 28 days (range 1–150). At the time of the flap reconstruction, bacterial cultures were still positive in 24 of 56 (43%) patients, and *Staphylococcus epidermidis* was observed in 58% of these cultures. The mean levels of C-RP prior to flap reconstruction were 13 mg/L (range 3–75), and the mean levels of blood leukocyte count were 7.4 E<sup>9</sup>/L (range 3–16).

## Risk factors for deep SSI

Patient-related factors, which were associated with a significantly increased risk of deep SSI following ankle fracture operations are shown in Table 7 (I).

In addition to these factors, postoperative non-compliance significantly increased the risk for deep SSI (13 patients with deep infection, 0 patients in control group,  $p < 0.001$ ). Surgery-related factors for deep SSI following ankle fracture operations are shown in Table 8 (I).

No significant associations were found with regard to obesity (BMI  $> 30$  kg/m<sup>2</sup>) ( $p = 0.4$ ), ASA score of 3 or 4 ( $p = 0.051$ ), neuropathy ( $p = 0.08$ ), schizophrenia ( $p = 0.054$ ), injury mechanism ( $p = 0.4$ ), Weber-classification ( $p = 0.6$ ), presence of an open fracture ( $p = 0.3$ ), delay from admission to surgery ( $p = 0.2$ ), tourniquet use ( $p = 0.5$ ), wound closure method ( $p = 0.6$ ), surgeon experience ( $p = 0.3$ ), nor for use of a syndesmotic screw ( $p = 0.4$ ) (I). In the multivariable analysis, the variables that remained independently associated with an increased risk of deep SSI are presented in Table 9 (I).

## Flap reconstruction for hardware exposure following deep ankle infection

Study IV showed, that the most commonly used flap recon-

Table 8. Univariate conditional logistic regression analyses for surgery-related risk factors for deep SSI (I)

Factor	Patients with infection n (%)	Control patients n (%)	OR (95% CI)	p-value
Suboptimal timing of prophylactic antibiotic therapy	42 (32)	27 (21)	1.9 (1.0–3.4)	0.035
Duration of surgery > 90 min	46 (35)	22 (17)	2.7 (1.5–5.0)	0.001
Postoperative skin necrosis or blistering	19 (15)	4 (3)	4.8 (1.6–14)	0.005
Malreduction in postoperative radiographs	19 (15)	6 (5)	3.4 (1.3–9.2)	0.016
Application of a cast in the operating room	31 (24)	59 (45)	0.4 (0.2–0.7)	<0.001

Table 9. Multivariable conditional logistic regression analyses for independent risk factors for deep SSI following ankle fracture operations (I)

Factor	Adjusted OR (95% CI)	p-value
Smoking	3.7 (1.6–8.5)	0.04
Duration of surgery > 90 min	2.5 (1.1–5.7)	0.001
Application of a cast in the operating room	0.4 (0.2–0.8)	<0.001

struction for hardware exposure following deep ankle fracture infection is a distally based peroneus brevis muscle flap with a split-thickness skin graft (STSG) (71%) (Figure 7). The 58 flap reconstructions for infected hardware exposure following ankle fracture operations are presented in Table 10. A microvascular free flap was required only in one patient. Flap reconstruction was performed over lateral malleolus in 91% of patients. The mean age of the patients was 57 years (range 25–93), and nearly half (48%) of the patients were smokers. The most common fracture type (45%) was a trimalleolar ankle fracture.

Table 10. The 58 flap reconstructions performed in 56 patients (IV)

Type of flap reconstruction	n (%)
Distally based peroneus brevis flap	41 (71)
Direct cutaneous flap	8 (14)
Bipedicular (n = 5)	
Transposition (n = 3)	
Propeller flap	6 (10)
Tibialis posterior (n = 3)	
Fibularis (n = 2)	
Tibialis anterior (n = 1)	
Suralis flap	2 (3)
Microvascular free flap (Latissimus dorsi)	1 (2)

Table 11. Patients with a complication following flap reconstruction for exposed hardware after deep ankle fracture infection (n = 56) (IV)

Complication	Number of patients <sup>a</sup>
Flap related complications requiring surgery	
Partial flap loss	14
Total flap loss	4
Incomplete take of skin graft	4
Hematoma	3
Other complications	
Severe osteoarthritis (KL III-IV)	12
Persistent infection	5
Fracture nonunion requiring fusion	1
Death related to treatment	1

<sup>a</sup> 8 patients had more than one complication

### The outcome of patients with flap reconstruction

Of the 56 patients, 32 (57%) had a complication (Table 11) (IV), and 22 of 56 (39%) patients required subsequent surgical interventions in the operating theatre due to a flap-related complication. Five patients required hardware removal due to

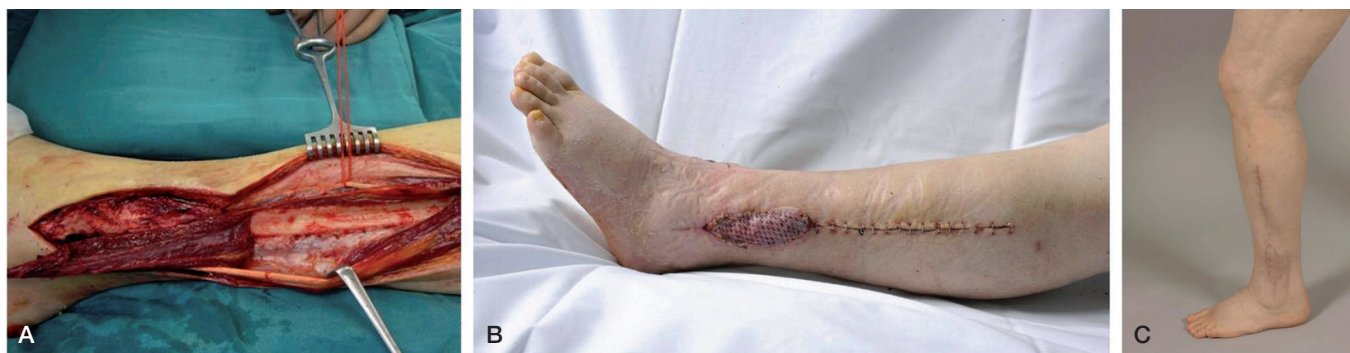

Figure 7. A distally based peroneus brevis flap with a split-thickness skin graft: A) during surgery; B) 9 days after surgery; C) 22 months after surgery at follow-up visit.

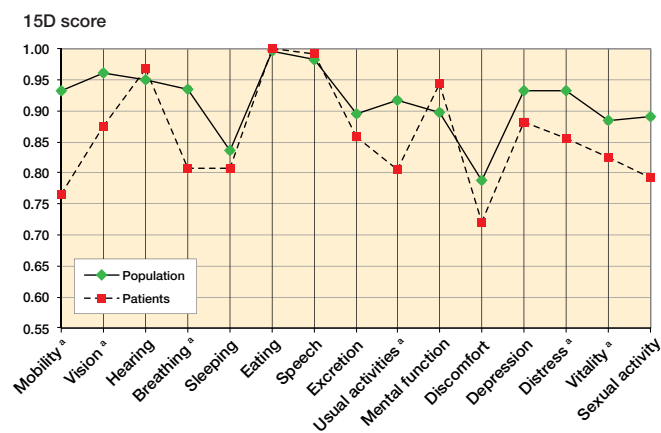


Figure 8. The 15D profile of the patients and those of a representative sample of an age-standardized general population (IV). <sup>a</sup>  $p < 0.05$ .

a persistent infection. Of the soft-tissue defects, 93% eventually healed, but four (7%) patients suffered a total flap loss and required a flap re-reconstruction. Patients needed an average of 2.9 surgical interventions (range 1–10) following deep infection. With flap reconstruction, hardware could eventually be salvaged in 53% of patients with a non-consolidated fracture.

The mean OMA score was fair or poor in 53% of the 32 clinically examined patients, and only 56% of the patients had recovered their pre-injury level of function. Half of the patients had shoe wear limitations. The mean 15D score of the patients was significantly lower than that of a representative sample of age-standardized general population. The patients had poorer scores than the general population on the dimensions of mobility, vision, breathing, usual activities, distress and vitality (Figure 8). The mean pain NRS was 2.1 and the mean satisfaction NRS was 6.6. The mean ROM of the ankle joint was 15 degrees less than in the contralateral ankle (IV).

### Incidence of treatment failure following deep SSI

In Study II, treatment failure occurred in 26 of 97 (27%) patients with deep postoperative ankle fracture infection (Figure 4). The mean age of these patients was 54 years (range 20–72). The most common fracture type (58%) was a trimalleolar ankle fracture, and 73% of the patients had a fracture dislocation. Most infections (69%) manifested  $\leq 42$  days after the index surgery (Table 12).

### Risk factors for treatment failure following deep SSI

Factors, which significantly increased the risk of a treatment failure, are presented in Table 13 (II).

Table 12. Characteristics of patients with treatment failure and success (II)

Characteristics	Treatment failure (n = 26)	Treatment success (n = 71)	p-value
Age (years) <sup>a</sup>	54 (20–72)	58 (24–84)	0.1
Male	14 (54%)	27 (38%)	0.2
Body mass index (kg/m <sup>2</sup> ) <sup>a</sup>	28 (18–39)	28 (18–46)	0.6
ASA class 3 or 4	10 (38%)	28 (39%)	0.9
Fracture type			0.5
unimalleolar	5 (19%)	13 (18%)	
bimalleolar	6 (23%)	25 (35%)	
trimalleolar	15 (58%)	33 (47%)	
Fracture dislocation	19 (73%)	37 (52%)	0.06
Open fracture	6 (23%)	6 (8%)	0.08
Early infection onset	18 (69%)	46 (65%)	0.7

<sup>a</sup> mean (range)

Table 13. Univariate logistic regression analysis of the risk factors predicting treatment failure following deep ankle fracture infection (n = 97) (II)

Factor	Treatment failure (n=26) n (%)	Treatment success (n=71) n (%)	OR (95% CI)	p-value
Smoking	15 (58)	18 (25)	4.0 (1.6–10)	0.004
Alcohol abuse	10 (38)	11 (15)	3.4 (1.2–9.4)	0.02
Diabetes	9 (35)	7 (10)	3.4 (1.1–11)	0.04
Weber type C fracture	11 (42)	12 (17)	3.6 (1.3–9.8)	0.01
Multibacterial infection	13 (50)	18 (26)	2.9 (1.1–7.4)	0.03
Hardware removal from nonunited fracture	15 (58)	14 (20)	5.6 (2.1–15)	<0.001
Nonunited fracture at debridement	20 (77)	33 (47)	3.8 (1.4–11)	0.01
Malreduction in postop. radiographs	7 (27)	6 (8)	4.0 (1.2–13)	0.02
$\geq 2$ additional surgical procedures	19 (73)	21 (30)	6.5 (2.4–18)	<0.001

Table 14. Multivariable logistic regression analysis of the risk factors predicting treatment failure following deep ankle fracture infection (n = 97) (II)

Factor	OR (95% CI)	p-value
Smoking	4.1 (1.3–13.0)	0.02
Malreduction in postoperative radiographs	4.6 (1.0–20.3)	0.04
Hardware removal from nonunited fracture at debridement	3.3 (1.0–10.7)	0.04

In the multivariable analysis, the variables that remained independently associated with an increased risk for treatment failure are presented in Table 14 (II).

## Discussion

### The most important complications

The number of geriatric patients sustaining rotational ankle fractures is rising (Kannus et al. 2002, Olsen et al. 2013). Recent studies have shown an increase in more complicated bi- and trimalleolar fractures in these patients (Thur et al. 2012). As the number of ankle fractures in elderly patients with comorbidities is increasing, a concomitant rise in the absolute amount of complications related to ankle fracture surgery may be expected in the near future.

Surgical treatment of ankle fractures may be accompanied by several complications. They could be classified as preoperative, perioperative, early postoperative and late postoperative complications (Figure 9).

The most frequently encountered complications are wound complications, of which deep infection may have the most devastating consequences (Soohoo et al. 2009, Schepers et al. 2013). For this reason, the current study focused on deep SSI following ankle fracture operations. Study I identified significant patient- and surgery-related risk factors for deep SSI, and Study IV determined the outcome of patients treated with flap reconstruction following deep infection with hardware exposure. Study II recognized the main factors predisposing to a treatment failure following deep infection. In contrast to the other studies, the focus of Study III was not on postoperative infection. Instead, the purpose of that study was to evaluate the most common surgical errors resulting in early reoperation following ankle fracture surgery.

The rate of deep SSI was 6.8% (I), which is slightly higher than in previous reports (Soohoo et al. 2009, Wukich et al.

2010, Schepers et al. 2011). The relatively high infection rate may partly be due to over-representation of complex fractures and patients with multiple comorbidities referred from other community hospitals. Including the 131 cases of deep SSI, a total amount of 345 complications were observed in the 1,915 operatively treated ankle fracture patients (Unpublished data). Deep infections constituted the majority (38%) of the observed complications. Other important reasons for postoperative complication were a technical error during the surgical procedure and a loss of reduction (Unpublished data). The data from the Patient Insurance Center reveal that 35% of the compensated ankle injuries in Finland are due to a technical error during the surgical procedure (Hirvensalo et al. 2009). Additionally, inadequate diagnostics, wrong treatment modality, and deep SSI were common reasons for a compensation (Hirvensalo et al. 2009).

Taken together, the most important reasons for a complication following ankle fracture surgery seem to be inadequate diagnostics, wrong treatment modality, technical error during the surgical procedure, deep infection, and loss of reduction (Figure 10).

Deep infection is the most important complication following ankle fracture surgery. Although successful treatment of the soft-tissue defect with exposed hardware can be achieved with reconstructive procedures (IV), a treatment failure is common (II). In the absence of a panacea for postoperative infections, we rely primarily on preventive measures. Therefore, identification of risk factors is crucial for developing strategies to prevent potentially disastrous complications.

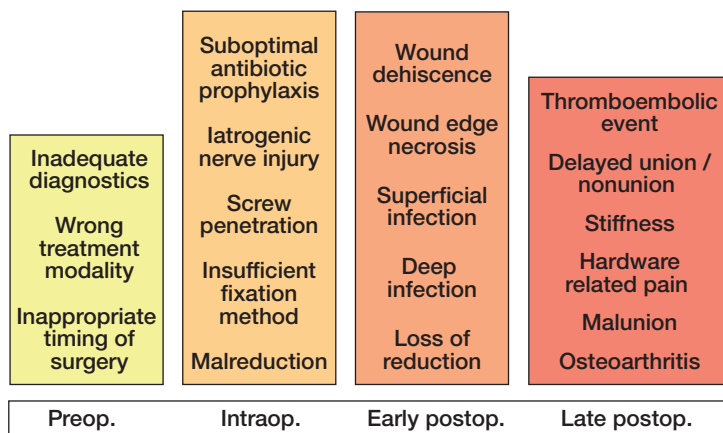


Figure 9. Complications and factors related to the formation of a complication following operative treatment of ankle fractures.

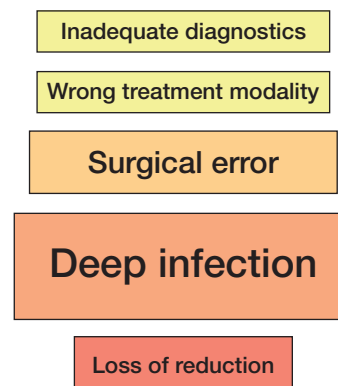


Figure 10. The most important reasons for a complication following ankle fracture surgery.

## Recognition of “red flags”

The goal of ankle fracture surgery should be the achievement and maintenance of an anatomic reduction with minimal duration of surgical wound exposure to surrounding pathogens. In Study I, a prolonged operative time was an independent risk factor for deep infection. However, tourniquet use did not increase the risk of infection (I). Study III showed that problems related to syndesmotic reduction were the most important indications for early reoperation, and that more severe fracture patterns were associated with postoperative malreduction. Furthermore, we found that fibular shortening can initiate an insidious cascade of events leading to a combination of surgical errors (III). The above findings together support the use of a tourniquet as a measure to facilitate accurate fracture reduction with a shorter duration of surgery.

A significantly lower number of infections was observed, when a cast was applied in the operating room following ankle fracture operations (I). This is not a surprising finding, since immobilization may have a beneficial effect on soft tissue recovery (Lehtonen et al. 2003). Furthermore, cast application in the operating room probably protects the surgical wound from bacterial contamination, since the dressings are less likely to be opened during the following few days (Bosco III et al. 2010). The above conclusion seems rational, but soft tissue condition may be a confounding factor, since patients with more severe swelling are more likely to have delayed cast application. Although we do not believe that immediate cast application itself prevents deep infection, our findings suggest that a cast should be applied as early as possible, provided that soft tissue injury is minimal.

We noted, that suboptimal timing of antibiotic prophylaxis increases the risk for deep SSI following ankle fracture surgery (I). This is not a surprising finding, since the efficacy of a single-dose prophylactic antibiotic therapy has already been described (Gillespie et al. 2001, Jaeger et al. 2006, Flecher et al. 2007, Slobogean et al. 2010). However, to have the desired effect, antibiotic prophylaxis has to be administered within 60 minutes before the incision (Flecher et al. 2007). In addition, it has to be fully administered before the tourniquet is inflated (Bosco III et al. 2010). We observed that antibiotic prophylaxis was administered suboptimally in many patients even without postoperative infection (I). This is a cause for concern since similar results have recently been reported in another study, reflecting the possible magnitude of this problem (Olsen et al. 2008). Suboptimal timing of antibiotic prophylaxis is an important risk factor for infection, and easily modifiable since it is due to a human error. The routine use of a surgical check-list is one solution to improve timely and effectively administered antibiotic prophylaxis.

Smoking is a major risk factor for poor fracture healing (Rightmire et al. 2008), and it has been shown to increase the risk of postoperative infection up to 5-fold following ankle fracture surgery (Nåsell et al. 2011). Our results support these

findings, since tobacco use was the strongest predictor of deep infection even after adjusting for all other variables (I). The current study also revealed that most patients requiring flap reconstruction for an infected ankle fracture were smokers (IV). Additionally, smoking was one of the most important factors predisposing to treatment failure following ankle fracture infection (II). Based on these findings, every smoker undergoing ankle fracture surgery should be encouraged to quit. Even a reduction in smoking may have beneficial effects (Kean 2010), especially in patients with a compromised soft tissue envelope (I,IV).

A delay from admission to surgery did not increase the risk of deep infection following ankle fracture surgery (I). However, previous studies have shown that in patients with fracture dislocation, a delay in surgery increases the risk of postoperative infection (Carragee et al. 1991, Höiness et al. 2000). Similarly, we noted that a fracture dislocation or even minor superficial skin abrasion results in an increased risk of postoperative infection (I). This is in line with a previous study reporting that major perioperative soft-tissue injury has a negative effect on long-term functional outcome following ankle fracture operations (Höiness et al. 2001). Based on these findings, judicious timing of surgery allowing for soft tissue recovery is warranted in patients without an associated ankle fracture dislocation.

## Ankle fracture surgery – where do we go wrong?

Data on failed fracture surgery is limited and often underreported. To our knowledge, Study III was the first to focus on determining the most common surgical errors resulting in early reoperation after ankle fracture surgery.

It has recently been demonstrated that proper reduction of syndesmosis is technically more demanding than previously thought (Miller et al. 2009, Mukhopadhyay et al. 2011, Franke et al. 2012, Sagi et al. 2012). Direct visualization and open reduction of the syndesmosis has been recommended (Miller et al. 2009), since lateral translation and rotational malalignment of the fibula at the level of the syndesmosis may go undetected (Marmor et al. 2011). This is reflected in our findings, since the majority of reoperated cases were due to syndesmotic malreduction (III). Studies have revealed a large variation in syndesmosis anatomy regarding the degree of incisura concavity and the position of the fibula within it (Elgafy et al. 2010, Mukhopadhyay et al. 2011, Franke et al. 2012, Sagi et al. 2012). Additionally, recent studies have shown that syndesmotic transfixation may not be necessary in type B ankle fractures despite intraoperatively confirmed syndesmotic disruption (Pakarinen et al. 2011c, Kortekangas et al. 2014). In our study, the most common error was a posterior fibular malpositioning in the tibiofibular incisura (III). Our findings are in line with a previous study cautioning, that the syndesmotic screw may be a factor leading to

syndesmotic malpositioning (Vasarhelyi et al. 2006, Nimick et al. 2013) (III).

Studies have shown that anatomic syndesmosis reduction cannot be achieved if the fibula is malreduced (Leeds and Ehrlich 1984). In the current study, the most commonly combined surgical errors were malreductions of the fibula and syndesmosis (III). Typically, the fibula was shortened, resulting in erroneous syndesmotic transfixation. Since malunion of the fibula is the most common and the most difficult malunion to reconstruct (van Wensen et al. 2011), particular attention must be paid to fibular length assessment in the operative treatment of this common fracture.

### Soft-tissue reconstruction for infected ankle fractures

Soft-tissue defects around the ankle are demanding to manage (Levin 2001), and lower extremity flap reconstruction is associated with higher complication rates than those to any other part of the body (Benacquista et al. 1996, Culliford et al. 2007). Free flap transfers have been considered as the ideal coverage method for infected defects of the distal leg (Thorason et al. 2000, Cyrochristos et al. 2009, Viol et al. 2009). In the current study, most soft-tissue defects following ankle fracture infection occurred over the lateral malleolus (IV). This is not surprising since most ankle fractures occur over the lateral malleolus (Zalavras et al. 2009). Although the number of flap-related complications was high, the majority of the infected soft-tissue defects around the ankle eventually healed with local fasciocutaneous and muscle flaps (IV).

Pre-flap infection has shown to be an independent predictor of adverse flap outcomes (Liu et al. 2012). Of note, even though all patients in Study IV had a deep infection prior to flap reconstruction, the number of complications was less than in a previous study assessing post-flap complications in non-united fractures of the distal leg (Vaienti et al. 2012a). Flap failure rates as high as 23% have been reported in patients with pre-flap infection (Gonzalez et al. 2002). Interestingly, in the current study only 7% of the patients suffered a total flap loss (IV).

### Hardware removal

Hardware removal prior to fracture union led to a permanent complication in the majority of patients with an infected ankle fracture, and it was the most important factor predisposing to a treatment failure (II). The presence of hardware exposure ultimately necessitates soft-tissue reconstruction, because inconsistent results have been achieved with secondary wound or split-thickness skin grafting (Viol et al. 2009). Hardware stability, duration of hardware exposure, and presence of an infection have been identified as important factors

for the potential salvage of the exposed hardware with soft-tissue coverage (Gonzalez et al. 2002, Gonzalez and Winzweig 2005, Cavadas and Landin 2007, Viol et al. 2009, Liu et al. 2012, Vaienti et al. 2012a). We showed that infected hardware could be salvaged with flap reconstruction in more than half of the patients with a non-consolidated and infected ankle fracture (IV). Based on the findings of the current study, we do not recommend hardware removal from a nonconsolidated ankle fracture infection (II, IV).

### The outcome of patients with an infected ankle fracture

Postoperative malreduction predisposes to poor clinical outcome and subsequent osteoarthritis. We showed that fracture type, associated medial malleolar fracture, posterior malleolar fracture, fracture dislocation, duration of index surgery, and medial malleolar fixation with other than two screws were all associated with postoperative malreduction (III). Additionally, Study II showed that malreduction in postoperative radiographs was an independent risk factor for treatment failure following ankle fracture infection (II). Fortunately enough, in the majority of reoperations postoperative malreduction could be corrected without an increased risk for postoperative infection (III). According to our findings, more complex fractures and fracture dislocations are more prone to postoperative malreduction, and the treatment of these fractures should probably be left to surgeons with greater expertise.

In patients requiring flap reconstruction for ankle fracture infection (IV), the average functional outcome assessed with the OMA score was similar to those previously reported following lower leg soft-tissue reconstruction with a distally based peroneus brevis flap (Lorenzetti et al. 2010). However, the OMA score was fair or poor in 53% of the examined patients, and only half of the patients recovered their pre-injury level of function (IV). Additionally, 25% of the patients were unable to ambulate without walking aids at the time of the follow-up visit, and half of them had shoe wear limitations (IV). The 15D showed that the HRQoL of the patients was poorer than that of a sample of age-standardized general population (IV).

Although successful treatment of a soft-tissue defect with exposed hardware can be achieved with reconstructive procedures (IV), a treatment failure following ankle fracture infection is common (II). Surgical site infections are known to prolong total hospital stay and increase total costs by more than 300% (Whitehouse et al. 2002, de Lissovoy et al. 2009). Since patients with flap reconstruction needed an average of 2.9 surgical interventions following deep infection (IV), and patients with treatment failure required 1.5 times more surgical procedures than patients with treatment success (II), we expect the total costs of treating patients with deep infection to be substantially higher than previously thought.

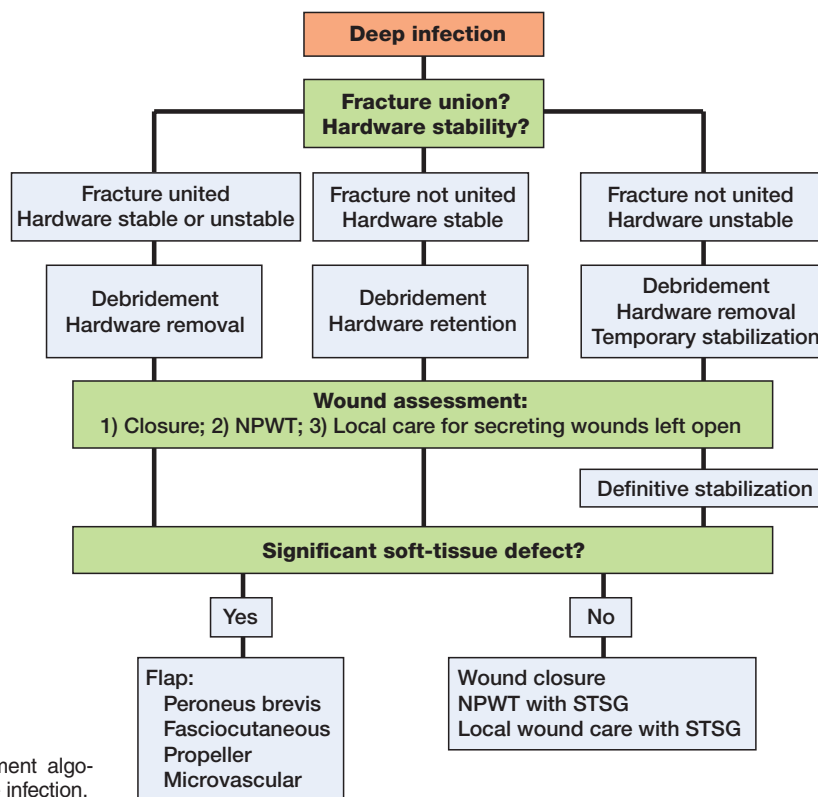


Figure 11. Proposed treatment algorithm for deep ankle fracture infection.

### Multidisciplinary musculoskeletal infection team

Deep ankle fracture infections are best managed by a multidisciplinary musculoskeletal infection team consisting of an orthopaedic trauma surgeon, a plastic reconstructive surgeon, a vascular surgeon, and a specialist in infectious diseases. Fracture union is the most important aspect when deciding the proper treatment path, and radiographs as well as CT scans should be carefully evaluated prior to debridement (Figure 11). Unstable implants should always be removed, and stable implants should be removed from all patients with a consolidated fracture. If hardware has to be removed from a nonconsolidated fracture, temporary stabilization with external fixator should be considered, since ankle fracture infection with an incongruent joint is doomed to failure. Removal of retained implants should be considered after fracture consolidation, since the recurrence of infection is common.

After debridement, wounds may be left open and local wound care or NPWT is used for wound bed conditioning. NPWT provides effective temporary wound coverage and reduces the complexity of the wound allowing simpler soft tissue procedures for definitive wound closure; however, it does not allow delay in soft-tissue coverage without a concomitant increase in the infection rate (Stannard et al. 2010, Hou et al. 2011, Liu et al. 2012).

Before planning of any reconstructive procedures, the vascular status of the patient must be carefully evaluated with palpation of the pulses, Doppler ultrasound examination, and

with angiography in patients with absent pulses. In complicated cases, vascular intervention should be considered before reconstructive soft-tissue procedures. The type of the required soft-tissue procedure depends on many patient- and wound-related aspects, and should be evaluated by the plastic reconstructive surgeon.

### Limitations and strengths of the study

An inherent limitation of the current study is the reliance on data provided by the medical and surgical charts. To control for these unavoidable reporting deficiencies, the charts of each patient were scrutinized, and records from all other medical specialties were assessed as well. In Study I, some occult infections may not have been identified. However, had occult or superficial infections progressed to a deep infection, they would probably be included in the study population. An important limitation of the Studies II and IV is that there was no standardized protocol for infected hardware removal prior to osseous union, and implant stability at debridement could not be categorically assessed. One of the limitations of Study III is that postoperative CT scans were not available for all reoperated patients, thus some minor syndesmotic malreductions may have been missed. Another limitation is that the design did not enable standardised outcome measurements. Additionally, it is possible that some older patients with malreduced fractures were not reoperated due to their general

health condition. However, there were no differences in the prevalence of multiple comorbidities between the reoperated and control patients. In Study IV, all included patients could be not examined at the follow-up visit.

The strengths of the current study include a large number of consecutive ankle fracture patients treated at a single institution. Furthermore, the great number of treating surgeons increases the generalizability of the results. One of the strengths of Study I is an extensive array of evaluated potential risk factors for ankle fracture infection. Another strength is the inclusion of only deep infections, because they can be diagnosed with high specificity, and have the greatest impact on clinical outcome. In Study II, in contrast to previous studies, the outcome criteria were chosen to be relevant in the clinical setting. One of the strengths of Study III is that radiographs were evaluated using well-defined criteria. Study IV included the biggest published series of patients requiring flap reconstruction to cover a soft-tissue defect following ankle fracture infection, and evaluated both subjective and objective outcome of the patients using validated questionnaires and clinical tests.

## Future aspects

As the number of geriatric patients sustaining ankle fractures increases, a growing number of complications following operative treatment of this common fracture may be expected. In the future, unnecessary surgery should be avoided, and the criteria for operative treatment of ankle fractures must be clearly defined. Unstable isolated lateral malleolar fractures with a congruent ankle joint should probably be treated by conservative means (Sanders et al. 2012, Slobogean et al. 2012). Additionally, in patients with multiple comorbidities, conservative treatment should probably be considered sometimes even in bi- and trimalleolar fractures.

The devastating nature of deep infection following operative treatment of an ankle fracture emphasizes the crucial role of preventive measures. Therefore, recognition of red flags such as diabetes, smoking, alcohol abuse, and compromised soft tissue condition is of paramount importance. The number of postoperative complications could be reduced with simple methods; every smoker undergoing ankle fracture surgery should be encouraged to quit; blood glucose levels should be evaluated and optimized in all patients because elevated blood glucose levels predispose to postoperative infection even in patients without a history of diabetes mellitus (Richards et al. 2012); and, surgery should be postponed in patients with a compromised soft-tissue envelope provided that the ankle joint remains congruent. A meticulous preoperative planning and implementation of a check-list seem to be valuable adjuncts in reducing human error as a source of postoperative infection. Additionally, a proper understanding and recognition of the most common surgical errors is of paramount importance to avoid the need for reoperation.

Studies have shown that fixation of even a small posterior malleolar fragment increases syndesmotic stability (Gardner et al. 2006, Miller et al. 2010, Irwin et al. 2013). A posterolateral approach to the fibula should probably be used more often, since it allows a more posterior positioning of the fibular plate with a simultaneous option for a posterior plating or fixation of a posterior malleolar fragment. Locking plates should be considered in patients with poor bone quality, as well as in obese, diabetic or noncompliant patients.

In most cases, deep infection occurs over the lateral malleolus; thus, in patients with multiple comorbidities bulky plates or syndesmotic screws with prominent screw heads positioned directly over the lateral malleolus should be avoided. In these patients, fibular nails, syndesmotic screws with smaller size heads, or rope-type fixation method of syndesmosis may play an important role (Rajeev et al. 2011, Bugler et al. 2012, Schepers 2012, Asloun et al. 2014). Syndesmotic instability should be carefully evaluated and unnecessary screws avoided (Kortekangas et al. 2014). Intraoperative CT scan may be required to provide an accurate reduction of syndesmosis with good functional outcome (Van Heest and Lafferty 2014).

Postoperatively, surgical incisions should not be manipulated during the first 48 hours. A cast should probably be applied to all patients already in the operating room, since it protects the wound from contamination, and prevents postoperative swelling. NPWT applied to the surgical incision directly after wound closure, as well as newer generation wound healing composite dressings with therapeutic agents may be valuable tools in treating compromised wounds in patients with a higher risk for postoperative infection (Boateng et al. 2008, Stannard et al. 2012).

In the future, deep ankle fracture infections are best managed by a multidisciplinary musculoskeletal infection team. A meticulous treatment plan is warranted to provide the patient the best possibilities for a successful outcome. PCR-based methods as well as sonication may be valuable tools in the proper diagnostics of an implant-related infection (Borens et al. 2013). Fracture union should be the most important aspect when deciding the proper treatment path. In comorbid patients with open wounds and retained implants, NPWT devices with antibiotic releasing sponges could be one solution providing valuable time for the fracture to consolidate. If hardware has to be removed from a non-consolidated fracture, antibiotic-releasing implants should be considered since infected ankle with an incongruent joint is doomed to failure. Careful vigilance after flap reconstruction should be carried out since flap-related complications occur frequently. All patients with deep SSI following ankle fracture operation need to be informed about the potential functional impairment that may result despite eventual reconstructive success of the soft-tissue defect.

The findings of the current thesis could serve as a basis for optimizing treatment algorithms for patients undergoing operative treatment of ankle fractures.

## Conclusions

On the basis of the present clinical studies, the following conclusions can be drawn:

1. Smoking, prolonged operative time, and delayed cast application are independent risk factors for deep SSI following ankle fracture operations.
2. Smoking, malreduction in postoperative radiographs, and hardware removal prior to fracture union are the most important factors predisposing to treatment failure following deep ankle fracture infection.
3. Problems related to syndesmotic reduction together with fibular shortening are the most important indications for early reoperation following ankle fracture surgery.
4. Soft-tissue defects following ankle fracture infections can be reconstructed with local flaps. Despite reconstructive success, patients perceive a poorer health-related quality of life, many have shoe wear limitations, and only half of them achieve their pre-injury level of function.

## References

- Akhtar S, Hameed A. Versatility of the sural fasciocutaneous flap in the coverage of lower third leg and hind foot defects. *J Plast Reconstr Aesthet Surg* 2006; 59: 839-45.
- Argenta L C, Morykwas M J, Marks M W, DeFranzo A J, Molnar J A, David L R. Vacuum-assisted closure: state of clinic art. *Plast Reconstr Surg* 2006; 117 Suppl 7: S127-42.
- Asloum Y, Bedin B, Roger T, Charissoux J L, Arnaud J P, Mabit C. Internal fixation of the fibula in ankle fractures. A prospective, randomized and comparative study: plating versus nailing. *Orthop Traumatol Surg Res* 2014; 100 Suppl 4: S255-9.
- Bach A D, Leffler M, Kneser U, Kopp J, Horch R E. The versatility of the distally based peroneus brevis muscle flap in reconstructive surgery of the foot and lower leg. *Ann Plast Surg* 2007; 58: 397-404.
- Bachoura A, Guitton T G, Smith R M, Vrahas M S, Zurakowski D, Ring D. Infirmity and injury complexity are risk factors for surgical-site infection after operative fracture care. *Clin Orthop Relat Res* 2011; 469: 2621-30.
- Bariteau J T, Fantry A, Blankenhorn B, Lareau C, Paller D, Digiovanni C W. A biomechanical evaluation of locked plating for distal fibula fractures in an osteoporotic sawbone model. *Foot Ankle Surg* 2014; 20: 44-7.
- Bauer M, Johnell O, Redlund-Johnell I, Johnsson K. Ankle fractures. *Foot Ankle* 1987; 8: 23-5.
- Bauer M, Jonsson K, Nilsson B. Thirty-year follow-up of ankle fractures. *Acta Orthop Scand* 1985; 56: 103-6.
- van den Bekerom M P. Diagnosing syndesmotic instability in ankle fractures. *World J Orthop* 2011; 2: 51-6.
- van den Bekerom M P, Haverkamp D, Kloen P. Biomechanical and clinical evaluation of posterior malleolar fractures. A systematic review of the literature. *J Trauma* 2009; 66: 279-84.
- van den Bekerom M P, Mutsaerts E L, van Dijk C N. Evaluation of the integrity of the deltoid ligament in supination external rotation ankle fractures: a systematic review of the literature. *Arch Orthop Trauma Surg* 2009; 129: 227-35.
- van den Bekerom M P, Lamme B, Hogervorst M, Bolhuis H W. Which ankle fractures require syndesmotic stabilization? *J Foot Ankle Surg* 2007; 46: 456-63.
- Beris A E, Kabbani K T, Xenakis T A, Mitsionis G, Soucacos P K, Soucacos P N. Surgical treatment of malleolar fractures. A review of 144 patients. *Clin Orthop Relat Res* 1997; 341: 90-8.
- Benacquista T, Kasabian A K, Karp N S. The fate of lower extremities with failed free flaps. *Plast Reconstr Surg* 1996; 98: 834-40.
- Beris A E, Kabbani K T, Xenakis T A, Mitsionis G, Soucacos P K, Soucacos P N. Surgical treatment of malleolar fractures. A review of 144 patients. *Clin Orthop Relat Res* 1997; 341: 90-8.
- Berkes M, Obremsky W T, Scannell B, Ellington J K, Hymes R A, Bosse M. Maintenance of hardware after early postoperative infection following fracture internal fixation. *J Bone Joint Surg Am* 2010; 92: 823-8.
- Beumer A, Swierstra B A. The influence of ankle positioning on the radiography of the distal tibial tubercles. *Surg Radiol Anat* 2003; 25: 446-50.
- Bhattacharyya T, Mehta P, Smith M, Pomahac B. Routine use of wound vacuum-assisted closure does not allow coverage delay for open tibia fractures. *Plast Reconstr Surg* 2008; 121: 1263-6.
- Bibbo C, Lin S S, Beam H A, Behrens FF. Complications of ankle fractures in diabetic patients. *Orthop Clin North Am* 2001; 32: 113-33.
- Birke-Sorensen H, Malmstro M, Rome P, et al.; International Expert Panel on Negative Pressure Wound Therapy [NPWT-EP], Martin R, Smith J. Evidence-based recommendations for negative pressure wound therapy: treatment variables (pressure levels, wound filler and contact layer)--steps towards an international consensus. *J Plast Reconstr Aesthet Surg* 2011; 64: S1-16.
- Black J D, Bhavikatti M, Al-Hadithy N, Hakmi A, Kitson J. Early weight-bearing in operatively fixed ankle fractures: a systematic review. *Foot (Edinb)* 2013; 23: 78-85.
- Blotter R H, Connolly E, Wasan A, Chapman M W. Acute complications in the operative treatment of isolated ankle fractures in patients with diabetes mellitus. *Foot Ankle Int* 1999; 20: 687-94.
- Boateng J S, Matthews K H, Stevens H N, Eccleston G M. Wound healing dressings and drug delivery systems: a review. *J Pharm Sci* 2008; 97: 2892-923.
- Borens O, Yusuf E, Steinrücken J, Trampuz A. Accurate and early diagnosis of orthopedic device-related infection by microbial heat production and sonication. *J Orthop Res* 2013; 31: 1700-3.
- Bosco III J A, Slovar J D, Haas J P. Perioperative strategies for decreasing infection. A comprehensive evidence-based approach. *J Bone Joint Surg Am* 2010; 92: 232-9.
- Brown O L, Dirschl D R, Obremsky W T. Incidence of hardware-related pain and its effect on functional outcomes after open reduction and internal fixation of ankle fractures. *J Orthop Trauma* 2001; 15: 271-4.
- Bugler K E, Watson C D, Hardie A R, Appleton P, McQueen M M, Court-Brown C M, White T O. The treatment of unstable fractures of the ankle using the Acumed fibular nail: development of a technique. *J Bone Joint Surg Br* 2012; 94: 1107-12.
- Büchler L, Tannast M, Bonel H M, Weber M. Reliability of radiologic assessment of the fracture anatomy at the posterior tibial plafond in malleolar fractures. *J Orthop Trauma* 2009; 23: 208-12.
- Calvert J W, Kohanzadeh S, Tynan M, Evans G R. Free flap reconstruction for infection of ankle fracture hardware: case report and review of the literature. *Surg Infect* 2006; 7: 315-22.
- Candal-Couto J J, Burrow D, Bromage S, Briggs P J. Instability of the tibiofibular syndesmosis: have we been pulling in the wrong direction? *Injury* 2004; 35: 814-8.
- Carragee E J, Csongradi J J, Bleck E E. Early complications in the operative treatment of ankle fractures. Influence of delay before operation. *J Bone Joint Surg Br* 1991; 73: 79-82.
- Cavadas P C, Landin L. Management of soft-tissue complications of the lateral approach for calcaneal fractures. *Plast Reconstr Surg* 2007; 120: 459-66.
- Chan J C, Malik V, Jia W, Kadowaki T, Yajnik C S, Yoon K H, Hu F B. Diabetes in Asia: epidemiology, risk factors, and pathophysiology. *JAMA* 2009; 301: 2129-40.
- Chaudhary SB, Liporace FA, Gandhi A, Donley BG, Pinzur MS, Lin SS. Complications of ankle fracture in patients with diabetes. *J Am Acad Orthop Surg* 2008; 16: 159-70.
- Chaudhry S, Egol KA. Ankle injuries and fractures in the obese patient. *Orthop Clin North Am* 2011; 42: 45-53.
- Connolly JF, Csencsitz TA. Limb threatening neuropathic complications from ankle fractures in patients with diabetes. *Clin Orthop Relat Res* 1998; 348: 212-9.
- Costigan W, Thordarson D B, Debnath U K. Operative management of ankle fractures in patients with diabetes mellitus. *Foot Ankle Int* 2007; 28: 32-7.
- Culliford AT 4th, Spector J, Blank A, Karp NS, Kasabian A, Levine J P. The fate of lower extremities with failed free flaps: a single institution's experience over 25 years. *Ann Plast Surg* 2007; 59: 18-21.
- Cyrochristos D J, Papadopoulos O, Liapis C, Felekouras E L, Giannopoulos A M, Bastounis E. Coverage strategies in exposed implants. *Am Surg* 2009; 75: 1132-8.
- Darouiche R O. Treatment of infections associated with surgical implants. *N Engl J Med* 2004; 350: 1422-9.

- Davidovitch R I, Weil Y, Karia R, Forman J, Looze C, Liebergall M, Egol K. Intraoperative syndesmotom reduction: three-dimensional versus standard fluoroscopic imaging. *J Bone Surg Am* 2013; 95: 1838-43.
- DeFranzo A J, Argenta L C, Marks M W, Molnar J A, David L R, Webb L X, Ward W G, Teasdale R G. The use of vacuum-assisted closure therapy for the treatment of lower-extremity wounds with exposed bone. *Plast Reconstr Surg* 2001; 108: 1184-91.
- Dodson N B, Ross A J, Mendicino R W, Catanzariti AR. Factors affecting healing of ankle fractures. *J Foot Ankle Surg* 2013; 52: 2-5.
- Donken C C, van Laarhoven C J, Edwards M J, Verhofstad M H. Misdiagnosis of OTA type B (Weber B) ankle fractures leading to nonunion. *J Foot Ankle Surg* 2011; 50: 430-3.
- Ebraheim N A, Elgafy H, Padanilam T. Syndesmotom disruption in low fibular fractures associated with deltoid ligament injury. *Clin Orthop Relat Res* 2003; 409: 260-7.
- Ebraheim N A, Mekhail A O, Gargas S S. Ankle fractures involving the fibula proximal to the distal tibiofibular syndesmosis. *Foot Ankle Int* 1997; 18: 513-21.
- Egol K A, Pahk B, Walsh M, Tejwani N C, Davidovitch R I, Koval K J. Outcome after unstable ankle fracture: effect of syndesmotom stabilization. *J Orthop Trauma* 2010; 24: 7-11.
- Egol K A, Tejwani N C, Walsh M G, Capla E L, Koval K J. Predictors of short-term functional outcome following ankle fracture surgery. *J Bone Joint Surg Am* 2006; 88: 974-9.
- Elgafy H, Semaan HB, Blessinger B, Wassef A, Ebraheim NA. Computed tomography of normal distal tibiofibular syndesmosis. *Skeletal Radiol* 2010; 39: 559-64.
- Eren S, Ghofrani A, Reifenrath M. The distally pedicled peroneus brevis muscle flap: a new flap for the lower leg. *Plast Reconstr Surg* 2001; 107: 1443-8.
- Fletcher NF, Sofianos DM, Berkes MB, Obremsky W. Current concepts review. Prevention of perioperative infection. *J Bone Joint Surg Am* 2007; 89: 1605-18.
- Flynn J M, Rodriguez-del Rio F, Pizá P A. Closed ankle fractures in the diabetic patient. *Foot Ankle Int* 2000; 21: 311-9.
- Franke J, von Recum J, Suda A J, Grütznér P A, Wendl K. Intraoperative three-dimensional imaging in the treatment of acute unstable syndesmotom injuries. *J Bone Joint Surg Am* 2012; 94: 1386-90.
- Ganesh S P, Pietrobon R, Cecilio WA, Pan D, Lightdale N, Nunley J A. The impact of diabetes on patient outcomes after ankle fracture. *J Bone Joint Surg Am* 2005; 87: 1712-8.
- Gardner M J, Brodsky A, Briggs S M, Nielson J H, Lorich D G. Fixation of posterior malleolar fractures provides greater syndesmotom stability. *Clin Orthop Relat Res* 2006; 447: 165-71.
- Gardner M J, Demetrakopoulos D, Briggs S M, Helfet D L, Lorich D G. The ability of the Lauge-Hansen classification to predict ligament injury and mechanism in ankle fractures: an MRI study. *J Orthop Trauma* 2006; 20: 267-72.
- Gardner M J, Demetrakopoulos D, Briggs S M, Helfet D L, Lorich D G. Malreduction of the tibiofibular syndesmosis in ankle fractures. *Foot Ankle Int* 2006; 27: 788-92.
- Giannini S, Faldini C, Aciri F, Leonetti D, Luciani D, Nanni M. Surgical treatment of post-traumatic malalignment of the ankle. *Injury* 2010; 41: 1208-11.
- Gillespie W J. Antibiotic prophylaxis for surgery for proximal femur and other closed long bone fractures. *Cochrane Database Syst Rev* 2001; 1: CD000244.
- Godina M. Early microsurgical reconstruction of complex trauma of the extremities. *Plast Reconstr Surg* 1986; 78: 285-92.
- Gonzalez M H, Weinzwieg N. Muscle flaps in the treatment of osteomyelitis of the lower extremity. *J Trauma* 2005; 58: 1019-23.
- Gonzalez M H, Tarandy D I, Troy D, Phillips D, Weinzwieg N. Free tissue coverage of chronic traumatic wounds of the lower leg. *Plast Reconstr Surg* 2002; 109: 592-600.
- Gopal S, Majumder S, Batchelor A G, Knight S L, De Boer P, Smith R M. Fix and flap: the radical orthopaedic and plastic treatment of severe open fractures of the tibia. *J Bone Joint Surg Br* 2000; 82: 959-66.
- Gougoulias N, Khanna A, Sakellariou A, Maffulli N. Supination-external rotation ankle fractures: stability a key issue. *Clin Orthop Relat Res* 2010; 468: 243-51.
- Gristina A G, Naylor P T, Myrvik Q N. Mechanisms of musculoskeletal sepsis. *Orthop Clin North Am* 1991; 22: 363-71.
- Guss D, Bhattacharyya T. Perioperative management of the obese orthopaedic patient. *J Am Acad Orthop Surg* 2006; 14: 425-32.
- Gustilo R B, Merkow R L, Templeman D. The management of open fractures. *J Bone Joint Surg Am* 1990; 72: 299-304.
- Hak D J, Egol K A, Gardner M J, Haskell A. The "not so simple" ankle fracture: avoiding problems and pitfalls to improve patient outcomes. *Instr Course Lect* 2011; 60: 73-88.
- Hallock G G. Utility of both muscle and fascia flaps in severe lower extremity trauma. *J Trauma* 2000; 48: 913-7.
- Halm J A, Schepers T. Damage to the superficial peroneal nerve in operative treatment of fibula fractures: straight to the bone? Case report and review of the literature. *J Foot Ankle Surg* 2012; 51: 684-6.
- Haraguchi N, Armiger R S. A new interpretation of the mechanism of ankle fracture. *J Bone Joint Surg Am* 2009; 91: 821-9.
- Haraguchi N, Haruyama H, Toga H, Kato F. Pathoanatomy of posterior malleolar fractures of the ankle. *J Bone Joint Surg Am* 2006; 88: 1085-92.
- Harris J, Fallat L. Effects of isolated Weber B fibular fractures on the tibiotalar contact area. *J Foot Ankle Surg* 2004; 43: 3-9.
- Hasselmann C T, Vogt M T, Stone K L, Cauley J A, Conti S F. Foot and ankle fractures in elderly white women. Incidence and risk factors. *J Bone Joint Surg Am* 2003; 85: 820-4.
- Henderson W B, Lau J T. Reconstruction of failed ankle fractures. *Foot Ankle Clin* 2006; 11: 51-60.
- Hermans J J, Beumer A, de Jong T A, Kleinrensink G J. Anatomy of the distal tibiofibular syndesmosis in adults: a pictorial essay with a multimodality approach. *J Anat* 2010; 217: 633-45.
- Hertel R, Lambert S M, Müller S, Ballmer F T, Ganz R. On the timing of soft-tissue reconstruction for open fractures of the lower leg. *Arch Orthop Trauma Surg* 1999; 119: 7-12.
- Hirvensalo E, Pajarinen J, Majola A, Salo J, Palonen R, Böstman O. Nilkämurtumien diagnostiikkaan ja hoitoon liittyvät potilasvahingot: Potilasvakuutuskeskuksen korvaamat tapaukset vuosilta 2002-2007. *Suomen Lääkärilehti* 2009; 38: 3101-6.
- Hjermstad M J, Fayers P M, Haugen D F, Caraceni A, Hanks G W, Loge J H, Fainsinger R, Aass N, Kaasa S; European Palliative Care Research Collaborative (EPCRC). Studies comparing Numerical Rating Scales, Verbal Rating Scales, and Visual Analogue Scales for assessment of pain intensity in adults: a systematic literature review. *J Pain Symptom Manage* 2011; 41: 1073-93.
- Hochberg J, Ardenghy M, Yuen J, Gonzalez-Cruz R, Miura Y, Conrado R M, Pait T G. Muscle and musculocutaneous flap coverage of exposed spinal fusion devices. *Plast Reconstr Surg* 1998; 102: 385-9.
- Hong C C, Nashi N, Prosad Roy S, Tan K J. Impact of trimalleolar ankle fractures: How do patients fare post-operatively? *Foot Ankle Surg* 2014; 20: 48-51.
- Hong C C, Roy S P, Nashi N, Tan K J. Functional outcome and limitation of sporting activities after bimalleolar and trimalleolar ankle fractures. *Foot Ankle Int* 2013; 34: 805-10.
- Horisberger M, Valderrabano V, Hintermann B. Posttraumatic ankle osteoarthritis after ankle-related fractures. *J Orthop Trauma* 2009; 23: 60-7.
- Hou Z, Irgit K, Strohecker K A, Matzko M E, Wingert N C, DeSantis J G, Smith W R. Delayed flap reconstruction with vacuum-assisted closure management of the open IIIB tibial fracture. *J Trauma* 2011; 71: 1705-8.
- Huang E S, Basu A, O'Grady M, Capretta J C. Projecting the future diabetes population size and related costs for the U.S. *Diabetes Care* 2009; 32: 2225-9.

- Hultman C S, Jones G E, Losken A, Seify H, Schaefer T G, Zapiach L A, Carlson G W. Salvage of infected spinal hardware with paraspinous muscle flaps: anatomic considerations with clinical correlation. *Ann Plast Surg* 2006; 57: 521-8.
- Höiness P, Engebretsen L, Strömsøe K. Soft tissue problems in ankle fractures treated surgically. A prospective study of 154 consecutive closed ankle fractures. *Injury* 2003; 34: 928-31.
- Höiness P, Engebretsen L, Strömsøe K. The influence of perioperative soft tissue complications on the clinical outcome in surgically treated ankle fractures. *Foot Ankle Int* 2001; 22: 642-8.
- Höiness P, Strömsøe K. The influence of the timing of surgery on soft tissue complications and hospital stay. A review of 84 closed ankle fractures. *Ann Chir Gynaecol* 2000; 89: 6-9.
- Irwin T A, Lien J, Kadakia A R. Posterior malleolus fracture. *J Am Acad Orthop Surg* 2013; 21: 32-40.
- Jaeger M, Maier D, Kern W V, Suedkamp N P. Antibiotics in trauma and orthopaedic surgery – a primer of evidence-based recommendations. *Injury* 2006; 37 Suppl 2: S74-80.
- Jakubietz R G, Schmidt K, Holzapfel B M, Meffert R H, Rudert M, Jakubietz M G. Soft tissue reconstruction of the distal lower extremity using the 180-degree perforator-based propeller flap. *Oper Orthop Traumatol* 2012; 24: 43-9.
- Jakubietz R G, Jakubietz M G, Gruenert J G, Kloss D F. The 180-degree perforator-based propeller flap for soft tissue coverage of the distal, lower extremity: a new method to achieve reliable coverage of the distal lower extremity with a local, fasciocutaneous perforator flap. *Ann Plast Surg* 2007; 59: 667-71.
- Jensen S L, Andresen B K, Mencke S, Nielsen P T. Epidemiology of ankle fractures. A prospective population-based study of 212 cases in Aalborg, Denmark. *Acta Orthop Scand* 1998; 69: 48-50.
- Johnson D P, Bannister G C. The outcome of infected arthroplasty of the knee. *J Bone Joint Surg Br* 1986; 68: 289-91.
- Jones K B, Maiers-Yelden K A, Marsh J L, Zimmerman M B, Estin M, Saltzman C L. Ankle fractures in patients with diabetes mellitus. *J Bone Joint Surg Br* 2005; 87: 489-95.
- Joy G, Patzakis M J, Harvey J P Jr. Precise evaluation of the reduction of severe ankle fractures. *J Bone Joint Surg Am* 1974; 56: 979-93.
- Jowett A J, Sheikh F T, Carare R O, Goodwin M I. Location of the sural nerve during posterolateral approach to the ankle. *Foot Ankle Int* 2010; 31: 880-3.
- Kadous A, Abdelgawad A A, Kanlic E. Deep venous thrombosis and pulmonary embolism after surgical treatment of ankle fractures: a case report and review of literature. *J Foot Ankle Surg* 2012; 51: 457-63.
- Kaikkonen A, Kannus P, Järvinen M. A performance test protocol and scoring scale for the evaluation of ankle injuries. *Am J Sports Med* 1994; 22: 462-9.
- Kanakaris N K, Thanasis C, Keramaris N, Kontakis G, Granick M S, Giannoudis P V. The efficacy of negative pressure wound therapy in the management of lower extremity trauma: review of clinical evidence. *Injury* 2007; 38 Suppl 5: S9-18.
- Kannus P, Palvanen M, Niemi S, Parkkari J, Järvinen M. Increasing number and incidence of low-trauma ankle fractures in elderly people: Finnish statistics during 1970-2000 and projections for the future. *Bone* 2002; 31: 430-3.
- Kannus P, Palvanen M, Niemi S, Parkkari J, Järvinen M. Stabilizing incidence of low-trauma ankle fractures in elderly people Finnish statistics in 1970-2006 and prediction for the future. *Bone* 2008; 43: 340-2.
- Karanas Y L, Nigriny J, Chang J. The timing of microsurgical reconstruction in lower extremity trauma. *Microsurgery* 2008; 28: 632-4.
- Kean J. The effects of smoking in the wound healing process. *J Wound Care* 2010; 19: 5-8.
- Keene D J, Williamson E, Bruce J, Willett K, Lamb S E. Early ankle movement versus immobilization in the postoperative management of ankle fracture in adults: a systematic review and meta-analysis. *J Orthop Sports Phys Ther* 2014; 44: 690-701.
- Kellgren J H, Lawrence J S. Radiological assessment of osteo-arthritis. *Ann Rheum Dis* 1957; 16: 494-502.
- Kennedy J G, Soffe K E, Dalla Vedova P, Stephens M M, O'Brien T, Walsh M G, McManus F. Evaluation of the syndesmotic screw in low Weber C ankle fractures. *J Orthop Trauma* 2000; 14: 359-66.
- Kessler B, Sendi P, Graber P, Knupp M, Zwicky L, Hintermann B, Zimmerli W. Risk factors for periprosthetic ankle joint infection: a case-control study. *J Bone Joint Surg Am* 2012; 94: 1871-6.
- Kettunen J, Kröger H. Surgical treatment of ankle and foot fractures in the elderly. *Osteoporos Int* 2005; 16 Suppl 2: S103-6.
- Khurana S, Karia R, Egol K A. Operative treatment of nonunion following distal fibula and medial malleolar ankle fractures. *Foot Ankle Int* 2013; 34: 365-71.
- Kim H N, Park Y J, Kim G L, Park Y W. Arthroscopy combined with hardware removal for chronic pain after ankle fracture. *Knee Surg Sports Traumatol Arthrosc* 2013; 21: 1427-33.
- Kneser U, Brockmann S, Leffler M, Haeberle L, Beier J P, Drago A, Unglaub F, Bach A, Horch R E. Comparison between distally based peroneus brevis and sural flaps for reconstruction of foot, ankle and distal lower leg: an analysis of donor-site morbidity and clinical outcome. *J Plast Reconstr Aesthet Surg* 2011; 64: 656-62.
- Korim M T, Payne R, Bhatia M. A case-control study of surgical site infection following operative fixation of fracture of the ankle in a large U.K. trauma unit. *Bone Joint J* 2014; 96: 636-40.
- Kortekangas T H, Pakarinen H J, Savola O, Niinimäki J, Lepojärvi S, Ohtonen P, Flinkkilä T, Ristiniemi J. Syndesmotic fixation in supination-external rotation ankle fractures: a prospective randomized study. *Foot Ankle Int* 2014; 35: 988-95.
- Koski E A, Kuokkanen H O, Tukiainen E J. Distally-based peroneus brevis muscle flap: a successful way of reconstructing lateral soft tissue defects of the ankle. *Scand J Plast Reconstr Surg Hand Surg* 2005; 39: 299-301.
- Koval K J, Zhou W, Sparks M J, Cantu R V, Hecht P, Lurie J. Complications after ankle fracture in elderly patients. *Foot Ankle Int* 2007; 28: 1249-55.
- Kristensen K D, Hansen T. Closed treatment of ankle fractures. Stage II supination-eversion fractures followed for 20 years. *Acta Orthop Scand* 1985; 56: 107-9.
- Kubiak E N, Beebe M J, North K, Hitchcock R, Potter M Q. Early weight bearing after lower extremity fractures in adults. *J Am Acad Orthop Surg* 2013; 21: 727-38.
- Lauge-Hansen N. Fractures of the ankle. II. Combined experimental-surgical and experimental-roentgenologic investigations. *Arch Surg* 1950; 60: 957-85.
- Lee J, Singletary R, Schmader K, Anderson D J, Bolognesi M, Kaye K S. Surgical site infection in the elderly following orthopaedic surgery. Risk factors and outcomes. *J Bone Joint Surg Am* 2006; 88: 1705-12.
- Leeds H C, Ehrlich M G. Instability of the distal tibiofibular syndesmosis after bimalleolar and trimalleolar ankle fractures. *J Bone Joint Surg Am* 1984; 66: 490-503.
- Lehtonen H, Järvinen T L, Honkonen S, Nyman M, Vihtonen K, Järvinen M. Use of a cast compared with a functional ankle brace after operative treatment of an ankle fracture. A prospective, randomized study. *J Bone Joint Surg Am* 2003; 85: 205-11.
- Lepojärvi S, Pakarinen H, Savola O, Haapea M, Blanco R, Niinimäki J. Posterior translation of the fibula may indicate malreduction: CT study of normal variation in uninjured ankles. *J Orthop Trauma* 2014; 28: 205-9.
- Lesavoy M A, Dubrow T J, Wackym P A, Eckardt J J. Muscle-flap coverage of exposed endoprostheses. *Plast Reconstr Surg* 1989; 83: 90-9.
- Levin L S. Soft tissue coverage options for ankle wounds. *Foot Ankle Clin* 2001; 6: 853-66.
- Leyes M, Torres R, Guillén P. Complications of open reduction and internal fixation of ankle fractures. *Foot Ankle Clin* 2003; 8: 131-47.
- Lin C W, Donkers N A, Refshauge K M, Beckenkamp P R, Khara K, Moseley A M. Rehabilitation for ankle fractures in adults. *Cochrane Database Syst Rev* 2012; 11: CD005595. doi: 10.1002/14651858.

- Lindsjö U. Operative treatment of ankle fractures. *Acta Orthop Scand Suppl* 1981; 189: 1-131.
- Lindsjö U. Operative treatment of ankle fracture-dislocations. A follow-up study of 306/321 consecutive cases. *Clin Orthop Relat Res* 1985; 199: 28-38.
- de Lissovoy G, Fraeman K, Hutchis V, Murphy D, Song D, Vaughn B B. Surgical site infection: Incidence and impact on hospital utilization and treatment costs. *Am J Infect Control* 2009; 37: 387-97.
- Little M T, Berkes M B, Lazaro L E, Sculco P K, Cymerman R M, Pardee N, Helfet D L, Lorich D G. Comparison of supination external rotation type IV ankle fractures in geriatric versus nongeriatric populations. *Foot Ankle Int* 2013; 34: 512-7.
- Little M T, Berkes M B, Lazaro L E, Sculco P K, Helfet D L, Lorich D G. Complications following treatment of supination external rotation ankle fractures through the posterolateral approach. *Foot Ankle Int* 2013; 34: 523-9.
- Liu D S, Sofiadellis F, Ashton M, MacGill K, Webb A. Early soft tissue coverage and negative pressure wound therapy optimises patient outcomes in lower limb trauma. *Injury* 2012; 43: 772-8.
- Lloyd J, Elsayed S, Hariharan K, Tanaka H. Revisiting the concept of talar shift in ankle fractures. *Foot Ankle Int* 2006; 27: 793-796.
- Lorenzetti F, Lazzeri D, Bonini L, Giannotti G, Piolanti N, Lisanti M, Pantaloni M. Distally based peroneus brevis muscle flap in reconstructive surgery of the lower leg: Postoperative ankle function and stability evaluation. *J Plast Reconstr Aesthet Surg* 2010; 63: 1523-33.
- Lübbecke A, Salvo D, Stern R, Hoffmeyer P, Holzer N, Assal M. Risk factors for post-traumatic osteoarthritis of the ankle: an eighteen year follow-up study. *Int Orthop* 2012; 36: 1403-10.
- Lynde M J, Sautter T, Hamilton G A, Schuberth J M. Complications after open reduction and internal fixation of ankle fractures in the elderly. *Foot Ankle Surg* 2012; 18: 103-7.
- Marmor M, Hansen E, Han H K, Buckley J, Matityahu A. Limitations of standard fluoroscopy in detecting rotational malreduction of the syndesmosis in an ankle fracture model. *Foot Ankle Int* 2011; 32: 616-22.
- Masquelet A C, Romana M C, Wolf G. Skin island flaps supplied by the vascular axis of the sensitive superficial nerves: anatomic study and clinical experience in the leg. *Plast Reconstr Surg* 1992; 89: 1115-21.
- McConnell T, Tornetta P 3rd. Marginal plafond impaction in association with supination-adduction ankle fractures: a report of eight cases. *J Orthop Trauma* 2001; 15: 447-9.
- McCormack R G, Leith J M. Ankle fractures in diabetics. Complications of surgical management. *J Bone Joint Surg Br* 1998; 80: 689-92.
- McGonagle L, Ralte P, Kershaw S. Non-union of Weber B distal fibula fractures: a case series. *Foot Ankle Surg* 2010; 16: 63-7.
- McKean J, Cuellar D O, Hak D, Mauffrey C. Osteoporotic ankle fractures: an approach to operative management. *Orthopedics* 2013; 36: 936-40.
- Mendelsohn E S, Hoshino C M, Harris T G, Zinar D M. The effect of obesity on early failure after operative syndesmosis injuries. *J Orthop Trauma* 2013; 27: 201-6.
- Michelson J D, Magid D, McHale K. Clinical utility of a stability-based ankle fracture classification system. *J Orthop Trauma* 2007; 21: 307-15.
- Michelson J D. Fractures about the ankle. *J Bone Joint Surg Am* 1995; 77: 142-52.
- Miller AG, Margules A, Raikin SM. Risk factors for wound complications after ankle fracture surgery. *J Bone Joint Surg Am* 2012; 94: 2047-52.
- Miller AN, Carroll EA, Parker RJ, Helfet DL, Lorich DG. Posterior malleolar stabilization of syndesmosis injuries is equivalent to screw fixation. *Clin Orthop Relat Res* 2010; 468: 1129-35.
- Miller AN, Carroll EA, Parker R J, Boraiah S, Helfet D L, Lorich D G. Direct visualization for syndesmosis stabilization of ankle fractures. *Foot Ankle Int* 2009; 30: 419-26.
- Mont M A, Sedlin E D, Weiner L S, Miller A R. Postoperative radiographs as predictors of clinical outcome in unstable ankle fractures. *J Orthop Trauma* 1992; 6: 352-7.
- Moucha C S, Clyburn T, Evans R P, Prokuski L. Modifiable risk factors for surgical site infection. *J Bone Joint Surg Am* 2011; 93: 398-404.
- Moués C M, Heule F, Hovius S E. A review of topical negative pressure therapy in wound healing: sufficient evidence? *Am J Surg* 2011; 201: 544-56.
- Mukhopadhyay S, Metcalfe A, Guha AR, Mohanty K, Hemmadi S, Lyons K, O'Doherty D. Malreduction of syndesmosis--are we considering the anatomical variation? *Injury* 2011; 42: 1073-6.
- Muller M, Allgower M, Schneider R, Willenegger H. Manual of internal fixation. Techniques recommended by the AO Group. Springer, New York 1979.
- Naique S B, Pearse M, Nanchahal J. Management of severe open tibial fractures: the need for combined orthopaedic and plastic surgical treatment in specialist centres. *J Bone Joint Surg Br* 2006; 88: 351-7.
- Ng A, Barnes E S. Management of complications of open reduction and internal fixation of ankle fractures. *Clin Podiatr Med Surg* 2009; 26: 105-25.
- Nielson J H, Gardner M J, Peterson M G, Sallis J G, Potter H G, Helfet D L, Lorich DG. Radiographic measurements do not predict syndesmosis injury in ankle fractures: an MRI study. *Clin Orthop Relat Res* 2005; 436: 216-21.
- Nielson J H, Sallis J G, Potter H G, Helfet D L, Lorich D G. Correlation of interosseous membrane tears to the level of the fibular fracture. *J Orthop Trauma* 2004; 18: 68-74.
- Nilsson G, Jonsson K, Ekdahl C, Eneroth M. Outcome and quality of life after surgically treated ankle fractures in patients 65 years or older. *BMC Musculoskelet Disord* 2007; 20: 8: 127.
- Nimick C J, Collman D R, Lagaay P. Fixation orientation in ankle fractures with syndesmosis injury. *J Foot Ankle Surg* 2013; 52: 315-8.
- Nugent J F, Gale B D. Isolated posterior malleolar ankle fractures. *J Foot Surg* 1990; 29: 80-3.
- Nåsell H, Ottoson C, Törnqvist H, Linde J, Ponzer S. The impact of smoking on complications after operatively treated ankle fractures – a follow-up study of 906 patients. *J Orthop Trauma* 2011; 25: 748-55.
- Obremsky W T, Dirschl D R, Crowther J D, Craig W L 3rd, Driver R E, LeCroy C M. Change over time of SF-36 functional outcomes for operatively treated unstable ankle fractures. *J Orthop Trauma* 2002; 16: 30-3.
- Ogilvie-Harris D J, Reed S C, Hedman T P. Disruption of the ankle syndesmosis: biomechanical study of the ligamentous restraints. *Arthroscopy* 1994; 10: 558-60.
- Olerud C, Molander H. A scoring scale for symptom evaluation after ankle fracture. *Arch Orthop Trauma Surg* 1984; 103: 190-4.
- Olsen J R, Hunter J, Baumhauer J F. Osteoporotic ankle fractures. *Orthop Clin North Am* 2013; 44: 225-41.
- Olsen MA, Nepple JJ, Riew KD, Lenke LG, Bridwell KH, Mayfield J, Fraser VJ. Risk factors for surgical site infection following orthopaedic spinal operations. *J Bone Joint Surg Am* 2008; 90: 62-9.
- Pakarinen H. Stability-based classification for ankle fracture management and the syndesmosis injury in ankle fractures due to a supination external rotation mechanism of injury. *Acta Orthop Suppl* 2012; 83: 1-26.
- Pakarinen H J, Flinkkilä T E, Ohtonen P P, Ristiniemi J Y. Stability criteria for nonoperative ankle fracture management. *Foot Ankle Int* 2011a; 32: 141-7.
- Pakarinen H, Flinkkilä T, Ohtonen P, Hyvönen P, Lakovaara M, Leppilahti J, Ristiniemi J. Intraoperative assessment of the stability of the distal tibiofibular joint in supination-external rotation injuries of the ankle: sensitivity, specificity, and reliability of two clinical tests. *J Bone Joint Surg Am* 2011b; 93: 2057-61.
- Pakarinen H J, Flinkkilä T E, Ohtonen P P, Hyvönen P H, Lakovaara M T, Leppilahti J, Ristiniemi J Y. Syndesmosis fixation in supination-external rotation ankle fractures: a prospective randomized study. *Foot Ankle Int* 2011c; 32: 1103-9.
- Pelet S, Roger M E, Belzile E L, Bouchard M. The incidence of thromboembolic events in surgically treated ankle fracture. *J Bone Joint Surg Am* 2012; 94: 502-6.
- Pettrone F A, Gail M, Pee D, Fitzpatrick T, Van Herpe L B. Quantitative criteria for prediction of the results after displaced fracture of the ankle. *J Bone Joint Surg Am* 1983; 65: 667-77.

- Phisitkul P, Ebinger T, Goetz J, Vaseenon T, Marsh J L. Forceps reduction of the syndesmosis in rotational ankle fractures: a cadaveric study. *J Bone Joint Surg Am* 2012; 94: 2256-61.
- Pneumaticos S G, Noble P C, Chatziioannou S N, Trevino S G. The effects of rotation on radiographic evaluation of the tibiofibular syndesmosis. *Foot Ankle Int* 2002; 23: 107-11.
- Pollak A N, Jones A L, Castillo R C, Bosse M J, MacKenzie E J, The LEAP Study Group. The relationship between time to surgical debridement and incidence of infection after open high-energy lower extremity trauma. *J Bone Joint Surg Am* 2010; 92: 7-15.
- Pollak A N, McCarthy M L, Burgess A R. Short-term wound complications after application of flaps for coverage of traumatic soft-tissue defects about the tibia. The Lower Extremity Assessment Project (LEAP) Study Group. *J Bone Joint Surg Am* 2000; 82: 1681-91.
- Ponzer S, Näsell H, Bergman B, Törnkvist H. Functional outcome and quality of life in patients with Type B ankle fractures: a two-year follow-up study. *J Orthop Trauma* 1999; 13: 363-8.
- Pritchard J M, Giangregorio L M, Ioannidis G, Papaioannou A, Adachi J D, Leslie W D. Ankle fractures do not predict osteoporotic fractures in women with or without diabetes. *Osteoporos Int* 2012; 23: 957-62.
- Ramsey P L, Hamilton W. Changes in tibiotalar area of contact caused by lateral talar shift. *J Bone Joint Surg Am* 1976; 58: 356-7.
- Rajeev A, Senevirathna S, Radha S, Kashayap N S. Functional outcomes after fibula locking nail for fragility fractures of the ankle. *J Foot Ankle Surg* 2011; 50: 547-50.
- Redfern D J, Sauvé P S, Sakellariou A. Investigation of incidence of superficial peroneal nerve injury following ankle fracture. *Foot Ankle Int* 2003; 24: 771-4.
- Richards J E, Kauffmann R M, Zuckerman S L, Obremskey W T, May A K. Relationship of hyperglycemia and surgical-site infection in orthopaedic surgery. *J Bone Joint Surg Am* 2012; 94: 1181-6.
- Richards R. Introduction: Implants and infection in fracture fixation "ten years on". *Injury* 2006; 37: S1-2.
- Rightmire E, Zurakowski D, Vrahas M. Acute infections after fracture repair: management with hardware in place. *Clin Orthop Relat Res* 2008; 466: 466-72.
- Ríos-Luna A, Villanueva-Martínez M, Fahandezh-Saddi H, Villanueva-Lopez F, del Cerro-Gutiérrez M. Versatility of the sural fasciocutaneous flap in coverage defects of the lower limb. *Injury* 2007; 38: 824-31.
- Rizvi A A, Chillag S A, Chillag K J. Perioperative management of diabetes and hyperglycemia in patients undergoing orthopaedic surgery. *J Am Acad Orthop Surg* 2010; 18: 426-35.
- Rodriguez-Merchan E C, Forriol F. Nonunion: general principles and experimental data. *Clin Orthop Relat Res* 2004; 419: 4-12.
- Ruedi T, Buckley R, Moran C. *AO Principles of fracture management. Vol 2 – Specific fractures. Malleoli*. Pages 871-899. Second expanded edition. Hahn D, Colton C. Pages 871-899. Thieme. New York 2007.
- Rukavina A. The role of fibular length and the width of the ankle mortise in post-traumatic osteoarthritis after malleolar fracture. *Int Orthop* 1998; 22: 357-60.
- Ryd L, Bengtsson S. Isolated fracture of the lateral malleolus requires no treatment. 49 prospective cases of supination-eversion type II ankle fractures. *Acta Orthop Scand* 1992; 63: 443-6.
- Sagi H C, Shah A R, Sanders R W. The functional consequence of syndesmosis joint malreduction at a minimum 2-year follow-up. *J Orthop Trauma* 2012; 26: 439-43.
- Saltzman C L, Salamon M L, Blanchard G M, Huff T, Hayes A, Buckwalter J A, Amendola A. Epidemiology of ankle arthritis: report of a consecutive series of 639 patients from a tertiary orthopaedic center. *Iowa Orthop J* 2005; 25: 44-6.
- Sanders D W, Tieszer C, Corbett B; Canadian Orthopedic Trauma Society. Operative versus nonoperative treatment of unstable lateral malleolar fractures: a randomized multicenter trial. *J Orthop Trauma* 2012; 26: 129-34.
- Schepers T, De Vries M R, Van Lieshout E M, Van der Elst M. The timing of ankle fracture surgery and the effect on infectious complications; a case series and systematic review of the literature. *Int Orthop* 2013; 37: 489-94.
- Schepers T, Van Lieshout E M, De Vries M R, Van der Elst M. Increased rates of wound complications with locking plates in distal fibular fractures. *Injury* 2011; 42: 1125-9.
- Schepers T. Acute distal tibiofibular syndesmosis injury: a systematic review of suture-button versus syndesmotic screw repair. *Int Orthop* 2012; 36: 1199-206.
- van Schie-Van der Weert E M, Van Lieshout E M, De Vries M R, Van der Elst M, Schepers T. Determinants of outcome in operatively and non-operatively treated Weber-B ankle fractures. *Arch Orthop Trauma Surg* 2012; 132: 257-63.
- Schoifet S D, Morrey B F. Treatment of infection after total knee arthroplasty by débridement with retention of the components. *J Bone Joint Surg Am* 1990; 72: 1383-90.
- Selby R, Geerts W H, Kreder H J, Crowther M A, Kaus L, Sealey F. Symptomatic venous thromboembolism uncommon without thromboprophylaxis after isolated lower-limb fracture: the knee-to-ankle fracture (KAF) cohort study. *J Bone Joint Surg Am* 2014; 96: e83
- Shivarathre DG, Chandran P, Platt SR. Operative fixation of unstable ankle fractures in patients aged over 80 years. *Foot Ankle Int* 2011; 32: 599-602.
- Simanski C J, Maegelé M G, Lefering R, Lehnen D M, Kawel N, Riess P, Yücel N, Tiling T, Bouillon B. Functional treatment and early weightbearing after an ankle fracture: a prospective study. *J Orthop Trauma* 2006; 20: 108-14.
- Sintonen H. The 15D instrument of health-related quality of life: properties and applications. *Ann Med* 2001; 33: 328-36.
- Slobogean G P, Marra C A, Sadatsafavi M, Sanders D W; Canadian Orthopedic Trauma Society. Is surgical fixation for stress-positive unstable ankle fractures cost effective? Results of a multicenter randomized control trial. *J Orthop Trauma* 2012; 26: 652-8.
- Slobogean G P, O'Brien P J, Brauer C A. Single-dose vs multiple-dose antibiotic prophylaxis for the surgical treatment of closed fractures. A cost-effectiveness analysis. *Acta Orthop* 2010; 81: 258-64.
- Somersalo A, Paloneva J, Kautiainen H, Lönnroos E, Heinänen M, Kiviranta I. Incidence of fractures requiring inpatient care. *Acta Orthop* 2014; 85: 525-30.
- SooHoo N F, Eagan M, Krenek L, Zingmond D S. Incidence and factors predicting pulmonary embolism and deep venous thrombosis following surgical treatment of ankle fractures. *Foot Ankle Surg* 2011; 17: 259-62.
- SooHoo N F, Krenek L, Eagan M J, Gurbani B, Ko C Y, Zingmond D S. Complication rates following open reduction and internal fixation of ankle fractures. *J Bone Joint Surg Am* 2009; 91: 1042-9.
- de Souza L J, Gustilo R B, Meyer T J. Results of operative treatment of displaced external rotation-abduction fractures of the ankle. *J Bone Joint Surg Am* 1985; 67: 1066-74.
- Stannard J P, Volgas D A, McGwin G 3rd, Stewart R L, Obremskey W, Moore T, Anglen J O. Incisional negative pressure wound therapy after high-risk lower extremity fractures. *J Orthop Trauma* 2012; 26: 37-42.
- Stannard J P, Singanamala N, Volgas D A. Fix and flap in the era of vacuum suction devices: What do we know in terms of evidence based medicine? *Injury* 2010; 41: 780-6.
- Stannard J P, Volgas D A, Stewart R, McGwin G Jr, Alonso J E. Negative pressure wound therapy after severe open fractures: a prospective randomized study. *J Orthop Trauma* 2009; 23: 552-7.
- Starkweather M P, Collman D R, Schuberth J M. Early protected weightbearing after open reduction internal fixation of ankle fractures. *J Foot Ankle Surg* 2012; 51: 575-8.
- Stoffel K, Wysocki D, Baddour E, Nicholls R, Yates P. Comparison of two intraoperative assessment methods for injuries to the ankle syndesmosis. A cadaveric study. *J Bone Joint Surg Am* 2009; 91: 2646-52.
- Strauss E J, Egol K A. The management of ankle fractures in the elderly. *Injury* 2007; 38 Suppl 3: S2-9.

- Stufkens S A, Knupp M, Horisberger M, Lampert C, Hintermann B. Cartilage lesions and the development of osteoarthritis after internal fixation of ankle fractures: a prospective study. *J Bone Joint Surg Am* 2010; 92: 279-86.
- Talbot M, Steenblock T R, Cole P A. Posterolateral approach for open reduction and internal fixation of trimalleolar ankle fractures. *Can J Surg* 2005; 48: 487-90.
- Tan K J, Lim C T, Lim A Y. The use of muscle flaps in the salvage of infected exposed implants for internal fixation. *J Bone Joint Surg Br* 2010; 92: 401-5.
- Tejwani N C, Pahk B, Egol K A. Effect of posterior malleolus fracture on outcome after unstable ankle fracture. *J Trauma* 2010; 69: 666-9.
- Testroote M, Stigter W, de Visser DC, Janzing H. Low molecular weight heparin for prevention of venous thromboembolism in patients with lower-leg immobilization. *Cochrane Database Syst Rev* 2008; 4: CD006681. doi: 10.1002/14651858.
- Thomas G, Whalley H, Modi C. Early mobilization of operatively fixed ankle fractures: a systematic review. *Foot Ankle Int* 2009; 30: 666-74.
- Thordarson D B. Patients with a crooked radiograph after ankle fracture: what to do? *Foot Ankle Int* 2012; 33: 355-8.
- Thordarson D B, Ahlmann E, Shepherd L E, Patzakis M J. Sepsis and osteomyelitis about the ankle joint. *Foot Ankle Clin* 2000; 5: 913-28.
- Thordarson D B, Motamed S, Hedman T, Ebramzadeh E, Bakshian S. The effect of fibular malreduction on contact pressures in an ankle fracture malunion model. *J Bone Joint Surg Am*, 1997; 79: 1809-15.
- Thur C K, Edgren G, Jansson K Å, Wretenberg P. Epidemiology of adult ankle fractures in Sweden between 1987 and 2004: a population-based study of 91,410 Swedish inpatients. *Acta Orthop* 2012; 83: 276-81.
- Trampuz A, Zimmerli W. Diagnosis and treatment of infections associated with fracture-fixation devices. *Injury* 2006; 37 Suppl 2: S59-66.
- Trebse R, Pisot V, Trampuz A. Treatment of infected retained implants. *J Bone Joint Surg Br* 2005; 87: 249-56.
- Tønnesen H, Pedersen A, Jensen M R, Møller A, Madsen J C. Ankle fractures and alcoholism. The influence of alcoholism on morbidity after malleolar fractures. *J Bone Joint Surg Br* 1991; 73: 511-3.
- Ueng W N, Shih C H. Management of infected tibial plate osteosynthesis using a staging system for infected fractures. *J Formos Med Assoc* 1992; 91: 531-7.
- Vaianti L, Di Matteo A, Gazzola R, Pierannunzi L, Palitta G, Marchesi A. First results with the immediate reconstructive strategy for internal hardware exposure in non-united fractures of the distal third of the leg: case series and literature review. *J Orthop Surg Res* 2012a; 7: 30.
- Vaianti L, Di Matteo A, Gazzola R, Randelli P, Lonigro J. Distally based sural fasciomusculocutaneous flap for treatment of wounds of the distal third of the leg and ankle with exposed internal hardware. *J Orthop Traumatol* 2012b; 13: 35-9.
- Valderrabano V, Horisberger M, Russell I, Dougall H, Hintermann B. Etiology of ankle osteoarthritis. *Clin Orthop Relat Res* 2009; 467: 1800-6.
- Valtola A, Honkanen R, Kröger H, Tuppurainen M, Saarikoski S, Alhava E. Lifestyle and other factors predict ankle fractures in perimenopausal women: a population-based prospective cohort study. *Bone* 2002; 30: 238-42.
- Van Heest T J, Lafferty PM. Injuries to ankle syndesmosis. *J Bone Joint Surg Am* 2014; 96: 603-13.
- Vasarhelyi A, Lubitz J, Gierer P, Gradl G, Rösler K, Hopfenmüller W, Klauke K, Mittlmeier T W. Detection of fibular torsional deformities after surgery for ankle fractures with a novel CT method. *Foot Ankle Int* 2006; 27: 1115-21.
- Viol A, Pradka S P, Baumeister S P, Wang D, Moyer K E, Zura R D, Olson S A, Zenn M R, Levin S L, Erdmann D. Soft-tissue defects and exposed hardware: a review of indications for soft-tissue reconstruction and hardware preservation. *Plast Reconstr Surg* 2009; 123: 1256-63.
- Vioreanu M, Dudeney S, Hurson B, Kelly E, O'Rourke K, Quinlan W. Early mobilization in a removable cast compared with immobilization in a cast after operative treatment of ankle fractures: a prospective randomized study. *Foot Ankle Int* 2007; 28: 13-9.
- Wagner M. General principles for the clinical use of the LCP. *Injury* 2003; 34 Suppl 2: B31-42.
- Walsh E F, DiGiovanni C. Fibular nonunion after closed rotational ankle fracture. *Foot Ankle Int* 2004; 25: 488-95.
- Webb L X, Bosse M J, Castillo R C, MacKenzie E J; LEAP Study Group. Analysis of surgeon-controlled variables in the treatment of limb-threatening type-III open tibial diaphyseal fractures. *J Bone Joint Surg Am* 2007; 89: 923-8.
- Weening B, Bhandari M. Predictors of functional outcome following trans-syndesmotomic screw fixation of ankle fractures. *J Orthop Trauma* 2005; 19: 102-8.
- van Wensen R J, van den Bekerom M P, Marti R K, van Heerwaarden R J. Reconstructive osteotomy of fibular malunion: review of the literature. *Strategies Trauma Limb Reconstr* 2011; 6: 51-7.
- White C B, Turner N S, Lee G C, Haidukewych G J. Open ankle fractures in patients with diabetes mellitus. *Clin Orthop Relat Res* 2003; 414: 37-44.
- Whitehouse J D, Friedman N D, Kirkland K B, Richardson W J, Sexton D J. The impact of surgical-site infection following orthopaedic surgery at a community hospital and a university hospital: adverse quality of life, excess length of stay, and extra cost. *Infect Control Hosp Epidemiol* 2002; 23: 183-9.
- Wikerøy A K, Høiness PR, Andreassen G S, Hellund J C, Madsen J E. No difference in functional and radiographic results 8.4 years after quadricortical compared with tricortical syndesmosis fixation in ankle fractures. *J Orthop Trauma* 2010; 24: 17-23.
- Wukich D K, Joseph A, Ryan M, Ramirez C, Irrgang J J. Outcomes of ankle fractures in patients with uncomplicated versus complicated diabetes. *Foot Ankle Int* 2011; 32: 120-30.
- Wukich D K, Lowery N J, McMillen R L, Frykberg R G. Postoperative infection rates in foot and ankle surgery: a comparison of patients with and without diabetes mellitus. *J Bone Joint Surg Am* 2010; 92: 287-95.
- Wukich D K, Kline A J. The management of ankle fractures in patients with diabetes. *J Bone Joint Surg Am* 2008; 90: 1570-8.
- Wyss C, Zollinger H. The causes of subsequent arthrodesis of the ankle joint. *Acta Orthop Belg* 1991; 57 Suppl 1: 22-7.
- Xu G, Lai-Jin L. The coverage of skin defects over the foot and ankle using the distally based sural neurocutaneous flaps: experience of 21 cases. *J Plast Reconstr Aesthet Surg* 2008; 61: 575-7.
- Yang Y L, Lin T M, Lee S S, Chang K P, Lai C S. The distally pedicled peroneus brevis muscle flap anatomic studies and clinical applications. *J Foot Ankle Surg* 2005; 44: 259-64.
- Yao L, Zhang W, Yang G, Zhu Y, Zhai Q, Luo C. Morphologic characteristics of the posterior malleolus fragment: a 3-D computer tomography based study. *Arch Orthop Trauma Surg* 2014; 134: 389-94.
- Yde J, Kristensen K D. Ankle fractures. Supination-eversion fractures stage II. Primary and late results of operative and non-operative treatment. *Acta Orthop Scand* 1980; 51: 695-702.
- Yi X, Zhu J, Wei M, Li J, Chen J, Wang Y, Shen E, Hu B. Risk factors of venous thrombosis in patients with ankle fractures. *Int Angiol* 2014; 33: 324-8.
- Zaghloul A, Haddad B, Barksfield R, Davis B. Early complications of surgery in operative treatment of ankle fractures in those over 60: A review of 186 cases. *Injury* 2014; 45: 780-3.
- Záhorka J, Nejedlý A, Tvrdík M, Dzupa V. Management of infected tibial fractures and chronic tibial osteomyelitis by muscle flap transfer: a comparison of two series of patients. *Acta Chir Plast* 2009; 51: 3-9.
- Zalavras C G, Christensen T, Rigopoulos N, Holtom P, Patzakis M J. Infection following operative treatment of ankle fractures. *Clin Orthop Relat Res* 2009; 467: 1715-20.